

High-Energy Proximal Humerus Fractures in Geriatric Patients: A Review

Geriatric Orthopaedic Surgery
& Rehabilitation
Volume 11: 1-15
© The Author(s) 2020
Article reuse guidelines:
sagepub.com/journals-permissions
DOI: 10.1177/2151459320971568
journals.sagepub.com/home/gos



Jordan M. Walters, MD¹ , and Shahryar Ahmadi, MD¹

Abstract

High-energy proximal humerus fractures in elderly patients can occur through a variety of mechanisms, with falls and MVCs being common mechanisms of injury in this age group. Even classically low-energy mechanisms can result in elevated ISS scores, which are associated with higher mortality in both falls and MVCs. These injuries result in proximal humerus fractures which are commonly communicated via Neer's classification scheme. There are many treatment options in the armamentarium of the treating surgeon. Nonoperative management is widely supported by systematic review as compared to almost all other treatment methods. ORIF is particularly useful for complex patterns and fracture dislocations in healthy patients. Hemiarthroplasty can be of utility in patients with fracture patterns with high risk of AVN and poor bone quality risking screw cut-out. Reverse total shoulder arthroplasty is a popular method of treatment for geriatric patients also, with literature now showing that even late conversion from nonoperative management or ORIF to rTSA can lead to good clinical outcomes. Prevention is possible and important for geriatric patients. Optimizing medical care including hearing, vision, strength, and bone quality, in coordination with primary care and geriatricians, is of great importance in preventing fractures and decreasing injury when falls do occur. Involving geriatricians on dedicated trauma teams will also likely be of benefit.

Keywords

geriatric, high energy, elderly, proximal humerus, fracture, trauma

Submitted January 19, 2020. Revised August 29, 2020. Accepted October 6, 2020.

Introduction

Proximal humerus fractures are common among injuries in geriatric patients. Although 87% of these are from standing height,¹ a substantial number of the remainder likely result from falls from height, motor vehicle collisions (MVCs), and other higher energy mechanisms.² In addition, even classically low energy mechanisms and low-speed MVCs can result in elevated injury severity scores (ISS) or Maximum Abbreviated Injury Scale (MAIS) scores in elderly patients,^{3,4} indicating the increased complexity of care in these patients. Taylor et al showed that mortality increased with ISS among elderly trauma patients and was significantly higher than patients less than 65 (ISS < 15, 3.2% mortality in elderly versus 0.4% non-elderly; ISS 15-29, 19.7% mortality in elderly versus 5.4% non-elderly; ISS ≥ 30, 47.8% mortality in elderly versus 21.7% non-elderly). They concluded that age is an independent risk factor of mortality after stratification for ISS.⁵ Labib and colleagues showed that geriatric patients requiring intubation or transfusion or suffering from head, c-spine, or chest trauma have increased mortality.⁶ Complexity of care is also increased as elderly patients are at risk of delirium; it has been shown that

patients 65 and older develop delirium in the surgical intensive care unit 28.3% of the time, while 45.6% experience delirium some time during their stay or within the 24 hours prior to admission.⁷ Mortality in elderly patients with rib fractures and traumatic brain injuries is also higher than in non-elderly counterparts, adding to complexity.^{8,9} Age has also been associated with hyperglycemia in trauma patients.¹⁰ In patients requiring surgery, geriatric patients are at increased risk of mortality, major perioperative complications, and length of stay.¹¹ These findings showing ISS correlating with mortality and showing elevated mortality and complications in geriatric patients in general stress the importance of interdisciplinary care, communication, and attention to detail.

¹ Department of Orthopaedic Surgery, University of Arkansas for Medical Sciences, Little Rock, AR, USA

Corresponding Author:

Jordan Walters, Department of Orthopaedic Surgery, University of Arkansas for Medical Sciences, 4301 W. Markham St, Slot 531, Little Rock, AR 72205, USA.

Email: JWalters@uams.edu



Proximal humerus fractures specifically are associated with elevated mortality rates among geriatric trauma patients,¹² further indicating that these are complex injuries in elderly patients. “High-energy” trauma is a term used in the literature without a concrete definition; for our purposes we assume “high-energy” to include injuries with ISS values of 16 or greater not resulting from a same-level fall, as there is some precedent for this in other studies.^{12,13}

Anatomy

Proximal humerus fractures are typically classified based on involvement of four structural elements: the greater tuberosity, lesser tuberosity, shaft, and articular surface. The blood supply to the humeral head is from the anterior and posterior circumflex humeral arteries and their branches. The posterior circumflex supplies the majority of the head, while the anterior circumflex gives rise to the arcuate artery, which runs lateral to the biceps tendon before piercing the head to supply the medial quadrant of the head.¹⁴

Classification

High-energy proximal humerus fractures are classified in the same manner as their low-energy counterparts. The two most common classification systems are the AO/OTA classification, which focuses on intra-articular versus extra-articular location, blood supply/risk of avascular necrosis, and focal versus bifocal pattern¹⁵ (Figure 1). The classic Neer classification (Figure 2) was first described in 1970 and is broken down into 2-part, 3-part, and 4-part injuries based on the greater tuberosity, lesser tuberosity, shaft, and articular surface involvement. This was intended originally to be based on effects of muscle attachment, blood supply to the humeral head, and the condition of the articular surface. It has faced scrutiny for somewhat arbitrary selection of one centimeter and 45 degree cutoffs for segment displacement and has been shown in numerous studies to have limited interobserver and intraobserver reliability. However, it does serve as a time-tested form of communication about fracture types and serves as a “mental picture of the actual pathomechanics and pathoanatomy” to identify each category.¹⁶

Diagnosis

Diagnosis is typically made with plain radiographs in simple two-part fractures, with advanced imaging for more complicated patterns when x-rays are inadequate to develop an appropriate treatment plan¹⁷ (Figure 3). As operative fixation of displaced greater tuberosity fractures can result in meaningful clinical differences¹⁸ and 5 mm displacement is generally considered indication for fixation, CT is often useful for fractures involving the tuberosities and for complex patterns with multiple parts. In cases in which arthroplasty is the treatment of choice, MRI¹⁹ and CT²⁰ have been shown to outperform x-ray in assessing glenoid version.

Management

Probably the most extensive element of proximal humerus literature, high-energy or not, regards management. Nonoperative management, percutaneous pinning, open reduction internal fixation (ORIF), hemiarthroplasty, and reverse total shoulder arthroplasty (rTSA) are all theoretical options for the geriatric patient with a high energy proximal humerus fracture. The high-energy and polytraumatic nature of the situation adds important caveats to treatment decisions as discussed below.

Nonoperative

Nonoperative management has long been considered an option for proximal humerus fractures. A retrospective study in the late 90s showed high patient satisfaction despite low functional scoring and poor reduction in many cases; the authors concluded that nonoperative management of displaced three-part fractures should be considered.²¹ Another similar study retrospectively looked at two-, three-, and four-part fractures and concluded that displaced proximal humerus fractures could be satisfactorily treated by closed methods.²² A systematic review by Iyengar et al showed that in 12 studies on 650 patients, radiographic union was 98% and the average Constant Score was 74. Avascular necrosis (AVN) was reported in only 13 of the 650 cases. The study concluded that nonoperative management demonstrates high rates of healing with good function outcomes.²³ Hanson et al showed that after one year of nonoperative management in 160 patients of an average 63.3 years old, mean difference in Constant Score (8.2) and DASH score (10.2) between the injured and uninjured arm were relatively mild; they concluded that these numbers make it difficult to demonstrate an advantage of operative over nonoperative management of these injuries.²⁴ In addition, a recent JAMA randomized controlled trial (RCT) concluded that fractures involving the surgical neck do not benefit from surgery at 2 years following the injury.²⁵ Interestingly, two large meta-analyses from recent years looking specifically at 3- and 4-part fractures have indicated no clear advantage of operative intervention for proximal humerus fractures.^{26,27}

Other studies have cast more doubt on the utility of nonoperative management. A systematic review from the Journal of Shoulder and Elbow Surgery²⁸ looked at 66 studies including over 2000 patients. They determined that studies were highly variable and included only two studies with randomized groups. They concluded that we are limited in our ability to make clinical conclusions from these data. Other studies have now emerged indicating that operative treatment may have benefit compared to nonoperative treatment for 3- and 4-part fractures, as discussed below.²⁹

Open Reduction Internal Fixation

Multiple ORIF techniques have been compared to nonoperative management. Zyto et al. compared a tension band technique to nonoperative management but did not find a significant

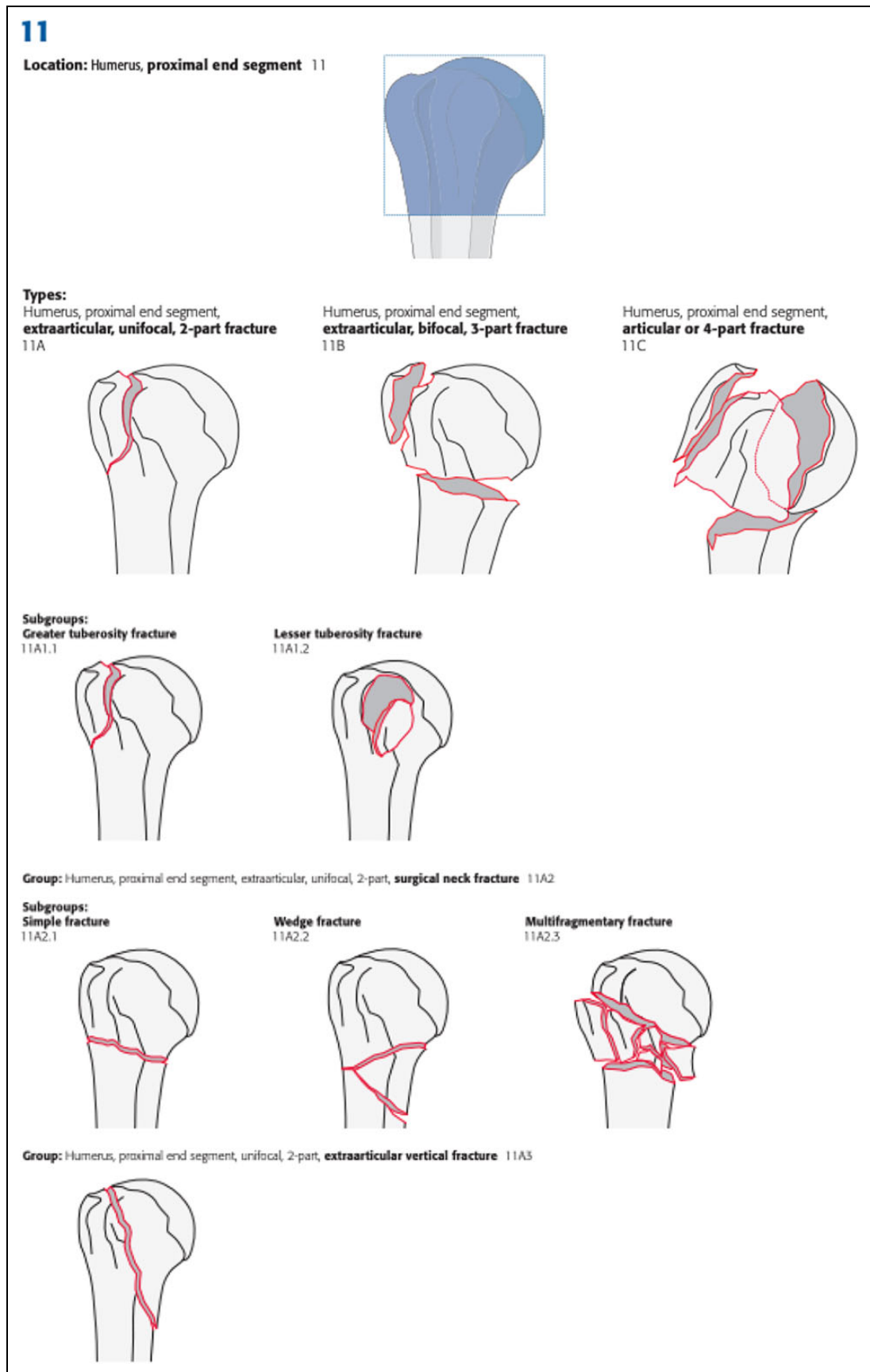


Figure 1. AO/OTA classification of proximal humerus fractures. Reproduced with permission from Meinberg, E. G., et al. "Fracture and Dislocation Classification Compendium—2018." *Journal of Orthopaedic Trauma* 32 (2018): S1-S10.

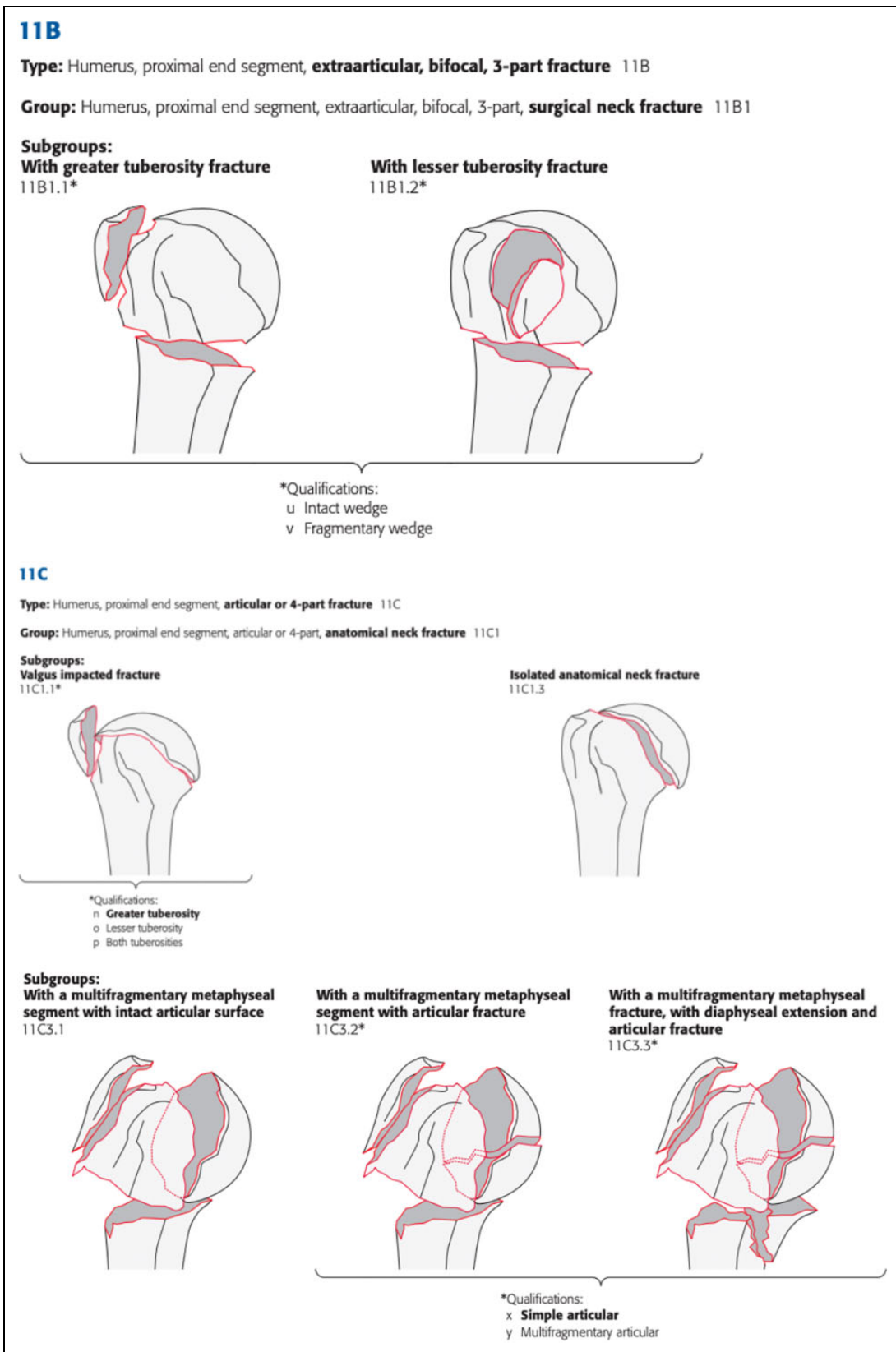


Figure 1. (Continued).

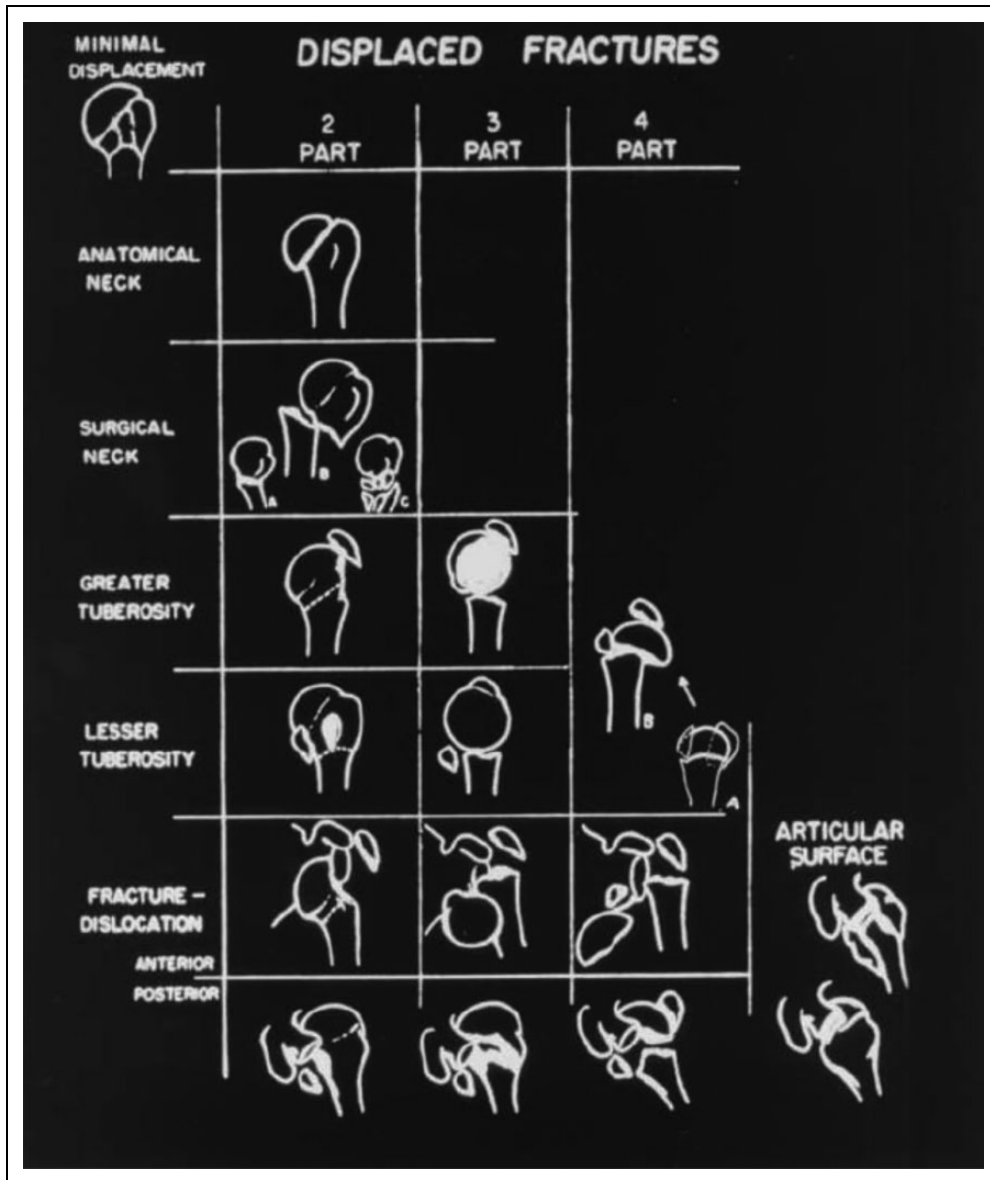


Figure 2. Neer classification of proximal humerus fractures. Reproduced with permission from Neer, Charles S. "Four-segment classification of proximal humeral fractures: purpose and reliable use." *Journal of shoulder and elbow surgery* 11.4 (2002): 389-400.

improvement in functional outcome at up to 5 years.³⁰ A retrospective study on tension bands with an average of 70 months of follow-up found that nonoperative management was superior for 3-part fractures but tension bands are superior for 4-part fractures.³¹

Olerud et al stated in 2011 that ORIF with a locking plate does "indicate an advantage" in function and quality of life, but the statistics were not significant and 30% of the patients needed additional surgery for complications following their ORIF.²⁹ Another study compared locking plates to nonoperative management and found significantly worse range of motion (ROM) and more complications and additional treatment in the locking plate group.³² A randomized clinical trial specifically looking at 3- and 4-part fracture compared to non-operative treatment found no evidence of benefit in

functional outcome or patient self-assessment, as only radiographic outcomes were better in the surgical group.³³ One retrospective study comparing ORIF versus hemiarthroplasty³⁴ did show improved patient-reported outcomes and quality of life scores in the ORIF group for complex articular fractures and fracture-dislocations.

Higher level studies have been performed, assessing the above studies and more.^{35,36} Meta-analysis and systematic review techniques do not identify an advantage of locking plate techniques over nonoperative management, including for 3- and 4-part fractures. Overall, while ORIF may provide some advantages for reconstructible fractures, benefit must be weighed against the high risk of reoperation,²⁹ decreased ROM,³² and risk of anesthesia and inpatient stay in an already-traumatized elderly patient.

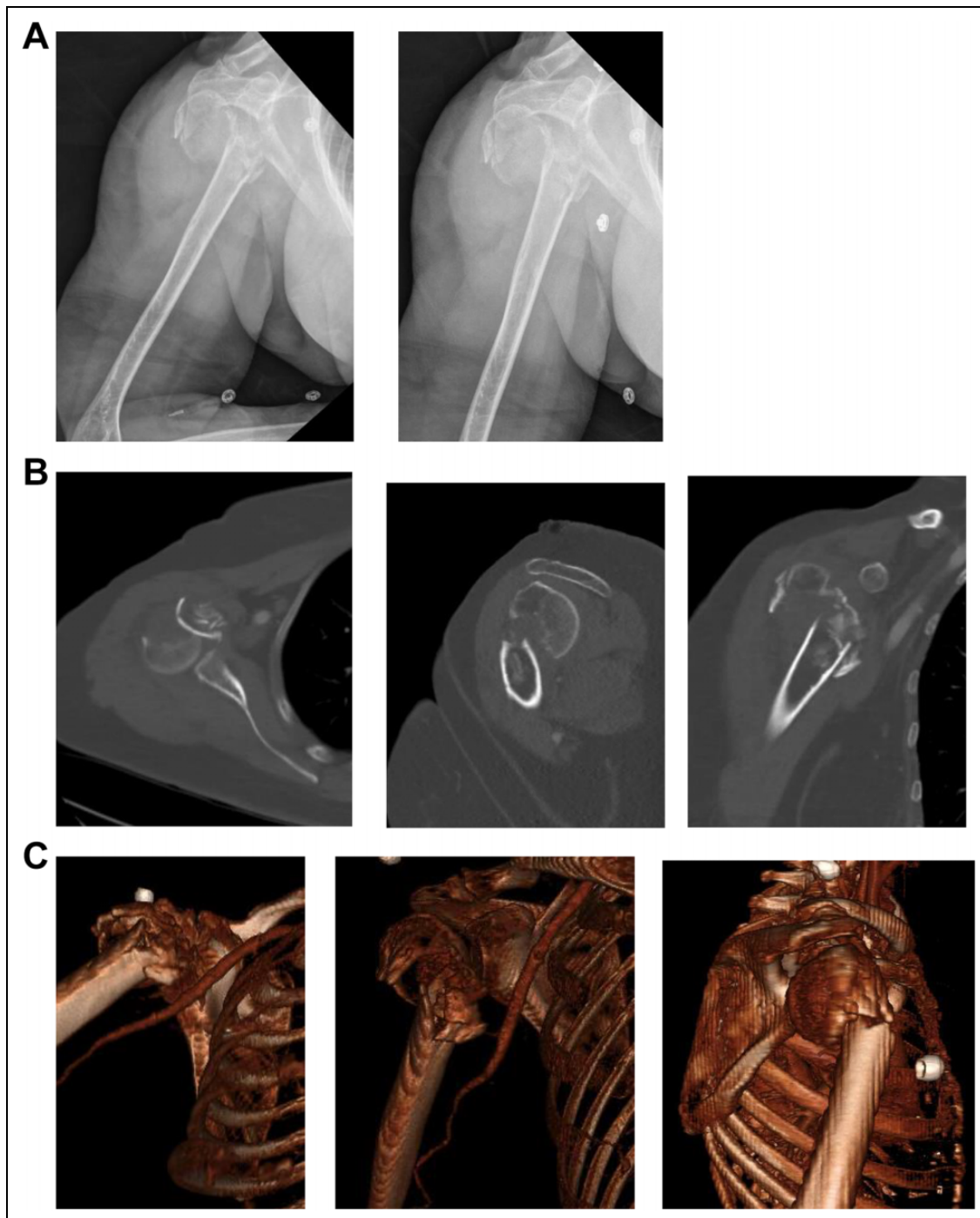


Figure 3. Comminuted proximal humerus fracture as assessed first with A) plain films followed by B) CT with C) 3D reconstruction. CT images show advanced detail useful for operative planning).

Hemiarthroplasty

Hemiarthroplasty can be of utility in the setting of high-energy proximal humerus injuries due to its lack of dependence on articular segment/neck fracture union and the lack of risk of humeral head avascular necrosis and screw cut-out. Multiple studies have been performed to elucidate whether hemiarthroplasty provides an advantage over nonoperative management.

Olerud et al in 2011 compared nonoperative management to hemiarthroplasty in the setting of 4-part fractures in an RCT. They found that health-related quality of life was better at two years in the hemiarthroplasty group, but disabilities of the arm, shoulder, and hand (DASH) scores, Constant scores, and range of motion were not statistically significantly different at two years.³⁷ Boons et al, in a similar RCT assessing 4-part fractures, found no differences in Constant Scores, Simple

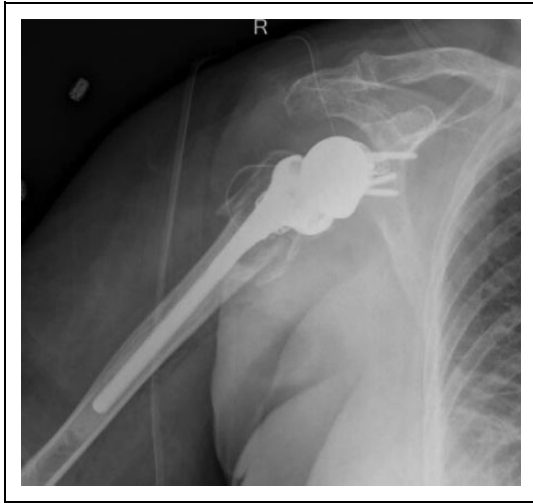

Figure 4. Patient from Figure 3 status post reverse total shoulder arthroplasty.

Shoulder Test scores, or pain at 12 months. Abduction strength was better in the nonoperative group at 12 months; they concluded that there are no clear advantages between the two treatment approaches.³⁸

Disadvantages of hemiarthroplasty include the necessity for tuberosity reduction and healing, but revision-free survival has been reported to be over 95% at over 10 years.³⁹ Grogan and Levine summarized in 2017 that hemiarthroplasty remains a cost-effective, durable option for active, older patients at risk for AVN or with unreconstructable fractures.⁴⁰

Reverse Total Shoulder Arthroplasty

rTSA has become a popular management strategy in recent years due to its lack of dependence on the rotator cuff for pain-free function and range of motion (Figure 4). There are now many published studies on its effectiveness in the setting of trauma.

Several recent studies have compared nonoperative management to rTSA. One study compared mortality retrospectively at one year between nonoperative management and rTSA and found no significant difference.⁴¹ A recent prospective RCT found no differences at 12 months for patient reported outcomes with the exception of 1.6 visual analog scale (VAS) pain score in the nonoperative group versus 0.9 in the operative group.⁴² A retrospective study compared nonoperative management with rTSA in 3- and 4-part fractures and found no difference in range of motion or patient-reported outcome.⁴³ A multicenter RTC found that Constant Scores are better at two years with rTSA as compared to nonoperative management with overall small clinical difference.⁴⁴

Regarding rTSA versus other operative managements, one study assessed a prospective cohort of patients undergoing rTSA as compared to retrospective cohorts who underwent ORIF or hemiarthroplasty. They found no differences in simple shoulder test (SST), American Shoulder and Elbow Surgeons

Score (ASES), or short form 12 (SF-12) scores but found significantly more forward flexion and less Medicare cost in the rTSA group.⁴⁵ Multiple other studies systematically reviewed by Mata-Fink et al⁴⁶ have shown that functional outcomes are significantly better with rTSA as compared to hemiarthroplasty,⁴⁷⁻⁵² exceeding the one study in their review⁴⁷ showing a slightly higher DASH score in hemiarthroplasty as compared to rTSA. Interestingly, another recent systematic review⁵³ found no significant differences in ASES or Constant Scores between rTSA and hemiarthroplasty and noted that complications were higher with rTSA, although this review included a prospective study showing better ASES and SST scores and better forward flexion with rTSA as compared to hemiarthroplasty⁵⁴ and a retrospective study including only 20 patients showing no difference in ASES and Oxford Scores.⁵⁵

A practical point in the treatment of proximal humerus fractures in elderly, high-energy trauma patients is that arthroplasty does not have to happen immediately. It is reasonable in a polytrauma patient at high risk for surgery to attempt a trial of nonoperative management followed by late rTSA if nonoperative management fails; these delayed rTSAs have been shown to have no difference in forward flexion, clinical outcome, or all-cause reoperation.⁵⁶ In fact, the delayed group in the study had significantly better external rotation than the acute group. Another study compared acute rTSA versus rTSA to salvage failed ORIF. The salvage group in this study was found to have slightly higher complications but overall no difference in clinical outcome, revision, or reoperation rate. The authors concluded that salvage rTSA after ORIF can still achieve good results.⁵⁷

Future Studies

Several studies are currently underway that will hopefully shed more definitive light on ideal treatment strategies.⁵⁵⁻⁶² RCTs are ongoing to assess nonoperative management, hemiarthroplasty, and rTSA. Perhaps with time these studies will more clearly direct treatment, including for high-energy geriatric patients.

Summary of Management

As noted above, there are many clinically reasonable options for treatment of proximal humerus fractures in the elderly patient (average ages of patients in pertinent treatment studies with open access at the authors' institution listed in Table 1). Nonoperative management is reasonable, with high union rates and low rates of AVN. Nonoperative strategies may be particularly beneficial in the acute, high-energy trauma patient with a proximal humerus fracture who may be at high morbidity and mortality risk with surgery. On the other hand, if the patient is healthy enough for surgery, immediate stabilization or arthroplasty may accelerate rehabilitation, providing overall benefit to the patient. ORIF may provide better radiographic outcomes and hold an advantage for complex intraarticular fractures and fracture-dislocations, but ORIF comes with a high complication rate. Hemiarthroplasty requires union of the tuberosities, but can be a good option for active elderly patients at high risk for AVN or screw cutout. rTSA has been shown in some

Table 1. Average Age Across Pertinent Treatment Studies With Open Access at Authors' Institution.

| (Reference) Study | Topic | Mean age (years) |
|--|--|---|
| ²³ Iyengar, Jaicharan J., et al. "Nonoperative treatment of proximal humerus fractures: a systematic review." <i>Journal of orthopaedic trauma</i> 25.10 (2011): 612-617 | Nonoperative Management | 65 |
| ²⁴ Hanson, Beate, et al. "Functional outcomes after nonoperative management of fractures of the proximal humerus." <i>Journal of Shoulder and Elbow Surgery</i> 18.4 (2009): 612-621. | Nonoperative Management | 63.3 |
| ²⁵ Rangan, Amar, et al. "Surgical vs nonsurgical treatment of adults with displaced fractures of the proximal humerus: the PROFHER randomized clinical trial." <i>Jama</i> 313.10 (2015): 1037-1047. | Nonoperative Management | 66 |
| ²⁷ Xie, Lin, et al. "Operative versus non-operative treatment in complex proximal humeral fractures: a meta-analysis of randomized controlled trials." <i>Springerplus</i> 4.1 (2015): 728. | Nonoperative Management | 65.6-79.9 in analyzed studies |
| ²⁸ Lanting, Brent, et al. "Proximal humeral fractures: a systematic review of treatment modalities." <i>Journal of shoulder and elbow surgery</i> 17.1 (2008): 42-54. | Nonoperative Management | 62.8 |
| ²⁹ Olerud, Per, et al. "Internal fixation versus nonoperative treatment of displaced 3-part proximal humeral fractures in elderly patients: a randomized controlled trial." <i>Journal of shoulder and elbow surgery</i> 20.5 (2011): 747-755. | Nonoperative Management | 73.9 |
| ³⁰ Zyto, Karol, et al. "Treatment of displaced proximal humeral fractures in elderly patients." <i>The Journal of bone and joint surgery. British volume</i> 79.3 (1997): 412-417. | Tension Band | 73 operative; 75 conservative |
| ³¹ Ilchmann, T., et al. "Non-operative treatment versus tension-band osteosynthesis in three-and four-part proximal humeral fractures." <i>International orthopaedics</i> 22.5 (1998): 316-320 | Tension Band | 61 operative; 73 nonoperative |
| ³² Sanders, Rick J., et al. "Locking plate versus nonsurgical treatment for proximal humeral fractures: better midterm outcome with nonsurgical treatment." <i>Journal of shoulder and elbow surgery</i> 20.7 (2011): 1118-1124. | Locking Plate | 58 operative; 64 nonoperative |
| ³³ Fjalestad, Tore, et al. "Surgical treatment with an angular stable plate for complex displaced proximal humeral fractures in elderly patients: a randomized controlled trial." <i>Journal of orthopaedic trauma</i> 26.2 (2012): 98-106. | Locking Plate | 72.2 operative; 73.1 nonoperative |
| ³⁴ Thorsness, Robert, et al. "Open reduction and internal fixation versus hemiarthroplasty in the management of proximal humerus fractures." <i>Geriatric orthopaedic surgery & rehabilitation</i> 5.2 (2014): 56-62. | ORIF versus Hemiarthroplasty | 64.2 ORIF; 69.3 hemiarthroplasty |
| ³⁵ Launonen, Antti P., et al. "Treatment of proximal humerus fractures in the elderly: a systematic review of 409 patients." <i>Acta orthopaedica</i> 86.3 (2015): 280-285. | Tension band, pinning, plating, hemiarthroplasty | 72-78 intervention across studies; 72-81 control across studies |
| ³⁶ Sun, Yangbai, et al. "Treatment of complex proximal humeral fracture: plate and tension band fixation versus conservative therapy." <i>International journal of clinical and experimental medicine</i> 8.5 (2015): 7143. | Tension band, plating, conservative management | 52.5-75 across studies |
| ³⁷ Olerud, Per, et al. "Hemiarthroplasty versus nonoperative treatment of displaced 4-part proximal humeral fractures in elderly patients: a randomized controlled trial." <i>Journal of shoulder and elbow surgery</i> 20.7 (2011): 1025-1033. | Hemiarthroplasty versus conservative | 75.8 hemiarthroplasty; 77.5 nonoperative |
| ³⁸ Boons, Harm W., et al. "Hemiarthroplasty for humeral four-part fractures for patients 65 years and older: a randomized controlled trial." <i>Clinical Orthopaedics and Related Research</i> 470.12 (2012): 3483-3491. | Hemiarthroplasty versus conservative | 76.4 hemiarthroplasty; 79.9 conservative |

(continued)

Table 1. (continued)

| (Reference) Study | Topic | Mean age (years) |
|--|---|--|
| ³⁹ Antuña, Samuel A., John W. Sperling, and Robert H. Cofield. "Shoulder hemiarthroplasty for acute fractures of the proximal humerus: a minimum five-year follow-up." <i>Journal of shoulder and elbow surgery</i> 17.2 (2008): 202-209. | Long-term results and complications of hemiarthroplasty | 66 at time of surgery |
| ⁴⁰ Grogan, Brian, and William N. Levine. "The continuing role of hemiarthroplasty in the treatment of proximal humerus fractures." <i>Seminars in Arthroplasty</i> . Vol. 28. No. 3. WB Saunders, 2017. | Review | N/A |
| ⁴¹ Grogan, Brian, and William N. Levine. "The continuing role of hemiarthroplasty in the treatment of proximal humerus fractures." <i>Seminars in Arthroplasty</i> . Vol. 28. No. 3. WB Saunders, 2017. | rTSA versus conservative | 82.2 rTSA; 83.7 conservative |
| ⁴² Lopiz, Yaiza, et al. "Reverse shoulder arthroplasty versus nonoperative treatment for 3-or 4-part proximal humeral fractures in elderly patients: a prospective randomized controlled trial." <i>Journal of Shoulder and Elbow Surgery</i> (2019). | rTSA versus conservative | 82 rTSA; 85 conservative |
| ⁴³ Roberson, Troy A., et al. "Nonoperative management versus reverse shoulder arthroplasty for treatment of 3-and 4-part proximal humeral fractures in older adults." <i>Journal of shoulder and elbow surgery</i> 26.6 (2017): 1017-1022. | rTSA versus conservative | 71 rTSA; 71 conservative |
| ⁴⁴ Chivot, Matthieu, et al. "Three-and four-part displaced proximal humeral fractures in patients older than 70 years: reverse shoulder arthroplasty or nonsurgical treatment?." <i>Journal of Shoulder and Elbow Surgery</i> 28.2 (2019): 252-259. | rTSA versus conservative | 77 rTSA; 79.2 conservative |
| ⁴⁵ Chalmers, Peter N., et al. "Reverse total shoulder arthroplasty for acute proximal humeral fracture: comparison to open reduction–internal fixation and hemiarthroplasty." <i>Journal of shoulder and elbow surgery</i> 23.2 (2014): 197-204. | rTSA, ORIF, hemiarthroplasty | 77 rTSA; 71 ORIF; 72 hemiarthroplasty |
| ⁴⁶ Mata-Fink, Ana, et al. "Reverse shoulder arthroplasty for treatment of proximal humeral fractures in older adults: a systematic review." <i>Journal of shoulder and elbow surgery</i> 22.12 (2013): 1737-1748. | rTSA versus hemiarthroplasty systematic review | Range 70-86 rTSA; 69-85 hemiarthroplasty |
| ⁴⁷ Gallinet, D., et al. "Three or four parts complex proximal humerus fractures: hemiarthroplasty versus reverse prosthesis: a comparative study of 40 cases." <i>Orthopaedics & Traumatology: Surgery & Research</i> 95.1 (2009): 48-55. | rTSA versus hemiarthroplasty | 74 rTSA; 74 hemarthroplasty |
| ⁵¹ Garrigues, Grant E., et al. "Hemiarthroplasty versus reverse total shoulder arthroplasty for acute proximal humerus fractures in elderly patients." <i>Orthopedics</i> 35.5 (2012): e703-e708. | rTSA versus hemiarthroplasty | 80.5 rTSA; 69.3 hemiarthroplasty |
| ⁵² Boyle, Matthew J., et al. "Functional outcomes of reverse shoulder arthroplasty compared with hemiarthroplasty for acute proximal humeral fractures." <i>Journal of shoulder and elbow surgery</i> 22.1 (2013): 32-37. | rTSA versus hemiarthroplasty | 79.6 rTSA; 71.9 hemiarthroplasty |
| ⁵³ Ferrel, Jason R., Thai Q. Trinh, and Richard A. Fischer. "Reverse total shoulder arthroplasty versus hemiarthroplasty for proximal humeral fractures: a systematic review." <i>Journal of orthopaedic trauma</i> 29.1 (2015): 60-68. | rTSA versus hemiarthroplasty systematic review | 77.1 average rTSA; 70.8 average hemiarthroplasty |

(continued)

Table 1. (continued)

| (Reference) Study | Topic | Mean age (years) |
|---|--|--------------------------------------|
| ⁵⁴ Cuff, Derek J., and Derek R. Pupello. "Comparison of hemiarthroplasty and reverse shoulder arthroplasty for the treatment of proximal humeral fractures in elderly patients." <i>JBS</i> 95.22 (2013): 2050-2055. | rTSA versus hemiarthroplasty | 74.4 average overall |
| ⁵⁵ Young, Simon W., et al. "Comparison of functional outcomes of reverse shoulder arthroplasty versus hemiarthroplasty in the primary treatment of acute proximal humerus fracture." <i>ANZ journal of surgery</i> 80.11 (2010): 789-793. | rTSA versus hemiarthroplasty | 77.2 rTSA; 75.5 hemiarthroplasty |
| ⁵⁶ Torchia, Michael T., et al. "Acute versus delayed reverse total shoulder arthroplasty for the treatment of proximal humeral fractures in the elderly population: a systematic review and meta-analysis." <i>Journal of shoulder and elbow surgery</i> (2019). | Acute versus delayed rTSA | 71.8 delayed; not reported for acute |
| ⁵⁷ Shannon, Steven F., et al. "Reverse shoulder arthroplasty for proximal humeral fractures: outcomes comparing primary reverse arthroplasty for fracture versus reverse arthroplasty after failed osteosynthesis." <i>Journal of shoulder and elbow surgery</i> 25.10 (2016): 1655-1660. | Primary rTSA versus RTSA after failed ORIF | 75 primary; 70 salvage |
| ⁵⁸ Launonen, Antti P., et al. "Conservative treatment, plate fixation, or prosthesis for proximal humeral fracture. A prospective randomized study." <i>BMC musculoskeletal disorders</i> 13.1 (2012): 167. | Not yet reported | Not yet reported |
| ⁵⁹ Den Hartog, Dennis, et al. "Primary hemiarthroplasty versus conservative treatment for comminuted fractures of the proximal humerus in the elderly (ProCon): a multicenter randomized controlled trial." <i>BMC musculoskeletal disorders</i> 11.1 (2010): 97. | Not yet reported | Not yet reported |
| ⁶⁰ Handoll, Helen, et al. "Protocol for the ProFHER (PROximal Fracture of the Humerus: Evaluation by Randomisation) trial: a pragmatic multi-centre randomised controlled trial of surgical versus non-surgical treatment for proximal fracture of the humerus in adults." <i>BMC musculoskeletal disorders</i> 10.1 (2009): 140. (Handoll, Helen, et al. "The ProFHER (PROximal Fracture of the Humerus: Evaluation by Randomisation) trial-a pragmatic multicentre randomised controlled trial evaluating the clinical effectiveness and cost-effectiveness of surgical compared with non-surgical treatment for proximal fracture of the humerus in adults." <i>Health Technology Assessment (Winchester, England)</i> 19.24 (2015): 1.) | Original protocol cited; results reported 2015 | 66.2 surgery; 65.8 not surgery |
| ⁶¹ Brorson, Stig, et al. "Effect of osteosynthesis, primary hemiarthroplasty, and non-surgical management for displaced four-part fractures of the proximal humerus in elderly: a multi-centre, randomised clinical trial." <i>Trials</i> 10.1 (2009): 51. | Not yet reported | Not yet reported |
| ⁶² Smith, Geoffrey CS, et al. "Reverse Shoulder Arthroplasty for the treatment of Proximal humeral fractures in the Elderly (ReShAPE trial): study protocol for a multicentre combined randomised controlled and observational trial." <i>Trials</i> 18.1 (2017): 91. | Not yet reported | Not yet reported |

high-quality studies to have slight advantages compared to nonoperative management or hemiarthroplasty, and rTSA can be performed after the acute clinical phase without compromising long-term results.

The author's preference (Figure 5) is to treat high-risk, frail patients with an initial course of non-operative management. If the patient is healthy enough for surgery and has a

high activity-level at baseline, minimal degenerative change, no pre-injury symptoms, and good bone quality, then ORIF is a reasonable option. If the patient has failed nonoperative management or has a complex injury pattern at high risk of AVN or ORIF failure, hemiarthroplasty or rTSA can be beneficial. This is an historic area of debate with broad terms, but we feel this algorithm provides general guidance.

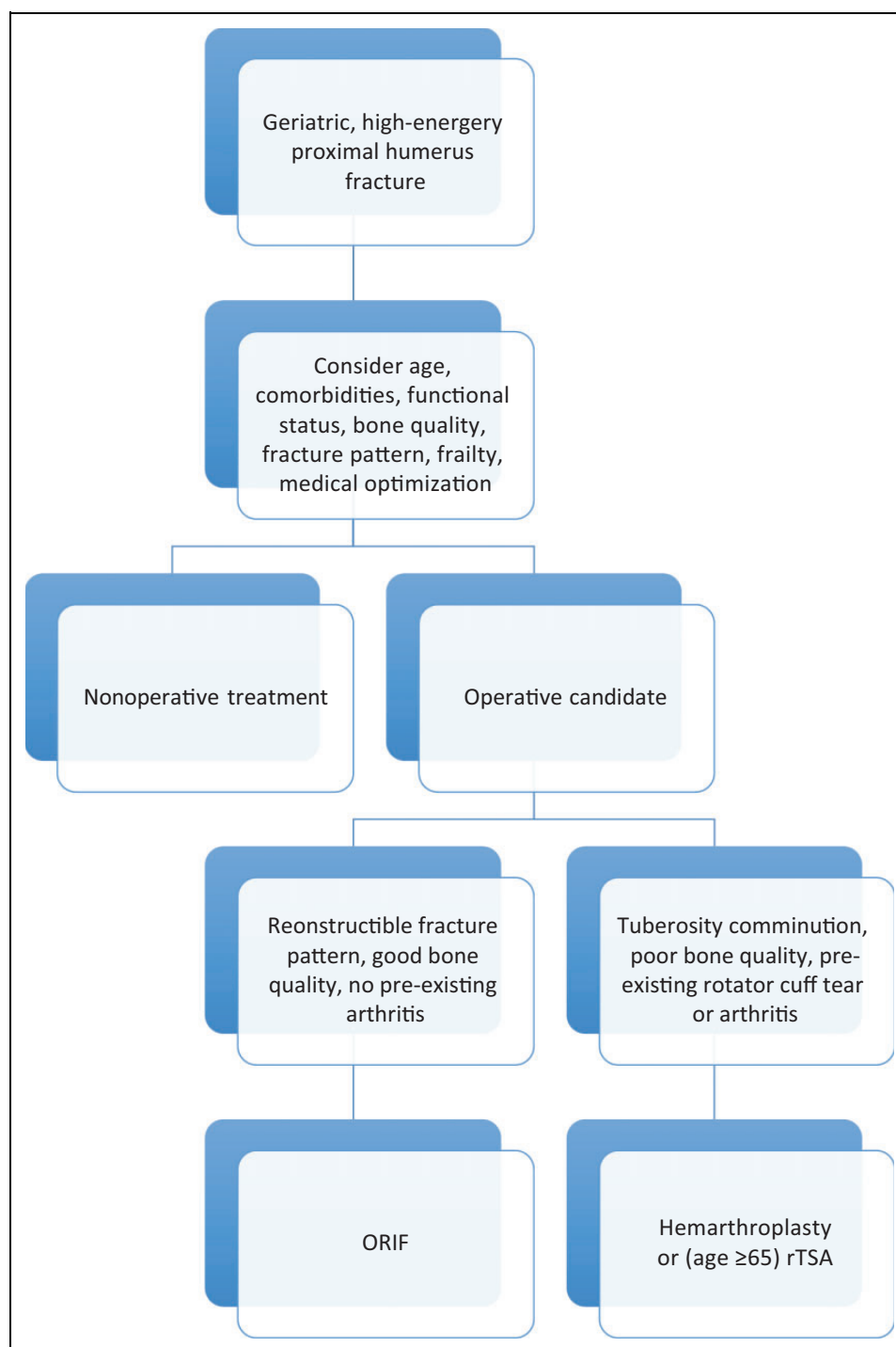


Figure 5. Author's preferred treatment algorithm.

Prevention

As extensive as management options are in treating high-energy proximal humerus fractures in the elderly, prevention of such injuries is clearly superior. Many studies have examined interventions that providers can take to optimize geriatric fitness to prevent falls and MVCs, specifically.

In 2017, around three million unintentional falls occurred in the U.S. prompting evaluation in emergency departments, with

over 870,000 of these patients requiring hospitalization.^{63,64} As noted above, even classically “low energy” mechanisms can lead to high ISS scores in geriatric patients.³ Falls from height and down stairs also result in polytrauma,² making fall prevention a potential key intervention in preventing some cases of polytraumatic injuries in the elderly. The United States Preventive Services Task Force (USPSTF) in its 2018 recommendation statement on fall prevention⁶⁴ recommended “exercise

interventions” in geriatric patients who are at increased risk for falls and recommended for “multifactorial interventions” for the same population. They recommend against vitamin D supplementation for patients who are not known to have osteoporosis and vitamin D deficiency. The recommendation for exercise interventions is based on systematic review of numerous RCTs from the U.S and elsewhere that show in general that three exercise sessions per week for 12 months can reduce fall-related fractures and falls that result in injury.⁶⁵ Multifactorial intervention recommendations are based on similar systematic review of RCTs in which various studies examined any number of components including balance, gait, vision, cardiovascular health, medication, environment, cognition, and psychological health. The reviewers found that individual studies did show reduced rates of falls and/or fall events per person-year, although pooled analysis of studies did not reveal a significant reduction (though it did trend toward a difference at $p = 0.09$). Malnutrition has also been shown to be associated with increased risk of falling and impaired activity in a Dutch study, with percentage of fallers lower in a malnourished group which underwent nutritional intervention ($p = 0.056$).⁶⁶

Motor vehicle collisions are another preventable mechanism of high energy trauma in geriatric patients. In 2017, 7700 adults over 65 years old were killed in MVCs, and over 257,000 were treated in emergency departments. As the population has aged in the United States, as of 2017 we have 44 million licensed drivers over 65, up 63% from 1999.⁶⁷ Fatal crash rates increase notably at age 70-74 and are highest among drivers 85 and older.⁶⁸ Increasing safety of driving in the geriatric population is multifactorial. The Eastern Association for the Surgery of Trauma (EAST) provided an evidence-based review of risk factors and prevention of MVCs in the elderly in 2015.⁶⁹ The group examined car engineering, environmental and behavioral interventions, and risk screening strategies. They noted that the Maximum Abbreviated Injury Scale is more likely to be 3 or higher in elderly patients with lower-severity crashes,⁴ and the authors recommended chest protection measures such as lower force airbags and more adaptable seat restraints. The EAST group noted in their environmental section that simply posting a reminder sign for seatbelt use outside of senior communities can result in improved seat belt use which remains substantial at four years post-intervention.^{70,71} Reducing elderly driving during evening hours may also pose a safety advantage.⁷² Regarding risk screening, the EAST group noted that patients with arrhythmias,⁷³ CAD, and DM⁷⁴ are at increased risk of MVCs. Hearing has also been noted to be related to risk of crash,⁷⁵ and cataract surgery has been shown to cut the crash rate in half compared to cataract patients who did not undergo surgery⁷⁶; reduction in useful visual field also increases crash risk.⁷⁷ Over 70% of elderly trauma patients with a positive alcohol screen were found to be legally intoxicated,⁷⁸ supporting alcohol abuse screening in geriatric drivers. These studies highlight multiple areas orthopaedic surgeons can screen and encourage elderly patients to treat to help ensure they avoid high-energy trauma.

A retrospective study comparing falls to MVCs in elderly patients has shown that falls are a strong predictor of mortality even when compared to MVCs. This study showed that MVC patients had an average ISS of 17.6 versus 5.8 in the fall patients overall, with ISS scores in fatal injuries at 14.2 for fall victims versus 15.1 for MVC patients.⁷⁹ Higher ISS was independently associated with mortality for both injury mechanisms; the authors concluded that trauma triage protocols should identify high-risk elderly patients and that serious consideration should be given to making geriatric specialists members of the trauma team.

Summary

In conclusion, high-energy proximal humerus fractures in elderly patients can occur through a variety of mechanisms, with falls and MVCs being common mechanisms of injury in this age group. Even classically low-energy mechanisms can result in elevated ISS scores, which are associated with higher mortality in both falls and MVCs. These injuries result in proximal humerus fractures which are commonly communicated via Neer’s classification scheme. There are many treatment options in the armamentarium of the treating surgeon. Non-operative management is widely supported by systematic review as compared to almost all other treatment methods. ORIF is particularly useful for complex patterns and fracture dislocations in healthy patients. Hemiarthroplasty can be of utility in patients with fracture patterns with high risk of AVN and poor bone quality risking screw cut-out. Reverse total shoulder arthroplasty is a popular method of treatment for geriatric patients also, with literature now showing that even late conversion from nonoperative management or ORIF to rTSA can lead to good clinical outcomes. Prevention is possible and important for geriatric patients. Optimizing medical care including hearing, vision, strength, and bone quality, in coordination with primary care and geriatricians, is of great importance in preventing fractures and decreasing injury when falls do occur. Involving geriatricians on dedicated trauma teams will also likely be of benefit.


Declaration of Conflicting Interests

The author(s) declared no potential conflicts of interest with respect to the research, authorship, and/or publication of this article.

Funding

The author(s) received no financial support for the research, authorship, and/or publication of this article.

ORCID iD

Jordan M. Walters, MD  <https://orcid.org/0000-0001-8256-4165>

References

1. Court-Brown CM, Garg A, McQueen MM. The epidemiology of proximal humeral fractures. *Acta Orthop Scand.* 2001;72(4): 365-371.

2. Clement ND, Aitken S, Duckworth AD, McQueen MM, Court-Brown CM. Multiple fractures in the elderly. *J Bone Joint Surg Br.* 2012;94(2):231-236.
3. Sterling DA, O'Connor JA, Bonadies J. Geriatric falls: injury severity is high and disproportionate to mechanism. *J Trauma Acute Care Surg.* 2001;50(1):116-119.
4. Augenstein J, Digges K, Bahouth G, Dalmotas D, Perdeck E, Stratton J. Investigation of the performance of safety systems for protection of the elderly. In: *Annual Proceedings/Association for the Advancement of Automotive Medicine*. Association for the Advancement of Automotive Medicine; 2005. Vol. 49.
5. Taylor MD, Tracy JK, Meyer W, Pasquale M, Napolitano LM. Trauma in the elderly: intensive care unit resource use and outcome. *J Trauma.* 2002;53(3):407-414.
6. Labib N, Nouh T, Winocour S. Severely injured geriatric population: morbidity, mortality, and risk factors. *J Trauma.* 2011;71(6):1908-1914.
7. Balas MC, Deutschman CS, Sullivan-Marx EM, Strumpf NE, Alston RP, Richmond TS. Delirium in older patients in surgical intensive care units. *J Nurs Scholarsh.* 2007;39(2):147-154.
8. Bulger EM, Arneson MA, Mock CN, Jurkovich GJ. Rib fractures in the elderly. *J Trauma.* 2000;48(6):1040-1047.
9. Susman M, DiRusso SM, Sullivan T, et al. Traumatic brain injury in the elderly: increased mortality and worse functional outcome at discharge despite lower injury severity. *J Trauma.* 2002;53(2):219-224.
10. Desai D, March R, Watters JM. Hyperglycemia after trauma increases with age. *J Trauma.* 1989;29(6):719-723.
11. Polanczyk CA, Marcantonio E, Goldman L, et al. Impact of age on perioperative complications and length of stay in patients undergoing noncardiac surgery. *Ann Intern Med.* 2001;134(8):637-643.
12. Keller JM, Sciadini MF, Sinclair E, O'Toole RV. Geriatric trauma: demographics, injuries, and mortality. *J Orthop Trauma.* 2012;26(9):e161-e165.
13. Abdelfattah A, Core MD, Cannada LK, Watson JT. Geriatric high-energy polytrauma with orthopedic injuries: clinical predictors of mortality. *Geriatr Orthop Surg Rehabil.* 2014;5(4):173-177.
14. Hettrich CM, Boraiah S, Dyke JP, Neviasser A, Helfet DL, Lorich DG. Quantitative assessment of the vascularity of the proximal part of the humerus. *J Bone Joint Surg Am.* 2010;92(4):943-948.
15. Meinberg EG, Agel J, Roberts CS, Karam MD, Kellam JF. Fracture and dislocation classification compendium—2018. *J Orthop Trauma.* 2018;32(suppl 1):S1-S10.
16. Neer CS. Four-segment classification of proximal humeral fractures: purpose and reliable use. *J Shoulder Elbow Surg.* 2002;11(4):389-400.
17. Bahrs C, Rolauffs B, Südkamp NP, et al. Indications for computed tomography (CT-) diagnostics in proximal humeral fractures: a comparative study of plain radiography and computed tomography. *BMC Musculoskelet Disord.* 2009;10(1):33.
18. Platzer P, Thalhammer G, Oberleitner G, et al. Displaced fractures of the greater tuberosity: a comparison of operative and nonoperative treatment. *J Trauma.* 2008;65(4):843-848.
19. Raymond AC, McCann PA, Sarangi PP. Magnetic resonance scanning vs axillary radiography in the assessment of glenoid version for osteoarthritis. *J Shoulder Elbow Surg.* 2013;22(8):1078-1083.
20. Nyffeler RW, Jost B, Pfirmann CW, Gerber C. Measurement of glenoid version: conventional radiographs versus computed tomography scans. *J Shoulder Elbow Surg.* 2003;12(5):493-496.
21. Zyto K. Non-operative treatment of comminuted fractures of the proximal humerus in elderly patients. *Injury.* 1998;29(5):349-352.
22. Rasmussen S, Hvass I, Dalsgaard J, Christensen BS, Holstad E. Displaced proximal humeral fractures: results of conservative treatment. *Injury.* 1992;23(1):41-43.
23. Iyengar JJ, Devcic Z, Sproul RC, Feeley BT. Nonoperative treatment of proximal humerus fractures: a systematic review. *J Orthop Trauma.* 2011;25(10):612-617.
24. Hanson B, Neidenbach P, de Boer P, Stengel D. Functional outcomes after nonoperative management of fractures of the proximal humerus. *J Shoulder Elbow Surg.* 2009;18(4):612-621.
25. Rangan A, Handoll H, Brealey S, et al. Surgical vs nonsurgical treatment of adults with displaced fractures of the proximal humerus: the PROFHER randomized clinical trial. *JAMA.* 2015;313(10):1037-1047.
26. Mao Z, Zhang L, Zhang L, et al. Operative versus nonoperative treatment in complex proximal humeral fractures. *Orthopedics.* 2014;37(5):e410-e419.
27. Xie L, Ding F, Zhao Z, Chen Y, Xing D. Operative versus non-operative treatment in complex proximal humeral fractures: a meta-analysis of randomized controlled trials. *Springerplus.* 2015;4(1):728.
28. Lanting B, MacDermid J, Drosdowech D, Faber KJ. Proximal humeral fractures: a systematic review of treatment modalities. *J Shoulder Elbow Surg.* 2008;17(1):42-54.
29. Olerud P, Ahrengart L, Ponzer S, Saving J, Tidermark J. Internal fixation versus nonoperative treatment of displaced 3-part proximal humeral fractures in elderly patients: a randomized controlled trial. *J Shoulder Elbow Surg.* 2011;20(5):747-755.
30. Zyto K, Ahrengart L, Sperber A, Törnkvis H. Treatment of displaced proximal humeral fractures in elderly patients. *J Bone Joint Surg Br.* 1997;79(3):412-417.
31. Ilchmann T, Ochsner PE, Wingstrand H, Jonsson K. Non-operative treatment versus tension-band osteosynthesis in three-and four-part proximal humeral fractures. *Int Orthop.* 1998;22(5):316-320.
32. Sanders RJ, Thissen LG, Teepen JC, van Kampen A, Jaarsma RL. Locking plate versus nonsurgical treatment for proximal humeral fractures: better midterm outcome with nonsurgical treatment. *J Shoulder Elbow Surg.* 2011;20(7):1118-1124.
33. Fjalestad T, Hole MØ, Hovden IA, Blücher J, Strømsøe K. Surgical treatment with an angular stable plate for complex displaced proximal humeral fractures in elderly patients: a randomized controlled trial. *J Orthop Trauma.* 2012;26(2):98-106.
34. Thorsness R, Iannuzzi J, Noyes K, Kates S, Voloshin I. Open reduction and internal fixation versus hemiarthroplasty in the management of proximal humerus fractures. *Geriatr Orthop Surg Rehabil.* 2014;5(2):56-62.

35. Launonen AP, Lepola V, Flinkkilä T, Laitinen M, Paavola M, Malmivaara A. Treatment of proximal humerus fractures in the elderly: a systematic review of 409 patients. *Acta Orthop*. 2015; 86(3):280-285.
36. Sun Y, Li L, Dai J, Wang T. Treatment of complex proximal humeral fracture: plate and tension band fixation versus conservative therapy. *Int J Clin Exp Med*. 2015;8(5):7143-7151.
37. Olerud P, Ahrengart L, Ponzer S, Saving J, Tidermark J. Hemiarthroplasty versus nonoperative treatment of displaced 4-part proximal humeral fractures in elderly patients: a randomized controlled trial. *J Shoulder Elbow Surg*. 2011;20(7):1025-1033.
38. Boons HW, Goosen JH, van Grinsven S, van Susante JL, van Loon CJ. Hemiarthroplasty for humeral four-part fractures for patients 65 years and older: a randomized controlled trial. *Clin Orthop Relat Res*. 2012;470(12):3483-3491.
39. Antuña SA, Sperling JW, Cofield RH. Shoulder hemiarthroplasty for acute fractures of the proximal humerus: a minimum five-year follow-up. *J Shoulder Elbow Surg*. 2008;17(2):202-209.
40. Grogan B, Levine WN. The continuing role of hemiarthroplasty in the treatment of proximal humerus fractures. In Blaine T, Wiater JM, ed *Seminars in Arthroplasty*. WB Saunders; 2017. Vol. 28(3).
41. Rotman D, Giladi O, Senderey AB, et al. Mortality after complex displaced proximal humerus fractures in elderly patients: conservative versus operative treatment with reverse total shoulder arthroplasty. *Geriatr Orthop Surg Rehabil*. 2018;9:215145931 8795241.
42. Lopiz Y, Alcobia-Díaz B, Galán-Olleros M, García-Fernández C, Picado AL, Marco F. Reverse shoulder arthroplasty versus non-operative treatment for 3-or 4-part proximal humeral fractures in elderly patients: a prospective randomized controlled trial. *J Shoulder Elbow Surg*. 2019;28(12):2259-2271.
43. Roberson TA, Granade CM, Hunt Q, et al. Nonoperative management versus reverse shoulder arthroplasty for treatment of 3-and 4-part proximal humeral fractures in older adults. *J Shoulder Elbow Surg*. 2017;26(6):1017-1022.
44. Chivot M, Lami D, Bizzozero P, Galland A, Argenson JN. Three-and four-part displaced proximal humeral fractures in patients older than 70 years: reverse shoulder arthroplasty or nonsurgical treatment? *J Shoulder Elbow Surg*. 2019;28(2):252-259.
45. Chalmers PN, Slikker III W, Mall NA, et al. Reverse total shoulder arthroplasty for acute proximal humeral fracture: comparison to open reduction-internal fixation and hemiarthroplasty. *J Shoulder Elbow Surg*. 2014;23(2):197-204.
46. Mata-Fink A, Meinke M, Jones C, Kim B, Bell JE. Reverse shoulder arthroplasty for treatment of proximal humeral fractures in older adults: a systematic review. *J Shoulder Elbow Surg*. 2013;22(12):1737-1748.
47. Gallinet D, Clappaz P, Garbuio P, Tropet Y, Obert L. Three or four parts complex proximal humerus fractures: hemiarthroplasty versus reverse prosthesis: a comparative study of 40 cases. *Orthop Traumatol Surg Res*. 2009;95(1):48-55.
48. Hanssens K, Stoffelen D, Fortems Y. *Le traitement des fractures threeand four- part: comparaison fonctionnelle entre les protheses inversees (Delta III) et les hemi-protheses*. *Folia Traumatol Belg*; 2005:30-39.
49. Sirveaux F, Mole D, Boileau P. The reversed prosthesis. In Warner JJ, Iannotti JP, Flatow E. ed. *Complex and Revision Problems in Shoulder Surgery*. Lippincott Williams and Wilkins; 2006: 497-511. 35.
50. Sirveaux F, Navez G, Favard L, Boileau P, Walch G, Mole D. Reverse prosthesis for acute proximal humerus fracture, the multicentric study. In Walch G, Boileau P, Mole D. ed *Reverse Shoulder Arthroplasty: Clinical Results, Complications, Revisions*. Sauramps Medical; 2006:73-80.
51. Garrigues GE, Johnston PS, Pepe MD, Tucker BS, Ramsey ML, Austin LS. Hemiarthroplasty versus reverse total shoulder arthroplasty for acute proximal humerus fractures in elderly patients. *Orthopedics*. 2012;35(5):e703-e708.
52. Boyle MJ, Youn SM, Frampton CM, Ball CM. Functional outcomes of reverse shoulder arthroplasty compared with hemiarthroplasty for acute proximal humeral fractures. *J Shoulder Elbow Surg*. 2013;22(1):32-37.
53. Ferrel JR, Trinh TQ, Fischer RA. Reverse total shoulder arthroplasty versus hemiarthroplasty for proximal humeral fractures: a systematic review. *J Orthop Trauma*. 2015;29(1):60-68.
54. Cuff DJ, Pupello DR. Comparison of hemiarthroplasty and reverse shoulder arthroplasty for the treatment of proximal humeral fractures in elderly patients. *J Bone Joint Surg Am*. 2013; 95(22):2050-2055.
55. Young SW, Segal BS, Turner PC, Poon PC. Comparison of functional outcomes of reverse shoulder arthroplasty versus hemiarthroplasty in the primary treatment of acute proximal humerus fracture. *ANZ J Surg*. 2010;80(11):789-793.
56. Torchia MT, Austin DC, Cozzolino N, Jacobowitz L, Bell JE. Acute versus delayed reverse total shoulder arthroplasty for the treatment of proximal humeral fractures in the elderly population: a systematic review and meta-analysis. *J Shoulder Elbow Surg*. 2019;28(4):765-773.
57. Shannon SF, Wagner ER, Houdek MT, Cross III WW, Sánchez-Sotelo J. Reverse shoulder arthroplasty for proximal humeral fractures: outcomes comparing primary reverse arthroplasty for fracture versus reverse arthroplasty after failed osteosynthesis. *J Shoulder Elbow Surg*. 2016;25(10):1655-1660.
58. Launonen AP, Lepola V, Flinkkilä T, et al. Conservative treatment, plate fixation, or prosthesis for proximal humeral fracture. A prospective randomized study. *BMC Musculoskelet Disord*. 2012;13(1):167.
59. Den Hartog D, Van Lieshout EM, Tuinebreijer WE, et al. Primary hemiarthroplasty versus conservative treatment for comminuted fractures of the proximal humerus in the elderly (ProCon): a multicenter randomized controlled trial. *BMC Musculoskelet Disord*. 2010;11(1):97.
60. Handoll H, Brealey S, Rangan A, et al. Protocol for the ProFHER (PROximal Fracture of the Humerus: Evaluation by Randomisation) trial: a pragmatic multi-centre randomised controlled trial of surgical versus non-surgical treatment for proximal fracture of the humerus in adults. *BMC Musculoskelet Disord*. 2009;10(1):140.

61. Brorson S, Olsen BS, Frich LH, et al. Effect of osteosynthesis, primary hemiarthroplasty, and non-surgical management for displaced four-part fractures of the proximal humerus in elderly: a multi-centre, randomised clinical trial. *Trials*. 2009;10(1):51.
62. Smith GC, Bateman E, Cass B, et al. Reverse Shoulder Arthroplasty for the treatment of Proximal humeral fractures in the Elderly (ReShAPE trial): study protocol for a multicentre combined randomised controlled and observational trial. *Trials*. 2017; 18(1):91.
63. CDC WISQARS, Unintentional Fall Nonfatal Emergency Department Visits and Rates per 100,000. Accessed January 2020. <https://webappa.cdc.gov/sasweb/ncipc/nfirates.html>
64. Grossman DC, Curry SJ, Owens DK, et al. Interventions to prevent falls in community-dwelling older adults: US Preventive Services Task Force recommendation statement. *JAMA*. 2018; 319(16):1696-1704.
65. Guirguis-Blake JM, Michael YL, Perdue LA, Coppola EL, Beil TL. Interventions to prevent falls in older adults: updated evidence report and systematic review for the US Preventive Services Task Force. *JAMA*. 2018;319(16):1705-1716.
66. Neyens J, Halfens R, Spreuwenberg M, et al. Malnutrition is associated with an increased risk of falls and impaired activity in elderly patients in Dutch residential long-term care (LTC): a cross-sectional study. *Arch Gerontol Geriatr*. 2013;56(1):265-269.
67. CDC. Older Adult Drivers. Accessed January 13, 2020. https://www.cdc.gov/motorvehiclesafety/older_adult_drivers/index.html
68. Insurance Institute for Highway Safety, Highway Loss Data Institute. Fatality Facts 2018 Older people. 2019. Accessed January 2020. <https://www.iihs.org/topics/fatality-statistics/detail/older-people#fn2ref1>
69. Crandall M, Streams J, Duncan T, et al. Motor vehicle collision-related injuries in the elderly: an Eastern Association for the Surgery of Trauma evidence-based review of risk factors and prevention. *J Trauma*. 2015;79(1):152-158.
70. Cox BS, Cox AB, Cox DJ. Motivating signage prompts safety belt use among drivers exiting senior communities. *J Appl Behav Anal*. 2000;33(4):635-638.
71. Cox CD, Cox BS, Cox DJ. Long-term benefits of prompts to use safety belts among drivers exiting senior communities. *J Appl Behav Anal*. 2005;38(4):533-536.
72. Renner CH, Heldt KA, Swegle JR. Diurnal variation and injury due to motor vehicle crashes in older trauma patients. *Traffic Inj Prev*. 2011;12(6):593-598.
73. Gresset J, Meyer F. Risk of automobile accidents among elderly drivers with impairments or chronic diseases. *Can J Public Health*. 1994;85(4):282-285.
74. Koepsell TD, Wolf ME, McCloskey L, et al. Medical conditions and motor vehicle collision injuries in older adults. *J Am Geriatr Soc*. 1994;42(7):695-700.
75. McCloskey LW, Koepsell TD, Wolf ME, Buchner DM. Motor vehicle collision injuries and sensory impairments of older drivers. *Age Ageing*. 1994;23(4):267-273.
76. Owsley C, McGwin G Jr, Sloane M, Wells J, Stalvey BT, Gauthreaux S. Impact of cataract surgery on motor vehicle crash involvement by older adults. *JAMA*. 2002;288(7):841-849.
77. Owsley C, Ball K, McGwin G Jr, et al. Visual processing impairment and risk of motor vehicle crash among older adults. *JAMA*. 1998;279(14):1083-1088.
78. Zautcke JL, Coker Jr SB, Morris RW, Stein-Spencer L. Geriatric trauma in the state of Illinois: substance use and injury patterns. *Am J Emerg Med*. 2002;20(1):14-17.
79. Sampalis JS, Nathanson R, Vaillancourt J, et al. Assessment of mortality in older trauma patients sustaining injuries from falls or motor vehicle collisions treated in regional level I trauma centers. *Ann Surg*. 2009;249(3):488-495.