

# Lower extremity regional anesthesia: essentials of our current understanding

De Q Tran,<sup>1</sup> Francis V Salinas,<sup>2</sup> Honorio T Benzon,<sup>3</sup> Joseph M Neal<sup>4</sup>

► Additional material is published online only. To view these files, please visit the journal online (<http://dx.doi.org/10.1136/rapm-2018-000019>).

<sup>1</sup>Department of Anesthesiology, McGill University, Montreal, Quebec, Canada

<sup>2</sup>Department of Anesthesiology, US Anesthesia Partners-Washington, Swedish Medical Center, Seattle, Washington, USA

<sup>3</sup>Department of Anesthesiology, Northwestern University Feinberg School of Medicine, Chicago, Illinois, USA

<sup>4</sup>Department of Anesthesiology, Virginia Mason Medical Center, Seattle, Washington, USA

## Correspondence to

De Q Tran, Department of Anesthesia, St. Mary's Hospital, Montreal, QC H3T-1M5, Canada; [de\\_tran@hotmail.com](mailto:de_tran@hotmail.com)

Received 20 February 2018

Revised 14 May 2018

Accepted 23 May 2018

Published Online First

11 January 2019

## ABSTRACT

The advent of ultrasound guidance has led to a renewed interest in regional anesthesia of the lower limb. In keeping with the American Society of Regional Anesthesia and Pain Medicine's ongoing commitment to provide intensive evidence-based education, this article presents a complete update of the 2005 comprehensive review on lower extremity peripheral nerve blocks. The current review article strives to (1) summarize the pertinent anatomy of the lumbar and sacral plexuses, (2) discuss the optimal approaches and techniques for lower limb regional anesthesia, (3) present evidence to guide the selection of pharmacological agents and adjuvants, (4) describe potential complications associated with lower extremity nerve blocks, and (5) identify informational gaps pertaining to outcomes, which warrant further investigation.

## INTRODUCTION

Historically, lower extremity nerve blocks have been less widely used than their brachial plexus counterparts.<sup>1</sup> Reasons may include the fact that anesthesia of the lower limb requires blockade of several different nerves, whereas neuraxial blocks can provide intraoperative anesthesia and postoperative analgesia with a single puncture site. Furthermore, the depth of many nerves supplying the lower limb also constitutes a physical deterrent. However, since the new millennium, factors such as the increasing use of antithromboembolic prophylaxis and the advent of ultrasound (US) guidance have led to a renewed interest in regional anesthesia of the lower limb. In 2005, *Regional Anesthesia and Pain Medicine* published a review article that summarized the essentials of the contemporary understanding of lower extremity peripheral nerve blockade.<sup>1</sup> In the last 13 years, the field has progressed by leaps and bounds, as novel anatomical concepts (eg, paraneurium and subparaneurial compartment), new blocks (ie, femoral triangle and adductor canal blocks), improved descriptions for US-guided techniques (eg, "Shamrock" lumbar plexus block), and novel applications (eg, motor-sparing nerve blocks for total knee arthroplasty) have emerged in the literature. In light of the temporal gap between the current and previous review article, we have elected not to carry out a simple update but to address the topic in its entirety. Although the current review article does not aim to set medico-legal standards, it does strive to (1) summarize the pertinent anatomy of the lumbar and sacral plexuses, (2) discuss the optimal approaches and techniques for lower limb regional anesthesia,

(3) present the available evidence to guide the selection of pharmacological agents and adjuvants, (4) describe potential complications associated with lower extremity nerve blocks, and (5) identify informational gaps pertaining to outcomes, which warrant further investigation.

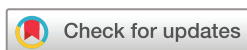## NEUROANATOMY OF THE LOWER LIMB

Lower extremity peripheral nerve blocks require a thorough understanding of the neuroanatomy of the lumbosacral plexus ([figure 1](#)), which is formed from the ventral primary rami of the 12th thoracic to the fourth sacral spinal nerves (T12–S4)<sup>2</sup> and provides sensory as well as motor innervation to the entire lower extremity, including the hip, knee, and ankle joints. The lumbosacral trunk (L4–S1) provides an anatomical communication between the lumbar and sacral plexus. However, for functional purposes, the two plexuses are usually considered distinct clinical entities and will be hereby discussed separately. Branches of the lumbar plexus include the iliohypogastric, ilioinguinal, genitofemoral, lateral femoral cutaneous, femoral, and obturator nerves. Of these, the lateral femoral cutaneous, femoral, and obturator nerves are the most important for lower extremity anesthesia and analgesia. The lumbar plexus usually lies deep within the substance of the psoas major muscle, anterior to the transverse processes of L1–L4 vertebrae whereas the sacral plexus can be found within the pelvis anterior to the piriformis muscle. The sacral plexus gives rise to 12 peripheral nerves, but the sciatic and posterior femoral cutaneous nerves are the most pertinent for lower extremity anesthesia and analgesia.

There exists a multitude of anatomical approaches and nerve localization techniques to anesthetize the lumbar plexus, sacral plexus, and their peripheral branches. Thus, a review of the anatomical course of the two plexuses and their most relevant peripheral nerves is warranted.

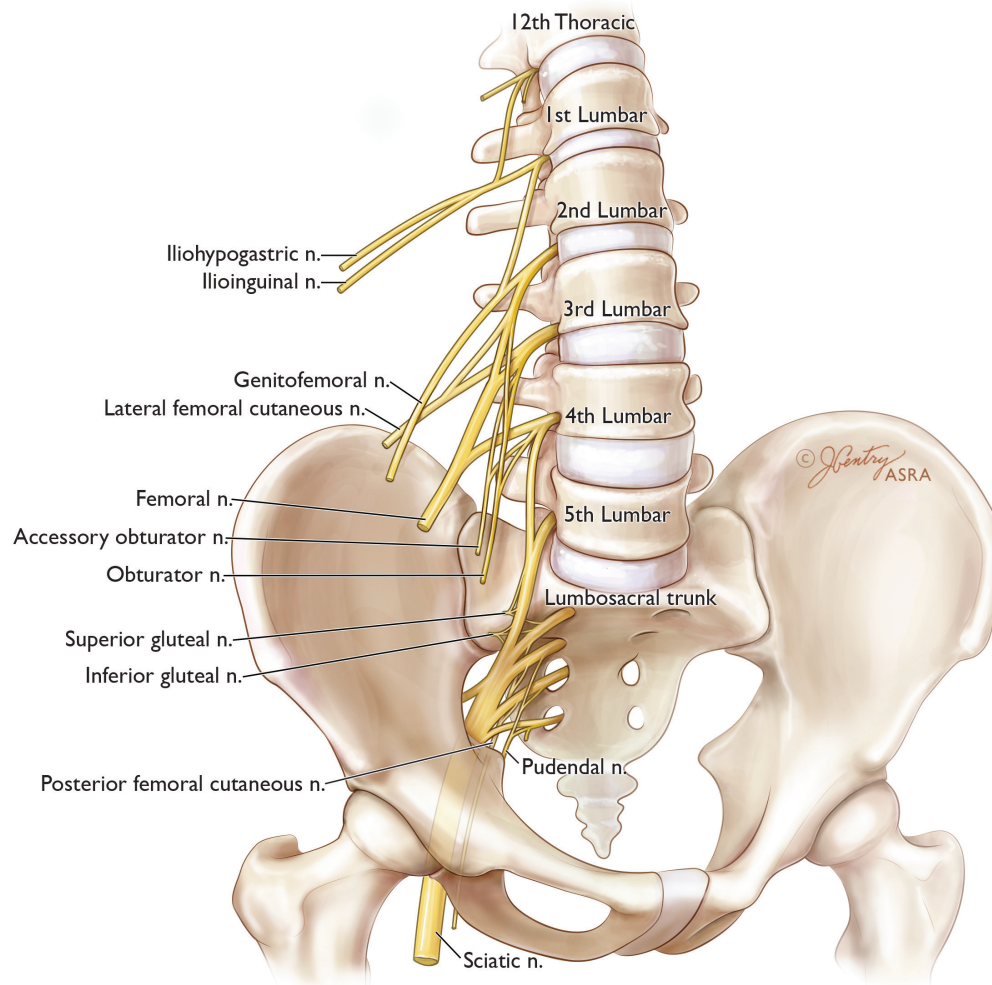
## Lumbar plexus anatomy

As the L1–L4 spinal nerve roots emerge from their respective intervertebral foramina, they lie anterior to the corresponding transverse processes and are typically embedded within a fascial plane located between the anterior and posterior portions of the psoas major muscle.<sup>3–9</sup> The smaller posterior layer of the psoas major originates from the anterior surfaces and lower borders of the L1–L5 transverse processes while the larger anterior layer originates from the lateral surfaces of the respective vertebral bodies and intervertebral discs.<sup>3–9</sup> Cadaveric and imaging studies have demonstrated that the lumbar



© American Society of Regional Anesthesia & Pain Medicine 2019. No commercial re-use. See rights and permissions. Published by BMJ.

**To cite:** Tran DQ, Salinas FV, Benzon HT,



**Figure 1** Idealized lumbar and sacral plexuses. Illustration by Jennifer Gentry. Copyright Jennifer Gentry, American Society of Regional Anesthesia and Pain Medicine.

plexus may also be located between the posterior border of the psoas major and the anterior border of the quadratus lumborum muscle in a small percentage of the population.<sup>8–10</sup> Within the psoas major, the ventral rami divide into anterior and posterior branches, which subsequently reunite to give rise to the individual peripheral nerves of the lumbar plexus. These nerves descend vertically within the mass of the psoas major. At the level of the L4–L5 transverse processes, the lateral femoral cutaneous nerve is located in the lateral portion of the psoas major, the obturator is situated medially, and the femoral nerve can be found between these two nerves. Although the lateral femoral cutaneous and femoral nerves lie within the same fascial plane, the obturator nerve is often separated (50%–60% of the time) from the other two nerves and contained within its own muscular fold inside the psoas major.<sup>3,6</sup> At the L4–L5 level, the anterior-to-posterior distance between the transverse processes and the lumbar plexus is consistently less than 2 cm, and rarely greater than 2.5 cm.<sup>5,8,10,11</sup>

### Femoral nerve

The femoral nerve is formed by the dorsal divisions of the ventral rami of the L2–L4 spinal nerves. The femoral nerve is the largest terminal branch of the lumbar plexus and typically emerges from the posterolateral or posterior surface of the psoas major and

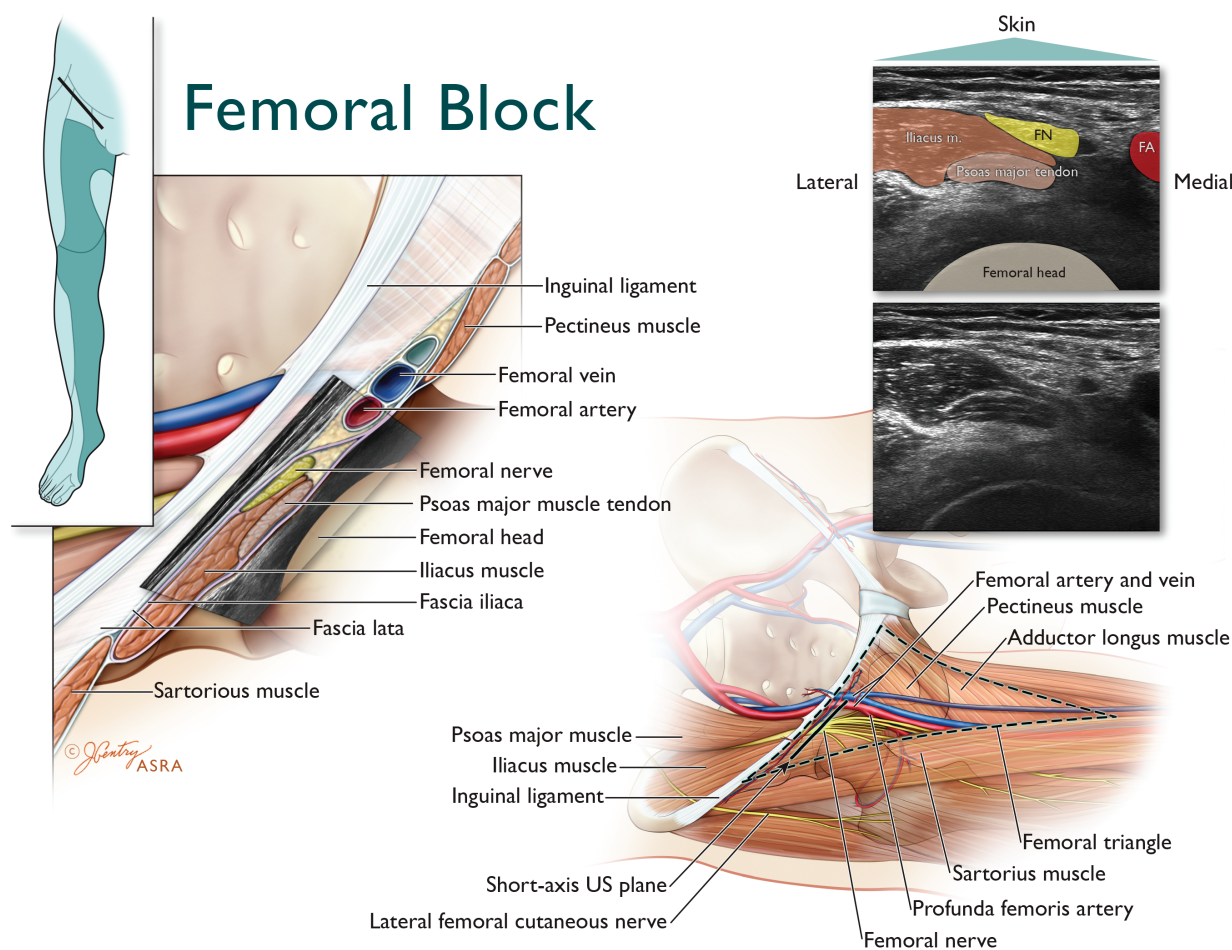
courses caudally in a muscular groove between the psoas major and underlying iliacus muscle. Within the pelvis, the femoral nerve supplies muscular branches to the iliacus and pectineus muscles, as well as an articular branch to the hip joint.<sup>12,13</sup>

The femoral nerve subsequently enters the base of the femoral triangle in the proximal thigh by passing deep (dorsal) to the inguinal ligament. The boundaries of femoral triangle are formed by the following structures (figures 2 and 3):

1. The inguinal ligament (superior border or base).
2. The medial margin of the sartorius muscle (lateral border).
3. The medial margin of the adductor longus muscle (medial border).

The apex of the femoral triangle is defined by the intersection of the medial border of the sartorius and the medial border of the adductor longus. In contrast, the intersection of the medial border of the sartorius muscle and the lateral border of the adductor longus muscle corresponds to the apex of the iliopectineal fossa, which constitutes a proximal subset of the femoral triangle.<sup>14,15</sup> The lateral and medial floors of the iliopectineal fossa are formed by the iliacus/psoas major and pectineus/adductor longus muscles, respectively. The roof of the iliopectineal fossa is made up by the overlying fascia lata.

At the level of the inguinal ligament, the femoral nerve is located within the iliopectineal fossa and is typically 1 to 2 cm



**Figure 2** Anatomy of the ultrasound-guided femoral nerve block (FNB). Top left inset depicts the transducer location and expected cutaneous sensory distribution after FNB. The femoral nerve (FN) enters the base of the femoral triangle in the proximal anterior thigh by passing dorsal to the inguinal ligament. The femoral nerve is located within the iliopectineal fossa just lateral or posterolateral to femoral artery (FA) and lies ventral to the iliacus muscle. The magnified axial view illustrates that within the iliopectineal fossa, the FN is located dorsal to the fascia iliaca, while the femoral vessels (located within the femoral sheath) are found ventral to the fascia iliaca. The corresponding short-axis ultrasound image of the FNB is obtained by placing the transducer in an axial oblique position distal to the inguinal ligament. The FN appears as a hyperechoic oval-shaped structure lying directly on the relatively hypoechoic iliacus muscle and just dorsal to the thin hyperechoic linear fascia iliaca. Illustration by Jennifer Gentry. Copyright Jennifer Gentry, American Society of Regional Anesthesia and Pain Medicine.

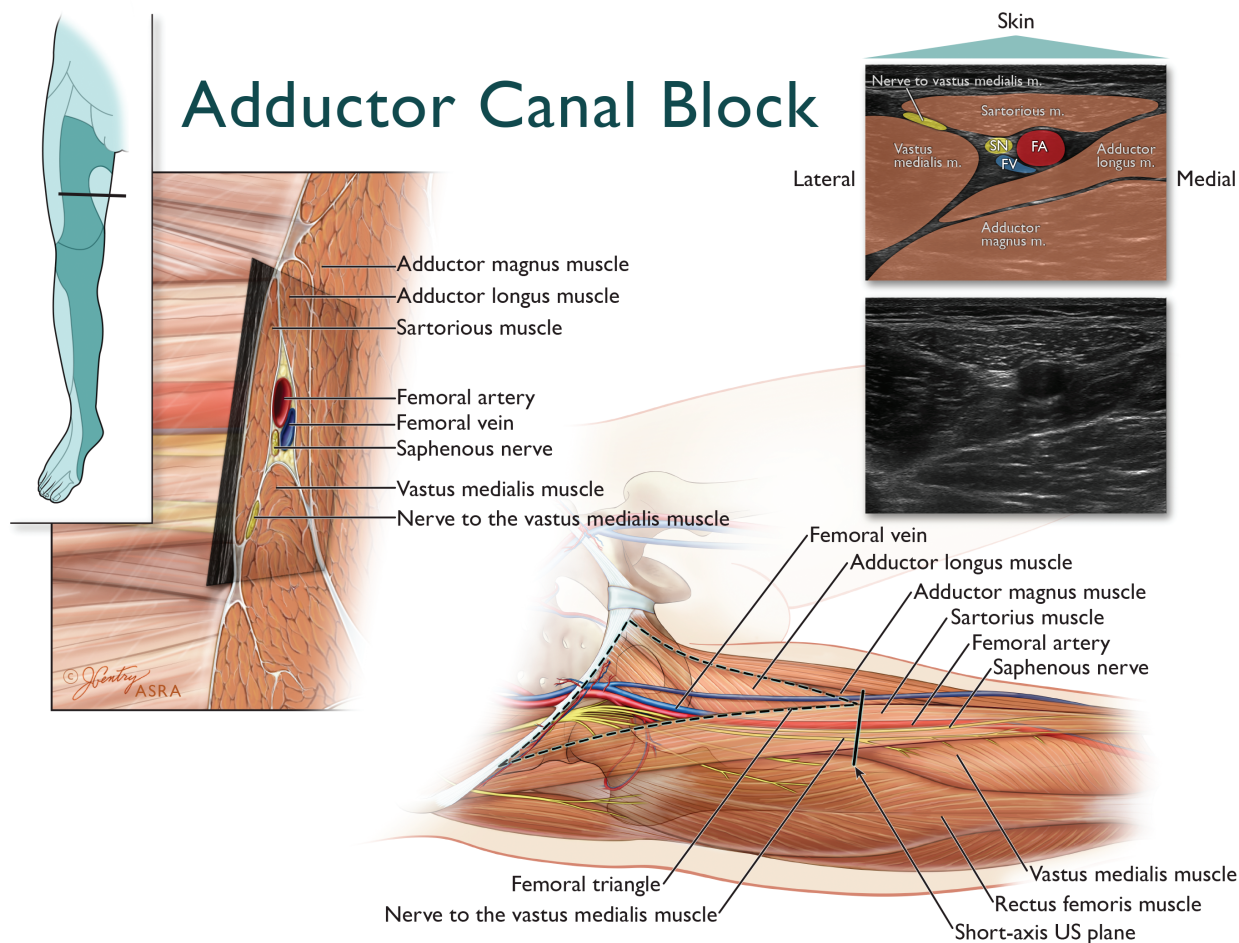
lateral to the femoral artery.<sup>16 17</sup> As the femoral nerve courses further caudad to the level of the inguinal crease, it adopts a position just lateral or posterolateral to the femoral artery.<sup>16 17</sup> Within the iliopectineal fossa, the femoral nerve can be found dorsal to both the fascia lata and fascia iliaca. In contrast, the femoral vessels (enveloped by the femoral sheath) are located dorsal to the fascia lata but ventral to the fascia iliaca. Thus, the fascia iliaca physically separates the femoral nerve from the femoral vessels.

The femoral nerve demonstrates a relatively flat cross-sectional diameter with a mean medial-to-lateral width of 9 to 11 mm and a mean anterior-to-posterior dimension of 1.3 to 2.3 mm.<sup>18</sup> The femoral nerve is composed of multiple “fascicular branches”:

1. Cutaneous branches to the anterior and medial thigh, peripatellar region, medial aspect of the lower leg and foot (figure 4).
2. Sensory and motor branches to the hip flexors, quadriceps and sartorius muscles (figure 5).

3. Articular branches to the hip, knee, and ankle joints, as well as contributions to the osseous innervation of the pelvis, femur, and tibia (figure 4).

Fascicular branches innervating the vastus medialis, vastus intermedius, and vastus lateralis are typically found in the central and dorsal portion of the femoral nerve. The fascicular branches innervating the rectus femoris (laterally located), pectineus (medially located), and the cutaneous nerves to the thigh can all be found on the peripheral aspects of the femoral nerve. The fascicular branch supplying the sartorius muscle is usually located on the ventral aspect of the femoral nerve, but can also be found in the lateral, medial, or central portion of the latter.<sup>18 19</sup> Anatomical and histological studies demonstrate that the femoral nerve arborizes into separate fascicular branches on average 3 cm distal to the inguinal ligament and consistently proximal to the inguinal (femoral) crease. At the level of the inguinal crease, the fascicular branches become separate nerves with an epineurial layer around each individual branch. The

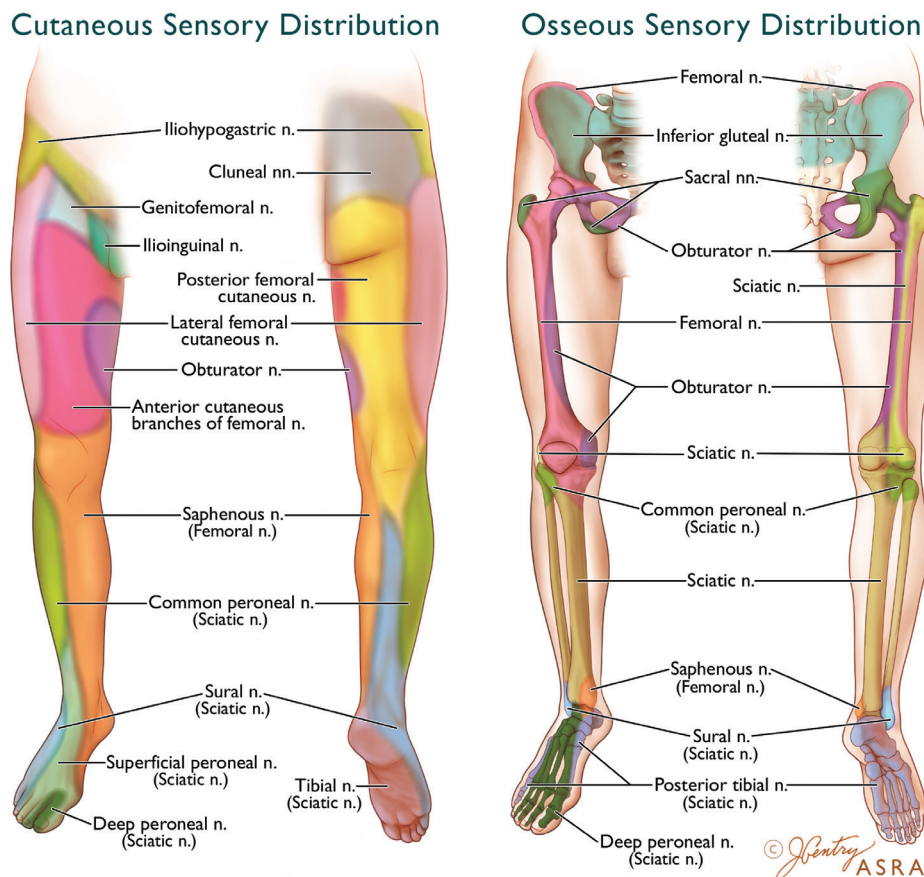


**Figure 3** Anatomy of the ultrasound-guided adductor canal block (ACB). Top left inset depicts the transducer location and expected cutaneous sensory distribution after ACB. The magnified axial view just distal to the apex of the femoral triangle illustrates that the adductor canal (AC) is a triangular myofascial structure defined by the sartorius muscle–vasoadductor membrane anteromedially, the vastus medialis muscle anterolaterally, and adductor muscles (adductor longus and magnus) posteromedially. The corresponding short-axis ultrasound image of the AC is obtained by placing the transducer just distal to the apex of the femoral triangle. The apex of the femoral triangle (where the medial border of the sartorius muscle crosses over the medial border of the adductor longus) seamlessly transitions into the proximal aspect of the AC, without a true anatomical boundary. The hyperechoic saphenous nerve (SN) is located lateral to the anechoic femoral artery (FA). The compressible femoral vein (FV) is often located just deep and lateral to the FA. The nerve to the vastus medialis is not located within the AC and travels in a separate myofascial tunnel contiguous but anterior to the AC. Illustration by Jennifer Gentry. Copyright Jennifer Gentry, American Society of Regional Anesthesia and Pain Medicine.

branches are tethered together by a common connective tissue sheath, with ample adipose and loose connective tissue between them. Thus, at the level of the inguinal crease, the femoral nerve has already divided into multiple individual branches, which travel in close approximation for some distance before physically separating and heading to their respective destinations.<sup>20</sup> Furthermore, at the apex of the iliopectineal fossa, the muscular branches to the rectus femoris, vastus intermedius, and vastus lateralis pierce through and become ventral to the fascia iliaca; they course for several centimeters through loose connective tissue before reaching their respective muscle. In a cadaveric study, US-guided dye injections at the apex of iliopectineal fossa (where the femoral artery has just passed beneath the medial border of the sartorius) consistently stained the nerve to the vastus medialis and the saphenous nerve, but spared the other muscular branches of the quadriceps muscles.<sup>21</sup>

Within the base of the iliopectineal fossa, the saphenous nerve is located medial to the nerve to the vastus medialis muscle.

Together, these two nerves continue distally toward the apex of the femoral triangle in conjunction with the femoral artery and femoral vein thereby forming a neurovascular bundle. In the distal part of the femoral triangle, the nerve to the vastus medialis lies between the sartorius and vastus medialis muscle (figure 3). The medial femoral cutaneous nerve travels along the posterior side of the sartorius muscle and communicates with the saphenous nerve and anterior branch of the obturator nerve thereby forming the subsartorial neural plexus ventral to the vasoadductor membrane.<sup>14</sup> These three nerves lie dorsal to the sartorius muscle and lateral to the femoral artery within the subsartorial apex (Scarpa) of the femoral triangle. The saphenous nerve and nerve to the vastus medialis exit the apex of the femoral triangle, but only the saphenous nerve enters the adductor canal in conjunction with the femoral artery and vein. It should be noted that the apex of the femoral triangle seamlessly transitions into the proximal aspect of the adductor canal, without a true anatomical boundary.<sup>14 21–24</sup>



**Figure 4** Cutaneous and osseous sensory distributions of the lower extremity. Terminal nerves of the lumbar and sacral plexus provide cutaneous sensory innervation to the lower extremity. The sensory distribution of these nerves is variable and overlapping (as depicted by the blended colors as the zones converge). Illustration by Jennifer Gentry. Copyright Jennifer Gentry, American Society of Regional Anesthesia and Pain Medicine.

The adductor canal is defined as the intermuscular compartment that begins proximally at the apex of the femoral triangle and ends distally at the adductor hiatus. The femoral artery exits the adductor canal by passing through the adductor hiatus on its way to the popliteal fossa where it becomes the popliteal artery. Within the adductor canal, the neurovascular bundle is located between the adductor muscles (longus and magnus) posteromedially, the vastus medialis muscle anterolaterally, and the vasoadductor membrane anteromedially (figure 3).<sup>14 22–24</sup> Inside the adductor canal, the saphenous nerve can be initially found lateral to the femoral artery. As it continues distally, the saphenous nerve assumes a position anterior and then medial to the femoral artery in the distal adductor canal. Although the anatomical data are conflicting,<sup>14 22–25</sup> the nerve to the vastus medialis deviates from the saphenous nerve just proximal to the adductor canal and travels in a separate myofascial tunnel contiguous but ventral to the adductor canal itself.<sup>14 22–24</sup> It gives rise to branches that supply the vastus medialis muscle as well as filaments that continue further distally to innervate the anterior and medial capsule of the knee joint and the medial retinaculum.<sup>14 24 25</sup> The saphenous nerve and the muscular branches from the nerve to the vastus medialis also give rise to branches that form a deep plexus lying between the femoral artery and the femur. In turn, this deep plexus gives rise to anterior and medial genicular nerves that supply the deep anteromedial aspect of the knee joint.<sup>14 24–27</sup>

At the distal end of the adductor canal, the saphenous nerve pierces the vasoadductor membrane and emerges subcutaneously between the sartorius and gracilis muscles, where it is

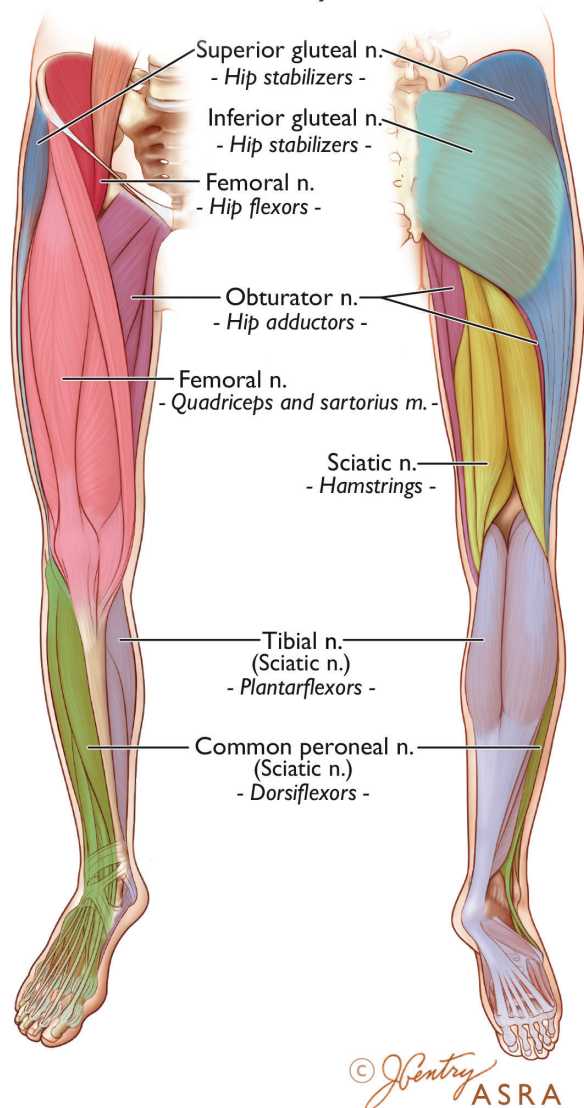
located dorsal to the distal aspect of the sartorius muscle.<sup>25–29</sup> As it courses further distally toward the joint line of the knee, the saphenous nerve further divides into infrapatellar and sartorial branches.<sup>30</sup> The infrapatellar branch provides cutaneous sensory innervation to the anterior aspect of the knee and gives rise to an articular branch that innervates the medial aspect of the knee joint (figure 4).<sup>14 25–27</sup>

The sartorial branch continues distally along the medial lower leg. Deep branches of the sartorial branch located 4–8 cm proximal to the medial malleolus provide significant innervation to the distal tibia and articular branches to the medial capsule of the ankle joint.<sup>31 32</sup> The sartorial branch continues further distally (passing anteromedial to the medial malleolus) to provide cutaneous innervation to the anteromedial lower leg as well as the medial aspect of the proximal and mid-portions of the foot (figure 4). Occasionally, it can contribute sensory innervation to the forefoot or articular innervation to first metatarsophalangeal joint.<sup>33–35</sup>

### Obturator nerve

The obturator nerve is formed within the substance of the psoas major from the anterior divisions of the ventral rami of the L2–L4 spinal nerves. Inside the psoas major, the obturator nerve is the most medially located branch of the lumbar plexus.<sup>2 6 8</sup> It emerges from the posterior border of the psoas major and descends along the lateral wall of the pelvis toward the superior part of the obturator foramen. The obturator nerve then enters the adductor compartment of the proximal thigh by passing

## Muscular Sensory Distribution



**Figure 5** Muscular sensory distribution. Terminal nerves of the lumbar and sacral plexus provide sensory innervation to the respective muscle groups of the lower extremity. Illustration by Jennifer Gentry. Copyright Jennifer Gentry, American Society of Regional Anesthesia and Pain Medicine.

through the obturator foramen.<sup>36 37</sup> After emerging from the latter, just caudad to the superior pubic ramus, the obturator nerve courses distally within an interfascial plane ventral to the obturator externus muscle and dorsal to the pectineus muscle. The obturator nerve and the accessory obturator nerve provide:

1. Variable cutaneous sensory innervation to the posteromedial distal thigh<sup>14 38</sup> (figure 4).
2. Sensory and muscular branches to adductor muscles of the thigh (figure 5).
3. Articular branches to the hip joint and posterior capsule of the knee joint.<sup>24-27 39</sup> as well as osseous innervation to the pelvis and femur (figure 4).

Anatomical studies have demonstrated a considerable degree of variability in the anatomy of the obturator nerve. It may divide into its respective anterior and posterior branches within the pelvis (23%) as it enters the obturator foramen, or within the obturator foramen itself (52%). It may also emerge from the

obturator canal as a singular structure and divide in the proximal medial thigh (25%).<sup>36</sup>

The anterior division initially courses in the interfascial plane between the pectineus and adductor brevis muscles, but further caudad, travels between the adductor longus and the adductor brevis muscles. The posterior division courses between the adductor brevis and adductor magnus. At the inferior border of the adductor longus within the apex of the femoral triangle, the distal continuation of the anterior division typically communicates with the medial cutaneous and saphenous branches of the femoral nerve to form a subsartorial plexus that supplies the skin on the medial side of the thigh.<sup>14</sup> Anatomical dissections have also described occasional communications between the anterior division of the obturator nerve and the articular branch of the saphenous nerve, which contribute to the perigenicular innervation of the medial aspect of the knee.<sup>26 27 39</sup>

The posterior branch of the obturator nerve descends between the adductor brevis and adductor magnus and enters the popliteal fossa (as the distal genicular branch) from the posterior surface of the adductor magnus muscle, the adductor hiatus, or through the distal 1 cm of the adductor canal. Within the popliteal fossa, the genicular branch anastomoses with branches of the tibial nerve to form the posterior popliteal plexus, which provides sensory innervation to the menisci, perimeniscal and posterior joint capsule, cruciate ligaments, as well as the infrapatellar fat pad.<sup>14 27 39</sup>

An accessory obturator nerve may be present in 10% to 30% of patients and originates from the ventral rami of the L3–L4 spinal nerves or directly from the obturator nerve itself.<sup>40 41</sup> The accessory obturator nerve courses along the posterior aspect of the external iliac artery and descends caudally over the superior pubic ramus giving off branches to the pectineus muscle and the hip joint. The presence of an accessory obturator nerve may carry clinical implications since the obturator and accessory obturator nerves are not adjacent to each other. Consequently, complete obturator nerve block (especially to the hip joint) may require blockade of the accessory obturator nerve as well. Fortunately, US-guided injection of 15 mL of methylene blue in the interfascial plane between the pectineus and obturator externus muscles effectively spreads to the superior ramus of the pubic bone, the obturator foramen, as well as the intrapelvic accessory obturator nerve when present (21% of cases).<sup>37</sup>

### Lateral femoral cutaneous nerve

The lateral femoral cutaneous nerve (LFCN) is a purely sensory nerve originating from the posterior divisions of the ventral rami of the L2–L3 spinal nerves. It emerges from the lateral border of the psoas major muscle and courses obliquely across the iliacus muscle (dorsal to the fascia iliaca) toward the anterior superior iliac spine (ASIS). The LFCN continues caudad dorsal to the inguinal ligament to enter the anterior and lateral compartments of the thigh, where it divides into multiple branches that supply a widely variable cutaneous distribution over the lateral, anterior, and medial thigh as far distal as the knee<sup>42</sup> (figure 4). The LFCN's course on entering the thigh, particularly in relation to the inguinal ligament and ASIS, also demonstrates considerable variability.<sup>43-46</sup> It is typically located 1.5 to 2.0 cm medial to the ASIS, although it may travel as far as 7 cm medial or even lateral to the ASIS. The LFCN usually enters the thigh as a single branch passing deep (dorsal) to the inguinal ligament in 70%–90% of cases. Less commonly, it may pass superficial (ventral) or directly through the inguinal ligament, and sometimes even through a bony canaliculus of the ASIS. As the LFCN penetrates the thigh,

it is most commonly located ventral to the sartorius muscle and dorsal to the fascia iliaca. It may also pass through the sartorius muscle, and rarely it may even travel ventral to the fascia lata.

### Sacral plexus anatomy

The sacral plexus originates within the pelvis from the lumbosacral trunk, the first to third sacral ventral rami, and part of the fourth sacral ventral ramus. The sacral ventral rami enter the pelvis through the anterior sacral foramina and converge to form a flattened band.<sup>2,47</sup> The sacral plexus is characterized by a triangular shape with its base along the sacral foramina and its vertex at the greater sciatic foramen. It lies ventral to the piriformis muscle and dorsal to the presacral fascia, which separates it from the intrapelvic viscera. The sacral plexus provides sensory and motor innervation to portions of the lower extremity including the hip, knee, and ankle joints. The most important branches for lower extremity surgery are the sciatic and posterior femoral cutaneous nerves as well as their respective terminal branches. In addition, the nerves to the quadratus femoris and inferior gemellus, the superior gluteal nerve, and a branch originating directly from the proximal sciatic nerve provide sensory innervation to posterior aspects of the hip joint.<sup>13 48</sup>

### Sciatic nerve

The sciatic nerve constitutes the primary terminal branch of the sacral plexus. It is derived from the lumbosacral trunk and ventral rami of the S1–S3 spinal nerves. It is the largest (measuring 10–20 mm in width at its proximal origin) and longest peripheral nerve in the body, extending from the inferior aspect of the piriformis muscle in the gluteal region to the apex of the popliteal fossa in the distal posterior thigh. The sciatic nerve trunk is composed of two major components: the tibial nerve (TN) and common peroneal nerve (CPN). These independent nerves do not mix fibers but share a common trajectory until they physically diverge from each other, typically within the popliteal fossa.<sup>49</sup> The lumbosacral trunk and the anterior divisions of the ventral rami give rise to the TN, whereas the posterior divisions give rise to the CPN. The TN is larger, located medial and slightly anterior in relation to the smaller CPN. A common extraneural connective sheath surrounds the TN and CPN to form the main sciatic nerve trunk. The fascicular components of the two nerves are separated by a septum (Compton-Cruveilhier septum) composed of connective and adipose tissue within the main sciatic nerve trunk.<sup>50 51</sup>

The sciatic nerve exits the pelvis via the greater sciatic foramen, descending caudally in the gluteal region on the ventral surface of the piriformis muscle. The sciatic nerve emerges from the caudal aspect of the piriformis and continues in a caudad direction along the dorsal surface of the external hip rotator muscles (superior gemellus, tendon of the obturator internus, inferior gemellus, and quadratus femoris from a cranial-to-caudal orientation).<sup>2</sup> At the caudal end of the quadratus femoris, the sciatic nerve enters the proximal posterior compartment of the thigh as it passes between the lateral border of the ischial tuberosity and the medial border of the posterior surface of the greater trochanter. Within the gluteal region, the gluteus maximus muscle covers the sciatic nerve, which can be found just lateral to both the posterior femoral cutaneous nerve and the inferior gluteal artery. Between the ischial tuberosity and the greater trochanter, the sciatic nerve is located in a well-defined intermuscular compartment (“*subgluteal compartment*”) dorsal to the quadratus femoris and ventral to the gluteus maximus.<sup>52–54</sup> As it emerges from the subgluteal compartment, the sciatic nerve lies on the posterior surface of the adductor magnus muscle and

is crossed obliquely by the tendon of the long head of the biceps femoris muscle.<sup>55 56</sup> Thus, the sciatic nerve is initially located just lateral to the tendinous origin (ischial tuberosity) of the long head of the biceps femoris before progressing distally deep to the belly of the latter toward the apex of the popliteal fossa.<sup>55–58</sup>

Within the gluteal region and the proximal-to-mid thigh, the most medial aspect of the sciatic nerve provides muscular branches to the semitendinosus, semimembranosus, long head and short head of the biceps femoris, as well as the ischial part of the adductor magnus (figure 5). Further caudad, the sciatic nerve provides articular branches to the knee joint.<sup>14 49 59</sup>

Within the mid-thigh (approximately halfway between the lateral aspect of the greater trochanter and the popliteal crease), the sciatic nerve is located posterior and medial to the shaft of the femur in a myofascial plane: it can be found dorsal to the adductor magnus and ventral to the belly of the long head of the biceps femoris.<sup>57 58 60</sup>

The distal sciatic nerve is located in the popliteal fossa. The latter is defined as the diamond-shaped intermuscular space posterior to the knee joint, bordered supero-laterally by the tendon of the long head of the biceps femoris, supero-medially by the tendons of the semimembranosus and overlying semitendinosus, infero-medially by the medial head of the gastrocnemius, and infero-laterally by the lateral head of the gastrocnemius.<sup>2</sup> Within the apex of the popliteal fossa, the sciatic nerve is bordered laterally by the long head of the biceps femoris muscle tendon and medially by the semimembranosus–semitendinosus tendons. In the upper part of the popliteal fossa, the sciatic nerve lies posterolateral to the popliteal vessels. The divergence of the sciatic nerve into the anatomically separate TN and CPN usually occurs in the cephalad aspect of the popliteal fossa, but it may also occur at any point between the sacral plexus and the popliteal skin crease.<sup>61 62</sup>

### Tibial nerve

The TN is the larger of the two terminal branches of the sciatic nerve. It continues further caudad within the center-midline of the popliteal fossa toward the popliteal skin crease and lies posterior and lateral to the popliteal vessels. Within the lower aspect of the popliteal fossa, it sends sensory and muscular branches to the major ankle flexors (the gastrocnemius and soleus muscles) (figure 5) as well as articular branches to the knee and ankle joint.<sup>59 63</sup> The TN then courses distally with the popliteal vessels deep to the tendinous arch of the soleus and runs along the dorsal surface of the tibialis posterior muscle. At the distal third of the lower leg, the TN emerges from beneath the soleus and courses along the medial aspect of the ankle midway between the dorsal aspect of the medial malleolus and the dorsal portion of the Achilles tendon. Proximal to the medial malleolus, the TN gives off its calcaneal branch, which supplies the heel of the foot.<sup>2 52</sup> At the level of the medial malleolus, the TN is only covered by superficial and deep fascia, and is typically found immediately dorsal to the posterior tibial artery. As the TN crosses over to the plantar aspect of the foot, it gives off the medial and lateral plantar nerves, which provide sensory and motor innervation to the foot and ankle. The medial plantar nerve supplies digital nerves to the medial 3 1/2 toes, whereas the lateral plantar nerve sends digital nerves to the lateral 1 1/2 toes.<sup>59 63</sup>

### Common peroneal nerve

The CPN is the lateral terminal branch of the sciatic nerve and travels obliquely along the lateral border of the popliteal fossa just medial to the tendon of the long head of the biceps femoris

muscle. Within the popliteal fossa, the CPN provides an articular branch to the lateral aspect of the knee joint. It exits the popliteal fossa by crossing over the lateral head of the gastrocnemius and can be found subcutaneously between the fibular head and the peroneus longus muscle. As it circumvents the neck of the fibula, the CPN divides into its two terminal branches: the superficial and deep peroneal nerve. The superficial peroneal nerve descends in the lateral compartment between the peroneus longus and extensor digitorum muscles to supply the ankle eversion muscles. In the lower third of the leg, it pierces the deep fascia and divides into several branches that provide cutaneous sensory innervation to the dorsal aspect of the ankle and foot. The deep peroneal nerve passes posterior to the extensor digitorum longus and anterior to the interosseous membrane, where it is joined by the anterior tibial artery. It then descends within the distal anterior compartment of the leg and emerges on the dorsum of the foot. The deep peroneal nerve and the contiguous dorsalis pedis artery are located lateral to the extensor hallucis longus tendon. At the level of the malleoli, the deep peroneal nerve can be found lateral to the artery.<sup>2 64</sup> Along its course, the deep peroneal nerve supplies the anterior muscle group of the lower leg and provides an articular branch to the ankle joint as well as a cutaneous branch to the first interdigital space.

### Sural nerve

The medial (MSCN) and lateral (LSCN) sural cutaneous nerves are purely sensory nerves derived from the TN and CPN, respectively, at the knee joint. In the majority (81%) of cases, the MSCN descends between the two heads of the gastrocnemius muscles where it receives the peroneal communicating branch (LSCN) to form the common sural nerve. Occasionally, the common sural nerve is derived solely from the TN (18% of cases) or the CPN (1% of cases).<sup>65</sup> The common sural nerve then continues caudad and courses between the dorsal aspect of the Achilles tendon and the dorsal aspect of the lateral malleolus in close proximity and lateral to the small saphenous vein, before terminating on the lateral side of the foot. The sural nerve provides cutaneous innervation to the posterolateral aspects of the lower leg and ankle as well as the dorsolateral aspect of the foot (figure 4).

### Posterior femoral cutaneous nerve

The posterior femoral cutaneous nerve is a purely sensory nerve derived from the ventral rami of the S1–S3 spinal nerves. It exits the pelvis through the greater sciatic foramen, initially medial and then dorsal to the sciatic nerve, while traveling ventral to the gluteus maximus alongside the inferior gluteal vessels. In the gluteal region, the posterior femoral cutaneous nerve is consistently located within the deep investing fascia of the gluteus maximus, while the sciatic nerve is located superficial to this fascial layer.<sup>64</sup> While ventral to the gluteus maximus, it gives cutaneous branches to the ipsilateral lower buttock and perineum.<sup>2</sup> Caudal to the ischium, the posterior femoral cutaneous nerve can be found lateral and superficial to the long head of the biceps femoris. At this level, it is located in subcutaneous tissues immediately ventral to the inferior margin of the gluteus maximus and fascia lata. In the proximal thigh, a deeper investing fascial layer connects the biceps femoris and vastus lateralis muscles. The sciatic nerve is located under this deeper investing fascial layer, while the posterior femoral cutaneous nerve is located superficial to the latter. Thus, the posterior femoral cutaneous nerve is located in a superficial fascial compartment that is separate from the sciatic nerve. The posterior femoral cutaneous nerve then continues down the posterior aspect of the thigh and leg, giving

off, in succession, femoral and sural branches, which provide cutaneous innervation to the back of the thigh, popliteal fossa, and calf<sup>2 65 67</sup> (figure 4).

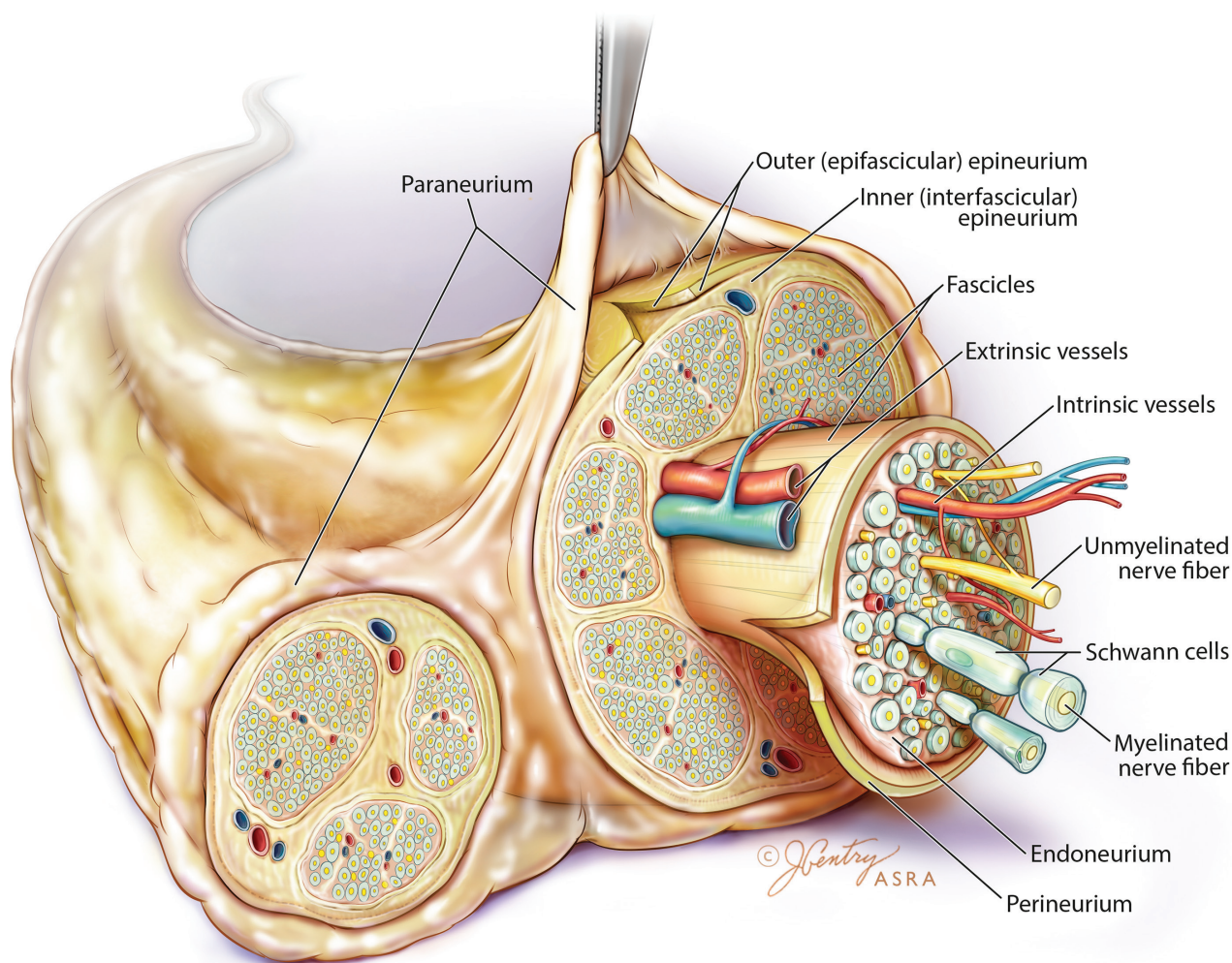
### Peripheral nerves: clinical and functional anatomy

A peripheral nerve consists of neural and non-neural components that together create a functional unit. The neural component is formed by axons, which are cytoplasmic neuronal extensions that conduct electrical signals originating from the cell bodies located inside the dorsal root ganglion (for general somatosensory function) or ventral horn of the spinal cord (for general somatic motor function).<sup>68</sup> From the inside outward, non-neural protective layers consist of endoneurium, perineurium, and epineurium (figure 6). Individual axons are surrounded by supporting connective tissue called the *endoneurium*, which consists of fibroblasts and their products (ie, collagen fibers and extracellular matrix). Groups of axons are bundled together into fascicles by the *perineurium*, which is composed of squamous cells that share tight junctions and are arranged in multiple concentric layers, interspersed by basal lamina. Each fascicle contains multiple axons and capillary blood vessels embedded within the loose connective tissue matrix of the adjacent endoneurium. The perineurium creates both a physical and chemical barrier, and functionally, serves as the “*blood–nerve barrier*.” The epineurium is the outermost connective tissue layer and encompasses two distinct anatomical components.<sup>69 70</sup> The inner (interfascicular) epineurium is composed of fibroadipose connective tissue that surrounds and fills the spaces between neural fascicles. The outer (epifascicular) epineurium encases the peripheral nerve and connects it to the adjacent extraneural tissues.

The extraneural connective (also known as paraneurium or paraneural sheath) suspends large peripheral nerves within a loose connective space that is directly connected to the epifascicular epineurium. In contrast, smaller nerves are surrounded by loose connective tissue originating from intramuscular compartments. The subparaneural space found around larger neural structures provides a path for longitudinal nerve motion, especially around joints thereby functioning as a “*gliding layer*” for the nerve and offering a layer of protection against neural trauma. In addition, the subparaneural compartment provides a plane of cleavage where the epifascicular epineurium and paraneurium come into contact.<sup>71 72</sup> This cleavage plane constitutes a virtual space that runs circumferentially and longitudinally along the course of a peripheral nerve, thus providing a conduit for local anesthetic spread.<sup>70–73</sup>

Peripheral nerves contain varying proportions of non-neural connective tissue. In general, the number of fascicles or fascicular bundles increases from proximal to distal, whereas the size of the fascicles decreases.<sup>49 74</sup> The relative and absolute amount of non-neural tissue also increases from proximal to distal. Thus, fascicles may constitute 25% to 75% of the cross-sectional surface area of a peripheral nerve with the relative amount of neural tissue decreasing from proximal to distal.<sup>59 74</sup> Along the path of a peripheral nerve, multiple intricate interconnections exist among fascicles. The latter may divide, regroup, interconnect, and reorganize to form intraneural plexuses.<sup>68 75</sup> The vascular supply of a peripheral nerve occurs mainly via longitudinally arranged blood vessels within the endoneurium and epineurium. The endoneural and epineural vessels have interconnecting bridges, and the epineural blood vessels can be directly modulated by the adrenergic system. The endothelial tight junctions of the endoneural capillaries serve as an additional blood–nerve barrier within peripheral nerves.<sup>68</sup>





**Figure 6** Peripheral nerve anatomy. Peripheral nerves consist of neural and non-neural connective tissue that together create a functional unit. Peripheral nerves are a collection of individual axons surrounded by supporting connective tissue called the endoneurium. Axons receive nutrition from intrinsic vessels. Extrinsic vessels are under adrenergic control and supply the intrinsic system. Groups of axons are bundled together into fascicles by the perineurium. The epineurium is the outermost connective tissue layer and encompasses both the interfascicular (which surrounds and fills the spaces between fascicles) and epifascicular (which encases the peripheral nerve and connects it to the adjacent extraneural connective tissue) layers. The extraneural connective tissue (paraneurium or paraneural sheath) suspends the peripheral nerve within loose connective tissue that is directly connected to the epineurium. Illustration by Jennifer Gentry. Copyright Jennifer Gentry, American Society of Regional Anesthesia and Pain Medicine.

## ESSENTIALS OF THE EVIDENCE PERTAINING TO APPROACHES AND TECHNIQUES

In recent years, the compendium of approaches and techniques for lower limb blocks has increased with the advent of US. In light of the large number of studies published in the English language, an evidenced-based discussion of lower extremity nerve blocks should focus on the best evidence available, ie, randomized controlled trials, published as of April 2018 (see online supplementary appendix 1/Supplemental Digital Content 1) for literature search strategy). Because randomized trials are primarily discussed, all technical recommendations contained in this review article are derived from Oxford Centre for Evidence-Based Medicine level 2 evidence (online supplementary appendix 2/Supplemental Digital Content 2).

For the purposes of this review, the term “*approach*” refers to the anatomical site where a plexus or peripheral nerve is targeted. The term “*technique*” refers to the modality (loss-of-resistance, paresthesia, neurostimulation, US) or endpoints (type

of evoked motor response with neurostimulation, single or multiple injections) needed to identify and anesthetize the nerve for a given approach. While some neural structures (eg, lumbar plexus, saphenous and sciatic nerves) can be blocked with different approaches as well as techniques, the majority of lower limb nerves are targeted using a single approach but multiple techniques.

## NERVE BLOCKS OF THE LUMBAR PLEXUS Approaches for lumbar plexus block

Lumbar plexus blocks are usually performed in the setting of hip arthroplasty<sup>10</sup> and hip fracture repair<sup>76–78</sup>. The lumbar plexus can be anesthetized with a posterior approach by depositing local anesthetic (LA) agents within the substance of the psoas muscle<sup>10 79–81</sup>. Alternatively, Winnie *et al*<sup>82</sup> suggested that an inguinal injection lateral to the femoral artery, coupled with cephalad angulation of the needle and distal manual compression,

would result in cephalad LA diffusion toward the lumbar plexus. Because the three main branches of the lumbar plexus (femoral, lateral femoral cutaneous, and obturator nerves) would be theoretically anesthetized with a single injection, this “anterior” approach to the lumbar plexus has also been called the “3-in-1 block.”

To date, six randomized controlled trials (RCTs) have compared single-injection 3-in-1 blocks and posterior lumbar plexus blocks.<sup>81 83–87</sup> Three RCTs reported a higher success rate with the posterior approach (83%–97% vs 16%–53%;  $p < 0.05$ ).<sup>83 85 86</sup> Although both methods reliably anesthetized the femoral nerve, obturator motor block was more commonly achieved with the posterior approach (63%–100% vs 0%–30%;  $p < 0.05$ ).<sup>81 83 86</sup> Two RCTs (combined  $n = 119$ ) have compared continuous 3-in-1 and lumbar plexus blocks for patients undergoing total knee replacement (TKR).<sup>88 89</sup> While one trial observed no differences in onset and sensory block of the obturator nerve,<sup>88</sup> the other study noted improved sensory obturator blockade at 24 hours with the posterior approach.<sup>89</sup>

The unreliable obturator block seen with the 3-in-1 block stems from the fact that, contrary to Winnie’s hypothesis,<sup>82</sup> LA anesthetizes the lateral femoral cutaneous and obturator nerves through lateral/medial spread, dorsal to the fascia iliaca and not via proximal diffusion.<sup>90</sup> Therefore, with the anterior approach, LA may distribute preferentially in a lateral direction, thus sparing the obturator nerve.<sup>85</sup> Some authors have even advocated renaming the anterior approach “2-in-1 block.”<sup>91</sup>

In summary, based on an analysis of the clinical evidence available, the posterior approach constitutes the only reliable method to anesthetize the lumbar plexus. The terms “anterior approach” and “3-in-1 block” should no longer be used.

### Techniques for (posterior) lumbar plexus block

While early descriptions of lumbar plexus blocks have advocated a loss-of-resistance (LOR) technique,<sup>76 80</sup> all subsequent studies have employed peripheral nerve stimulation (PNS).<sup>81 92 93</sup> In 2011, one trial comparing both modalities reported similar success rates but a shorter onset time with PNS.<sup>94</sup>

Four different sets of surface landmarks have been advocated for PNS-guided lumbar plexus blocks.<sup>10 79–81</sup> An RCT comparing Winnie’s and Chayen’s landmarks in children reported that, despite similar success rates (88%–92%), Chayen’s landmarks also resulted in a block of the contralateral lower limb in 88% of cases.<sup>92</sup> In contrast, in adults, all described landmarks for lumbar plexus block seem to provide similar success rates as well as comparable risks of neuraxial spread (4%–40%).<sup>81 93</sup>

In a 2008 trial, the relationship between injection pressure and epidural spread has been assessed.<sup>95</sup> Compared with a lower injection pressure ( $< 15$  psi), an injection pressure  $> 20$  psi should be avoided since it significantly increased the incidence of epidural blockade (0% vs 50%;  $p = 0.03$ ).

In recent years, US has been increasingly used as an adjunct for lumbar plexus block.<sup>96</sup> Because of its depth, the psoas muscle (and lumbar plexus) can be insonated with different US transducer orientations: parasagittal (ie, the “Trident” sign),<sup>96</sup> paramedian transverse through the lumbar intertransverse space,<sup>97</sup> and axial along the posterior axillary line (ie, the “Shamrock” sign)<sup>98</sup> (figure 7). In a small randomized, crossover trial ( $n = 20$ ), Strid *et al*<sup>99</sup> compared the “Trident” and “Shamrock” methods. These authors found that the latter resulted in a shorter performance time ( $238 \pm 74$  vs  $334 \pm 156$  s;  $p < 0.001$ ), fewer needle insertions, and less procedural pain. However, sensorimotor block was similar between the two groups. A recent RCT

( $n = 110$ ) compared combined US–PNS and US alone for lumbar plexus blocks. In the combined group, quadriceps-evoked motor response was sought at a current between 0.2 and 0.8 mA (pulse width = 0.1 ms) prior to LA injection. In the US alone group, LA was simply deposited inside the posteromedial quadrant of the psoas muscle. The authors found no intergroup differences in terms of performance time, block success, and postoperative opioid consumption. However, the combined US–PNS resulted in a 34% decrease in onset time compared to US alone.<sup>100</sup>

In summary, compared to LOR, PNS provides a shorter onset time for lumbar plexus blocks. In adult patients, all described landmarks for the PNS technique result in similar efficacy and adverse events (ie, epidural LA spread). For US-guided lumbar plexus block, compared to a parasagittal probe orientation, the “Shamrock” method results in a shorter performance time and fewer needle redirections. Compared to US alone, combined US–PNS provides a quicker onset for lumbar plexus blocks. However, the decreased onset time may provide minimal benefits if the block is performed mainly for postoperative analgesia and patients undergo concomitant general or neuraxial anesthesia.

### Techniques for femoral nerve block

Femoral nerve blocks are commonly used to provide pain control for TKR, anterior cruciate ligament (ACL) reconstruction, total hip arthroplasty as well as femoral fractures.<sup>87 101 102</sup>

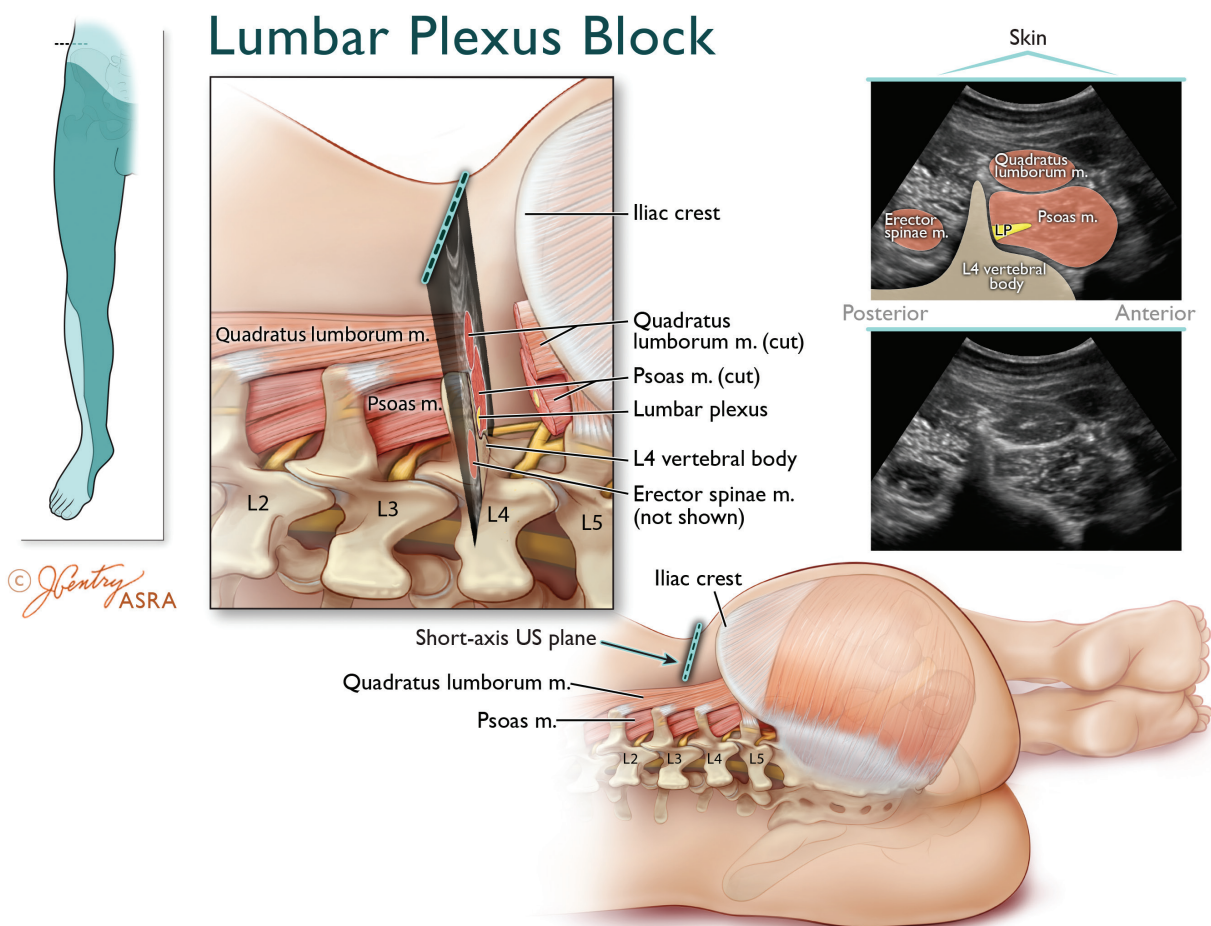
Two RCTs have been carried out to determine the best technique for PNS-guided femoral nerve block.<sup>103 104</sup> Compared to a single-injection technique, a three-injection method (with targeted stimulation of the motor branches to the vastus medialis, intermedius, and lateralis muscles) resulted in a decreased total anesthesia-related preoperative time (due to a quicker onset of surgical anesthesia)<sup>103</sup> as well as a lower minimum effective anesthetic volume of ropivacaine 0.5% for successful femoral blockade in 50% of subjects ( $MEV_{50}$ ) (14 vs 23 mL;  $p = 0.001$ ).<sup>104</sup>

During PNS-guided localization of the femoral nerve, two evoked motor responses (EMRs) are commonly encountered: sartorius muscle contraction (stimulation of the fascicular branch of the sartorius muscle) and quadriceps contraction, ie, “patellar ascension” sign (stimulation of the fascicular branches of the quadriceps muscle). Traditionally, only a quadriceps EMR was deemed acceptable. However, in 64 patients randomized to either sartorius or quadriceps EMR, no differences were noted between the proportions of subjects with complete and partial sensory block or complete motor block of the femoral nerve at 30 min.<sup>105</sup> These findings may be explained by the fact that the fascicular branches to the sartorius and quadriceps muscles lie in close proximity to each other dorsal to the fascia iliaca.<sup>105</sup>

To date, two clinical trials have compared US and PNS for femoral nerve block.<sup>106 107</sup> In a dose-finding study, the  $MEV_{50}$  of ropivacaine 0.5% was lower with US compared to PNS (15 vs 26 mL;  $p = 0.002$ ).<sup>106</sup> Another RCT, comparing US to combined US–PNS, found similar efficacy; however, the combination of modalities increased both performance time and number of needle passes.<sup>108</sup>

In three RCTs comparing PNS and US for “3-in-1 blocks,” US was found to provide significant benefits such as a quicker onset and/or a denser combined sensory block of the femoral, lateral femoral cutaneous and obturator nerves.<sup>87 109 110</sup>

In summary, compared to a single-EMR PNS technique, multiple EMRs shorten the onset time and decrease the LA requirement for femoral nerve block. Based on the limited evidence available, quadriceps and sartorius contraction constitute acceptable EMRs for single-injection femoral nerve block.



**Figure 7** Anatomy of the ultrasound-guided Shamrock lumbar plexus block (LPB). Top left inset depicts the transducer location and expected cutaneous sensory distribution after LPB. The magnified axial view illustrates that the lumbar plexus is located within posteromedial aspect of the psoas major muscle (PMM) just anterior to the transverse process (TP). The corresponding short-axis ultrasound view of the lumbar vertebral body, TP, PMM, erector spinae muscles (ESM), and quadratus lumborum muscle (QLM) and lumbar plexus is obtained by placing the transducer in an axial orientation just cranial to the iliac crest approximately along the posterior axillary line. The ultrasound image displays the characteristic view of the TP forming the stem of a Shamrock (three-leaf clover), with the PMM, QLM, and ESM representing the three leaves. The hyperechoic lumbar plexus is contained within the relatively hypoechoic PMM, typically within 2 cm anterior to the intensely hyperechoic TP. Since the segmental lumbar vertebral arteries lie lateral to the vertebral body and medial to the lumbar plexus, the needle tip should be positioned on the lateral side of the lumbar plexus. Illustration by Jennifer Gentry. Copyright Jennifer Gentry, American Society of Regional Anesthesia and Pain Medicine.

Ultrasound guidance provides a LA-sparing effect for femoral nerve block. However, if the femoral nerve can be well visualized, the combination of PNS and US confers no additional benefits when compared with US alone. The limited evidence available suggests that US provides a more reliable adjunct for “3-in-1 blocks” than PNS.

#### Techniques for fascia Iliaca block

In 1989, Dalens *et al*<sup>111</sup> introduced the fascia iliaca compartment block, an LOR method whereby LA is injected immediately dorsal to the fascia iliaca while firm compression is applied distal to the puncture site. In 120 children randomized to a PNS-guided “3-in-1” or a fascia iliaca compartment block, Dalens *et al*<sup>111</sup> reported similar rates of complete sensory block for the femoral nerve (100%); however, the fascia iliaca block resulted in improved sensory blockade of the LFCN (92% vs 15%;  $p < 0.05$ ). Subsequently, the same comparison was carried

out in 100 adults.<sup>112</sup> Again, despite a similar rate of femoral block (88%–90%), the LFCN was more frequently anesthetized in the fascia iliaca group (90% vs 62%;  $p < 0.05$ ). However, motor blockade of the obturator nerve showed no intergroup difference (20%–32%). Thus, compared to its “3-in-1” counterpart, the fascia iliaca block results in more frequent anesthesia of the LFCN. However, obturator block remains elusive in adults.

In 2008, a trial randomized 80 patients to a fascia iliaca block using LOR or US.<sup>113</sup> Although similar sensory blocks were observed in the anterior and lateral thighs, US yielded a better sensory block of the medial thigh as well as improved motor block of the obturator and femoral nerves. The authors speculated that subcutaneous fascias might in fact consist of several layers separated by adipose tissue: thus, blind puncture of any of these layers (with subsequent incorrect placement of LA) could have been mistaken for that of the fascia iliaca.

### Techniques for LFCN block

Block of the LFCN is commonly performed to anesthetize the skin of the lateral thigh. It can aid in the diagnosis and management of meralgia paresthetica.<sup>114</sup>

In a randomized crossover study, LFCN block was carried out using fan infiltration or a PNS-guided technique (seeking a paresthesia of the lateral thigh).<sup>115</sup> Nerve stimulation achieved a higher success rate, a quicker onset time as well as a decreased rate of incidental femoral nerve block (5% vs 35%;  $p=0.02$ ). The LFCN can also be anesthetized with US guidance.<sup>116</sup> A recent RCT comparing (sensory) neurostimulation and US reported no intergroup differences in terms of success rate, performance time, and onset. However, US guidance conferred a threefold decrease in the number of needle passes ( $p=0.009$ ).<sup>117</sup> Currently, there exist two techniques for US-guided LFCN block. One trial comparing US-guided targeted LFCN block and US-guided infiltration dorsal to the inguinal ligament found that the latter method resulted in a higher success rate (96% vs 75%;  $p=0.0027$ ).<sup>118</sup>

### Techniques for obturator nerve block

The obturator nerve provides sensory innervation to the medial aspect of the femur as well as articular innervation to the hip and knee. Obturator and femoral nerve blocks can be performed conjointly to provide analgesia for TKR.<sup>119</sup>

Neurostimulation-guided obturator block can be carried out proximally just caudad to the superior pubic ramus or more distally at the level of the inguinal crease. An RCT comparing these two methods found that, despite a similar efficacy, the distal approach resulted in a shorter performance time (80 vs 120 s;  $p<0.05$ ), decreased procedural discomfort, and fewer complications such as vascular puncture and groin pain.<sup>120</sup>

Several reports have advocated US for obturator nerve block.<sup>121 122</sup> However, to date, only one RCT ( $n=50$ ) has compared US and combined US–PNS.<sup>123</sup> In the US group, the authors injected LA between the adductor longus and brevis and the adductor brevis and magnus muscles. In contrast, in the US–NS group, EMRs of the adductor magnus (posterior division of the obturator nerve) and the adductor longus or brevis (anterior division of the obturator nerve) were sought. The combination of modalities provided no additional benefits in terms of efficacy (motor block at 15 min) or efficiency (onset/total anesthesia-related times, number of needle passes). Although preliminary studies suggest that obturator block can also be achieved by depositing LA between the pectineus and obturator externus muscles,<sup>37 124</sup> further trials are required to validate this technique.

### Approaches and techniques for saphenous nerve block

Saphenous nerve blocks are commonly performed to cover the medial leg in the setting of ankle and foot surgery.<sup>125</sup> Several approaches have been described to anesthetize the saphenous nerve: perifemoral injection, transsartorial injection, infiltration around the medial femoral condyle, infiltration around the medial tibial tuberosity, paravenous injection distal to the knee joint, and infiltration around the medial malleolus. Techniques include blind LA infiltration, LOR, (sensory) PNS, and US.

In the literature, seven RCTs have compared approaches and techniques for saphenous nerve block.<sup>125–131</sup> In terms of approaches, a small volunteer study ( $n=20$ ) compared blind LA injections around the saphenous vein and distal to the knee (between the tibial tuberosity and the medial head

of the gastrocnemius).<sup>125</sup> The paravenous approach yielded a higher success rate (100% vs 33.3%;  $p<0.05$ ). In 2009, Benzon *et al*<sup>128</sup> compared a PNS-guided perifemoral approach (4 cm distal to the inguinal crease) with a PNS-guided transsartorial approach (3–4 cm superior and 6–8 cm posterior to the supero-medial border of the patella) and three landmark-based field blocks: paracondylar, distal to the knee, and around the medial malleolus. These authors observed the following rates of sensory blockade: 100% for the transsartorial approach, 70% for the perifemoral approach, 10% for paracondylar injection, and 70% for infiltration distal to the knee. Unfortunately, the small number of subjects ( $n=10$ ) precluded definitive conclusions. However, two subsequent trials did report improved success rate with the transsartorial approach (with LOR or US) compared to blind LA infiltration distal to the knee (80%–100% vs 30%–40%;  $p<0.05$ ).<sup>126 129</sup> In recent years, the US transsartorial approach has also been compared to US-guided LA injection between the sartorius and vastus medialis muscles proximal to the knee joint with mixed results: one trial found no intergroup differences in terms of success rate<sup>129</sup> while the other RCT reported a higher success rate (100% vs 86%;  $p=0.003$ ) and shorter onset time (3 vs 9 min;  $p<0.001$ ) with the transsartorial approach.<sup>130</sup>

In an effort to refine the transsartorial technique, LOR, and (sensory) PNS were compared in a group of 25 volunteers.<sup>127</sup> Despite an improved success rate (100% vs 72%;  $p<0.05$ ), the PNS technique was associated with more procedural pain score and a longer performance time. In a recent RCT ( $n=80$ ), saphenous block 3 to 5 cm proximal to the patella was performed using US or combined US–(sensory) PNS. Adjunctive PNS did not improve block success but only served to lengthen the performance time ( $314\pm 125$  vs  $207\pm 76$  s;  $p<0.001$ ).<sup>131</sup>

In summary, based on the limited evidence available, the transsartorial approach constitutes the optimal approach for saphenous nerve block. Peripheral neurostimulation seems to confer minimal benefits when compared with US.

### Techniques for femoral triangle / adductor canal block

In recent years, LA injection next to the neurovascular bundle (around the femoral artery) at the level of the mid-thigh has received considerable interest. In addition to the saphenous nerve, LA injection in this location can also anesthetize the fascicular motor branch (of the femoral nerve) to the vastus medialis.<sup>14</sup> While most authors have initially termed this block “adductor canal block,” recent anatomical studies seem to suggest that “femoral triangle block” (FTB) might constitute a more accurate description. Irrespective of the correct denomination, recent RCTs have shown that FTB can decrease pain and/or opioid requirements and preserve quadriceps motor strength (compared to femoral blocks) after TKR.<sup>132–134</sup>

To date, two RCTs (combined  $n=122$ ) have investigated the optimal insertion site for FTB perineural catheters in the setting of TKR.<sup>135 136</sup> Both trials concluded that proximal insertion sites (ie, where the medial border of the sartorius muscle first covers the femoral artery or where the femoral artery travels dorsal to the medial third of the sartorius muscle) and distal insertion sites (ie, approximately halfway between the antero-superior iliac spine and the patella or where the femoral artery travels dorsal to the midpoint of the sartorius muscle) resulted in comparable postoperative opioid consumption, quadriceps strength, distance ambulated, and hospital length of stay.<sup>135 136</sup>

## Continuous block of nerves originating from the lumbar plexus

In their simplest permutation, perineural catheters are positioned by advancing the catheter blindly (usually 3–5 cm) past the needle tip (ie, blind catheters). Alternatively, placement of perineural catheters can be accomplished with PNS and preservation of the EMR via the catheter tip as the latter is advanced beyond the needle (ie, stimulating catheters). Increasingly, US is being used to verify the position of perineural catheters (ie, US catheters).

Although one recent trial has reported a 50%-decrease in the MEV<sub>50</sub> of mepivacaine 1.5% with stimulating compared with blind lumbar plexus catheters,<sup>137</sup> all RCTs comparing the different techniques for catheter insertion have focused exclusively on the femoral nerve.

### Techniques for blind femoral catheters

Prior to blind catheter advancement, the femoral nerve can be localized using PNS, US, or LOR (fascia iliaca compartment). Four RCTs have compared these modalities in patients undergoing ACL repair or TKR.<sup>138–141</sup> In two trials, PNS and LOR resulted in similar postoperative pain scores and opioid requirements.<sup>138 139</sup> However, LOR was associated with a faster performance time and a lower estimated material cost.<sup>138</sup> A third RCT compared PNS and US<sup>140</sup>. Although US resulted in a quicker performance time and less procedural discomfort, postoperative analgesia as well as ropivacaine and opioid requirements were similar between the two groups. In a fourth trial, US was compared to combined US–NS. Again, no differences were found in terms of analgesia and opioid consumption.<sup>141</sup> In summary, compared to PNS, LOR and US result in more expedient/less expensive needle placement prior to blind catheter advancement. However, postoperative analgesia is comparable with all three techniques since the catheters are advanced blindly.

### Blind versus stimulating femoral catheters

Seven RCTs have compared blind and stimulating femoral catheters in the context of healthy volunteers, TKR, or ACL repair.<sup>100 141–146</sup> In 20 volunteers, Salinas *et al*<sup>142</sup> placed bilateral femoral catheters while randomizing one side to a blind technique and the contralateral side to a stimulating technique. Despite similar success rates, these authors found that limbs anesthetized with stimulating catheters displayed a denser block as evidenced by higher tolerance to transcutaneous electrical stimulation and more pronounced quadriceps motor weakness, when quantitatively assessed with force dynamometry.

Unfortunately, Salinas *et al*'s results could not be reproduced outside of volunteers. Three RCTs (combined n=204) have compared stimulating and blind femoral catheters in the setting of TKR (n=183) and ACL repair (n=21).<sup>143–145</sup> All three trials reported no differences in terms of static/dynamic pain scores, narcotic/LA consumption, physiotherapy performance, and discharge time. In 70 patients undergoing ACL repair, Dauri *et al*<sup>101</sup> compared blind and stimulating femoral catheters. These authors found that stimulating catheters resulted in a quicker onset of sensory block for the femoral nerve as well as decreased consumption of breakthrough ropivacaine and ketorolac postoperatively. However, there were no intergroup differences in terms of static/dynamic pain scores and incidence of side effects. In two recent trials, 477 patients undergoing TKR were randomized to a stimulating or blind femoral catheter.<sup>141 146</sup> In the stimulating catheter group, the femoral nerve was initially localized with combined PNS–US; subsequently, the catheter was positioned

with PNS only. In the blind catheter group, the femoral nerve was localized with PNS–US or US alone; subsequently, the catheter was advanced blindly past the needle tip. Both studies found no intergroup differences in terms of postoperative pain scores, physiotherapy performance, and opioid consumption. However, the stimulating catheters resulted in decreased cumulative ropivacaine consumption at 48 hours ( $181.3 \pm 74.1$  vs  $228.5 \pm 49.8$  mL;  $p=0.03$ ).<sup>146</sup>

In summary, compared to their blind counterparts, stimulating femoral catheters result in decreased in LA consumption. However, they seem to provide minimal clinical benefits in terms of analgesia, physiotherapy performance time, opioid consumption, and discharge time.

### Blind versus US-guided femoral catheters

One RCT (n=92) compared blind and US-guided femoral catheters in the setting of TKR.<sup>147</sup> For the US group, the femoral nerve was located with combined PNS–US; subsequently, the catheter tip was visualized sonographically to ensure proximity to the femoral nerve. Compared to their blind counterparts, US-guided femoral catheters resulted in decreased LA requirement at 48 hours, static/dynamic pain scores at 12, 24, and 48 hours, and supplemental oral morphine consumption.

### Techniques for stimulating femoral catheters

In 120 patients undergoing TKR, PNS was compared to a combination of PNS and US for initial needle placement.<sup>148</sup> Subsequently, in both groups, a stimulating catheter was advanced 3 to 5 cm beyond the needle tip with preservation of the quadriceps EMR. The US–PNS group was associated with a decrease in performance time (9.0 vs 13.5 min;  $p=0.024$ ) and needle passes ( $p=0.007$ ) as well as a higher rate of complete femoral sensory block at 30 min (63% vs 38%;  $p=0.01$ ). Since all femoral catheters were placed with PNS, both groups displayed similar postoperative analgesia, knee flexion, and breakthrough opioid consumption.

### Stimulating versus US-guided femoral catheters

To date, two trials (combined n=88) have compared PNS and US for placement of the femoral catheter itself.<sup>149 150</sup> With PNS, the quadriceps EMR was obtained at a minimal stimulatory threshold of 0.5 mA (pulse width=0.1–0.2 ms). With US, a non-stimulating catheter was advanced under direct vision and its correct position (next to the nerve) inferred by the injection of 1 mL of air or normal saline. Both trials found no differences in postoperative pain scores. However, US resulted in a 24% to 41% decrease in performance time ( $p<0.03$ ). Furthermore, one trial also reported a decreased incidence of vascular puncture (0% vs 20%;  $p=0.039$ ) and less procedure-related pain with US.<sup>149</sup>

### Techniques for US-guided femoral catheter

In a total of 97 patients undergoing TKR, two RCTs have compared US-guided femoral catheters inserted parallel (long-axis in-plane technique (LAX-IP)) or perpendicular (short-axis in-plane technique (SAX-IP)) to the long axis of the femoral nerve.<sup>151 152</sup> In both groups, the desired position of the catheter tip (within 0.3 cm of the femoral nerve) was inferred by the injection of saline<sup>151</sup> or air.<sup>152</sup> Catheter placement required significantly less time (45% reduction) in the SAX-IP perpendicular group. There were no differences in the success rate of catheter placement, pain scores, opioid consumption, nausea/vomiting, maximal knee flexion, and length of stay. Thus, compared to

a SAX-IP technique, catheter insertion and advancement using a LAX-IP technique confers no clinical benefits. In 16 healthy volunteers, Ilfeld *et al*<sup>153</sup> placed bilateral US-guided femoral catheters using a SAX-IP technique. Through randomization, the catheter tip was positioned either ventral or dorsal to the femoral nerve on one side. On the contralateral side, the catheter tip was placed in the alternate position. At different time intervals until 22 hours after the start of the LA infusion, the authors assessed sensory and motor blockade using tolerance to transcutaneous electrical stimulation and maximum voluntary isometric quadriceps contraction, respectively. No differences in motor block were found between the two groups. However, at 1, 6, 7, 8, and 9 hours, catheters placed ventral to the nerve provided a denser sensory block.

### Summary of femoral perineural catheter techniques

For the placement of blind perineural catheters, the femoral nerve can be identified with PNS, US, or LOR (fascia iliaca compartment). Although LOR and US result in quicker needle placement, postoperative analgesia is comparable since the catheters are advanced blindly beyond the needle tip in all three cases. For the placement of stimulating perineural catheters, the femoral nerve can be identified with PNS alone or combined with US. The combination of modalities yields a shorter block performance time. However, postoperative analgesia is similar, as the catheters are inserted with PNS in both cases. In clinical practice (TKR or ACL repair), compared with their blind counterparts, stimulating femoral catheters seem to provide minimal clinical benefits. Similarly, US-guided and stimulating catheters result in comparable postoperative analgesia after TKR.

### NERVE BLOCKS OF THE SACRAL PLEXUS

Although the sacral plexus gives rise to multiple branches, only the sciatic nerve is commonly anesthetized for lower extremity surgery. Sciatic nerve blocks can be used as an adjunct to femoral block for TKR<sup>154</sup> and to provide anesthesia or analgesia for major ankle<sup>155</sup> and foot<sup>156 157</sup> surgery. Furthermore, the sciatic nerve, in conjunction with the superior gluteal nerve and the nerve to the quadratus femoris muscle, also provides innervation to the posterior aspect of the hip joint.<sup>13 48</sup>

### Approaches for sacral plexus and proximal sciatic nerve block

The proximal sciatic nerve can be anesthetized at the level of the sacral plexus (parasacral approach), proximal thigh (transgluteal, subgluteal, and anterior approaches) (figure 8), or mid-thigh (lateral approach). The parasacral approach targets the sacral plexus just caudal to the posterior inferior iliac spine, with a puncture site situated 6 cm inferior to the posterior superior iliac spine (PSIS) on an imaginary line joining the PSIS and the ischial tuberosity.<sup>158</sup> In 150 patients, one trial compared parasacral and transgluteal sciatic nerve blocks: although the parasacral approach resulted in a quicker performance time (2.0 vs 5.5 min;  $p < 0.001$ ), total anesthesia-related times and success rates were similar between the two groups.<sup>159</sup> Two RCTs (combined  $n = 178$ ) have compared the transgluteal and subgluteal approaches with similar conclusions: while no differences were noted in terms of success rate, onset and offset times, the subgluteal approach was associated with quicker sciatic nerve localization (32 vs 60 s;  $P < 0.001$ ) and less procedural pain.<sup>160 161</sup>

One RCT ( $n = 59$ ) compared the lateral mid-femoral and anterior approaches and reported similar performance times, success rates (77%–79%), onset times, and block durations.<sup>162</sup> In contrast, another trial, which compared the lateral, anterior,

and parasacral approaches, found that, despite similar onsets and durations, the anterior approach resulted in a denser block and improved patient satisfaction.<sup>163</sup> Finally, one RCT ( $n = 94$ ) compared the anterior and subgluteal approaches using combined PNS and US.<sup>164</sup> No differences were found in imaging, performance, onset/offset times, and success rate.

To date, only one trial has assessed proximal approaches in pediatric patients.<sup>165</sup> In 180 children undergoing lower extremity surgery, the anterior, posterior transgluteal, and lateral mid-femoral provided similar overall success rates (82%–97%). However, the transgluteal approach was associated with a higher success rate on the first attempt compared to its lateral and anterior counterparts (88% vs 78% and 62%, respectively; both  $p < 0.05$ ).<sup>165</sup>

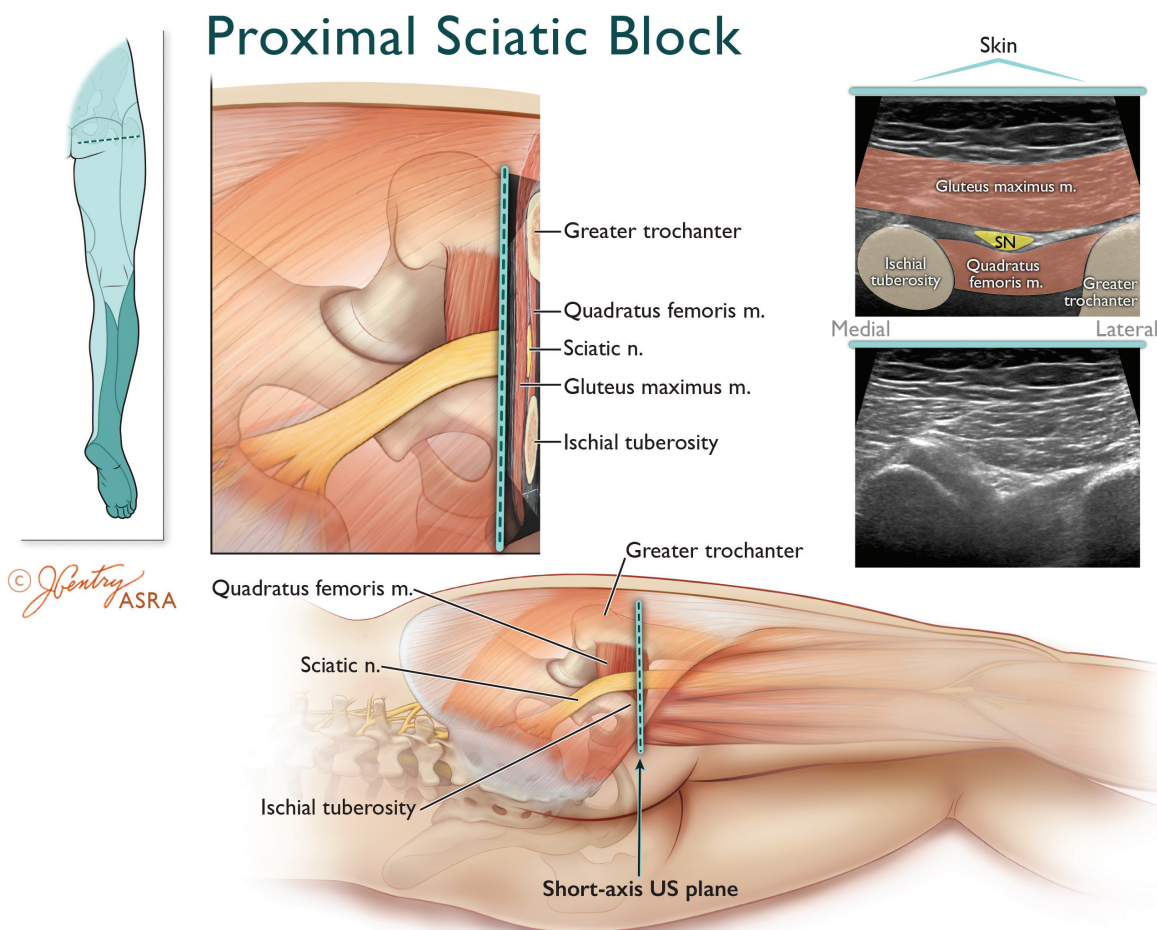
In summary, the current evidence suggests that all proximal approaches to the sciatic nerve result in similar success rates. In adults, the subgluteal approach should be preferred to the transgluteal method because of decreased performance time and procedural pain.

### Technique for parasacral and proximal sciatic nerve block

Neurostimulation-guided sciatic nerve block can target an EMR of either the TN or CPN. To date, two RCTs have compared the success rates of sciatic nerve block based on elicitation of plantar flexion (TN) or dorsiflexion (CPN) EMR with fairly consistent results (table 1).<sup>166 167</sup> For the parasacral and transgluteal approaches, compared to dorsiflexion, plantar flexion resulted in a higher success rate (78%–87.5% vs 16.7%–55.0%;  $p < 0.05$ )<sup>166 167</sup> as well as shorter onset times for complete sensory and motor block.<sup>167</sup> These findings could be explained by the fact that the larger TN requires more LA to be deposited in its vicinity. Although preliminary works suggest that inversion and plantar flexion constitute the optimal EMRs for the subgluteal approach (table 1),<sup>168 169</sup> these findings require further validation with RCTs.

In an effort to improve the success of proximal sciatic nerve blocks, some authors have proposed a double-injection technique, whereby the TN and CPN are independently localized and anesthetized.<sup>159 170 171</sup> For the transgluteal approach, two trials (combined  $n = 150$ ) have compared single-injection to double-injection techniques with similar findings.<sup>159 170</sup> A two-injection technique produced a higher success rate at 45 min (75%–100% vs 55%–80%;  $p < 0.05$ ). Furthermore, the longer performance time of the double-injection technique was offset by a decreased onset time.<sup>170</sup> For the subgluteal approach, one trial ( $n = 50$ ) compared one-injection and two-injection techniques: despite similar success rates (92%–96%), performance times and block durations, the double-injection technique also provided a faster onset of complete sensory and motor blockade.<sup>171</sup>

Because of its depth, the proximal sciatic nerve can be difficult to localize. In recent years, new landmarks have attempted to simplify PNS-guided subgluteal, anterior, and lateral mid-femoral approaches. For the subgluteal approach, a new needle insertion site (3 cm medial and 4 cm caudal to the ischial tuberosity),<sup>172</sup> based solely on the palpation of the ischial tuberosity (IT), was compared with the conventional one (4 cm caudal to the midpoint between the IT and greater trochanter). The new IT-based approach resulted in a higher rate of successful block placement (100% vs 42%;  $p < 0.001$ ), a shorter performance time, fewer needle passes, as well as a quicker onset of sensory and motor block.<sup>172</sup> The results of this trial confirm the fact that, rather than being equidistant between the greater trochanter (GT) and the IT, the sciatic nerve is closer to the latter. For



**Figure 8** Anatomy of the ultrasound-guided proximal sciatic nerve (SN) block. Top left inset depicts the transducer location and expected cutaneous sensory distribution after proximal SN block. Note that this approach does not provide cutaneous sensory anesthesia to the posterior thigh. The magnified axial view illustrates that the SN is located between the lateral border of the ischial tuberosity (IT) and the medial border of the greater trochanter (GT) within the intermuscular (“subgluteal”) space dorsal to the quadratus femoris (QFM) and the ventral to the gluteus maximus muscle (GMM). The corresponding short-axis ultrasound image of the SN and subgluteal space is obtained by placing the transducer in an axial orientation between the IT and GT. The SN nerve appears as a hyperechoic oval to lip-shaped polyfascicular structure sandwiched ventral to the epimysium of the GMM and dorsal to the epimysium of the QFM. Illustration by Jennifer Gentry. Copyright Jennifer Gentry, American Society of Regional Anesthesia and Pain Medicine.

Table 1 Evoked motor responses of the sciatic nerve		
EMR	Muscle responsible for EMR	Peripheral nerve mediating EMR
Plantar flexion*	Posterior compartment:	1. Tibial nerve
	▶ Primarily gastrocnemius and soleus ▶ Weakly by peroneus longus and peroneus brevis	2. Superficial peroneal nerve (CPN)
Dorsiflexion*	Anterior compartment:	Deep peroneal nerve (CPN)
	▶ Tibialis anterior ▶ Extensor digitorum longus ▶ Extensor hallucis longus	
Eversion†	Lateral compartment:	Superficial peroneal nerve (CPN)
	▶ Peroneus longus ▶ Peroneus brevis	
Inversion†	▶ Tibialis anterior	1. Deep peroneal nerve (CPN)
	▶ Tibialis posterior	2. Tibial nerve

\*Occurs at talocrural joint.

†Occurs at the subtalar joint.

CPN, common peroneal nerve; EMR, evoked motor response.

the anterior approach, one RCT (n=20) compared placing the patient’s leg in a neutral position or in external rotation.<sup>173</sup> The success rates, distances from skin to nerve, and number of attempts were similar between the two groups. Finally, one trial (n=50) assessed proximal (20 cm distal to the GT) and distal (30 cm distal to the GT) puncture sites for the lateral mid-femoral approach.<sup>174</sup> The proximal method resulted in a higher success rate (88% vs 56%; p<0.05) and a faster onset of complete sensorimotor block.

Two RCTs have compared US with PNS for proximal sciatic nerve blocks.<sup>175 176</sup> In 2009, 60 patients receiving a subgluteal block were randomized to PNS (TN EMR) or US.<sup>175</sup> Ultrasound guidance resulted in lower MEAV<sub>50</sub> (12 vs 19 mL; p<0.001) and MEAV<sub>95</sub> (14 vs 29 mL; p=0.008) for mepivacaine 1.5%. In the second RCT, PNS was compared to US-PNS for lateral mid-femoral sciatic blocks.<sup>176</sup> The combination of modalities resulted in fewer attempts (1 vs 2; p=0.001) and a denser sensory block. However, performance and onset/offset times were similar between the two groups.

Two RCTs have investigated the best technique for US-guided proximal (subgluteal) sciatic blocks.<sup>177,178</sup> In 86 patients, circumferential LA injection around the sciatic nerve was compared to a single injection dorsal to the nerve. Although the circumferential group required a longer performance time, it resulted in higher proportions of patients with complete sensory block at 30 min (41.9% vs 16.3%;  $p=0.018$ ). In the second trial ( $n=27$ ), in patients with body mass indices  $>25$  kg/m<sup>2</sup>, Abdallah *et al*<sup>178</sup> compared US-guided subgluteal sciatic nerve blocks (with perineural LA injection) to US-guided LA injection in the subgluteal space (ie, the intermuscular fascial plane between the gluteus maximus and quadratus femoris muscles). Despite similar success rates, these authors found that the subgluteal space technique resulted in a shorter performance time (4.4 vs 9.0 min;  $p<0.001$ ) as well as fewer needle passes and less procedural pain.

In summary, for PNS-guided proximal sciatic nerve block, electrostimulation of the TN should be preferred to that of the CPN. Furthermore, compared to its single-injection counterpart,

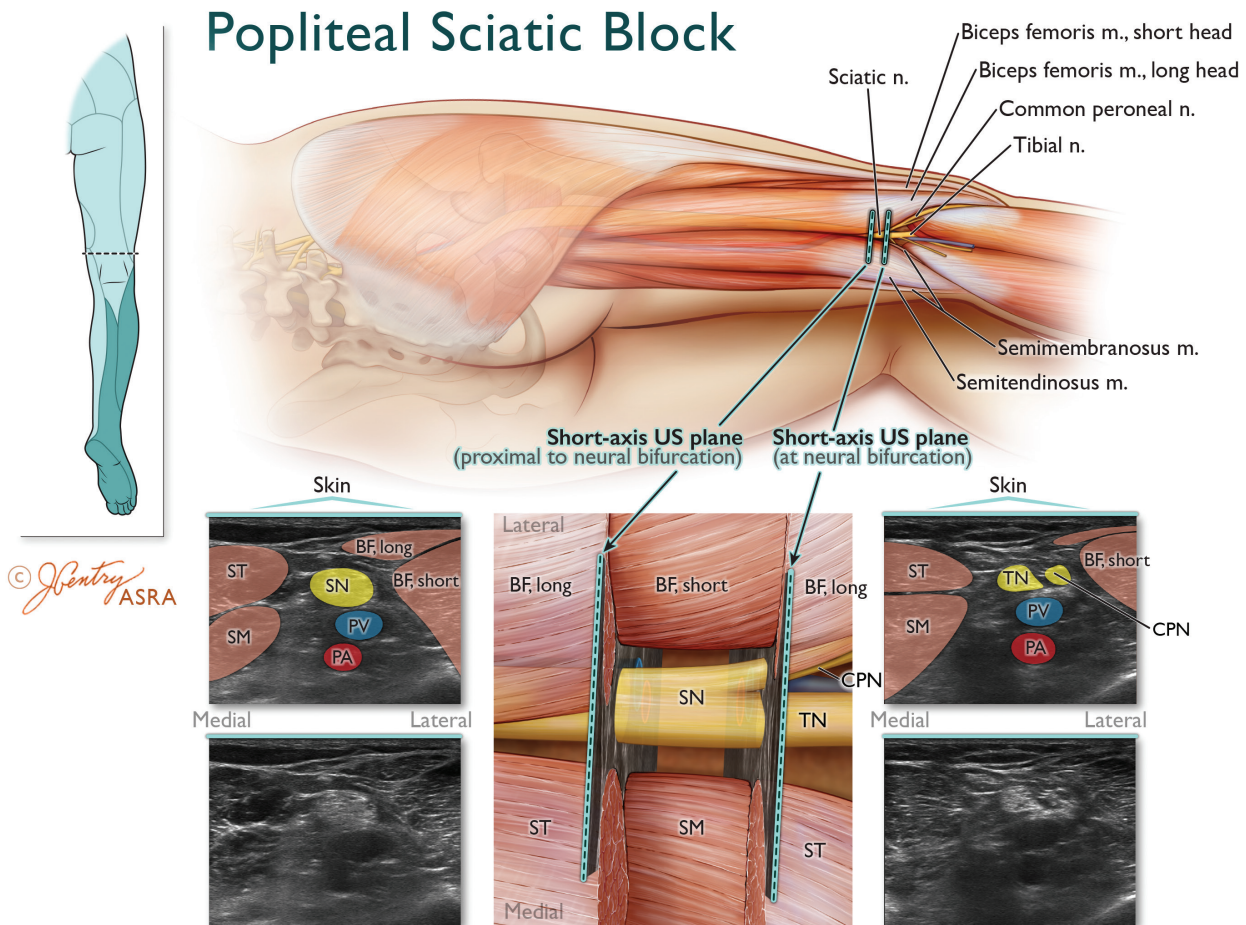
a double-injection (EMR) technique offers significant advantages such as improved success rate and onset time. Compared to PNS, US provides a LA-sparing effect. For US-guided proximal sciatic blocks, circumferential LA injection around the nerve should be preferentially sought. Further trials are required to investigate the subgluteal space technique in patients with normal body mass indices.

### Popliteal sciatic nerve block

The lateral and posterior popliteal approaches target the sciatic nerve in the distal thigh at the level of the popliteal fossa (figure 9).

### Proximal versus popliteal approaches

Two RCTs (combined  $n=158$ ) have compared the transgluteal and posterior popliteal approaches for sciatic nerve block and found no differences in onset, offset, and performance



**Figure 9** Anatomy of the ultrasound-guided popliteal sciatic nerve (SN) block. Top left inset depicts the two transducer locations and expected cutaneous sensory distribution after popliteal SN block. The magnified axial view illustrates that the SN is located within the apex of the popliteal fossa (bordered laterally by the long and short heads of the biceps femoris muscles and medially by the semimembranosus–semitendinosus muscles) and dorsal (superficial) to the popliteal vein (PV) and artery (PA). The corresponding short-axis ultrasound image of the SN is obtained by placing the transducer in an axial orientation over the apex of popliteal fossa. The SN appears as a round hyperechoic polyfascicular structure dorsal to the PV–PA. The corresponding short axis ultrasound image of the bifurcation of the SN is obtained by moving the transducer distally until the medially located TN and laterally located CPN physically separate from each other. There will be a relatively hypoechoic space located between the hyperechoic TN and CPN that consists of extraneural connective tissue (subparaneural space) located deep to the paraneurium (figure 6), but just superficial to the epineurium of the TN and CPN. Illustration by Jennifer Gentry. Copyright Jennifer Gentry, American Society of Regional Anesthesia and Pain Medicine.



times.<sup>179 180</sup> While one trial reported a higher success rate with the transgluteal approach (95% vs 45%;  $p < 0.01$ ),<sup>179</sup> the other found no difference between the two groups (94%–98%).<sup>180</sup> Two RCTs (combined  $n = 100$ ) have compared the transgluteal and lateral popliteal approaches: both studies found a longer onset for sensory and motor block with the latter.<sup>161 181</sup> One trial also reported a lower success rate with the lateral popliteal approach (68% vs 96%;  $p < 0.05$ ).<sup>181</sup>

One trial assessed the subgluteal and posterior popliteal approaches in terms of LA requirement for a complete sensory and motor block at 30 min with 30 mL of mepivacaine.<sup>182</sup> The subgluteal approach was associated with a significantly lower minimum effective anesthetic concentration to achieve a successful block in 50% of patients ( $MEAC_{50} = 0.95\% \pm 0.014\%$  vs  $1.53 \pm 0.453\%$ ;  $p = 0.026$ ). Using similar methodology, another RCT compared the subgluteal and posterior popliteal approaches in terms of LA requirement for a complete sensory and motor block at 20 min with mepivacaine 1.5%.<sup>183</sup> Again, the subgluteal approach was associated with significantly lower LA requirement ( $MEAV_{50} = 12 \pm 3$  mL vs  $20 \pm 3$  mL;  $p < 0.05$ ). The combined results of these two studies suggest that the subgluteal approach requires approximately 40% less LA than its popliteal counterpart.<sup>182 183</sup>

One RCT ( $n = 63$ ) comparing the lateral mid-femoral and lateral popliteal approaches reported no differences in performance time, procedural discomfort and quality as well as duration of sensory and motor blockade.<sup>184</sup> However, the lateral mid-femoral approach was associated with shorter onset times for sensory block of the TN and for motor block of the TN and CPN.

In summary, the available evidence suggests that, compared to their popliteal counterparts, proximal approaches to sciatic nerve block result in a decreased onset time and lower LA requirements.

### Posterior versus lateral popliteal approaches

The lateral and posterior popliteal approaches are similar in terms of PNS EMRs, LA volume, and pharmacodynamics; the main difference resides in the fact that the lateral approach involves needle puncture in the lateral instead of the posterior aspect of the distal thigh. To date, only one RCT ( $n = 50$ ) has compared both popliteal approaches.<sup>185</sup> Despite similar success rates (96%–100%), the posterior approach required fewer attempts to localize the sciatic nerve ( $p < 0.001$ ). Nonetheless, the lateral approach may still prove useful when patients cannot be placed in the prone (or lateral decubitus) position.

### Techniques for posterior popliteal sciatic nerve block

To date, two RCTs have investigated the optimal landmarks and techniques for PNS-guided posterior popliteal blocks.<sup>186 187</sup> One trial ( $n = 109$ ) compared a “modified intertendinous” technique (ie, needle insertion site in the intermuscular groove just distal to the overlap of the lateral and medial hamstring muscles) with a “classic” technique (ie, needle insertion site 1 cm lateral to the midline, 7–8 cm proximal to the popliteal crease).<sup>186</sup> No intergroup differences were found in performance times, number of attempts, and success rates (71%–82%). Another RCT ( $n = 60$ ), comparing single-injection and double-injection techniques, reported similar success rates (77%–87%), sensory onset times as well as total anesthesia-related times.<sup>187</sup> However, a decreased performance time ( $4.6 \pm 2.8$  vs  $5.9 \pm 3.1$  min;  $p = 0.03$ ) and incidence of paresthesia (17% vs 40%;  $p = 0.04$ ) were noted with a single-injection technique. Although observational studies have

suggested that foot inversion constitutes the optimal EMR for posterior popliteal sciatic blockade,<sup>62</sup> this finding has not been rigorously validated with RCTs (table 1).

Multiple RCTs have compared PNS and US for posterior popliteal blocks.<sup>188–193</sup> In 51 patients undergoing a double-injection technique, one study compared PNS to a combination of US and PNS.<sup>188</sup> Despite similar performance time, number of needle passes, and procedural pain, patients randomized to PNS–US displayed a higher incidence of complete sensory block (85% vs 32%;  $p < 0.001$ ), complete motor block (65% vs 16%;  $p < 0.001$ ), and success rate (65% vs 16%;  $p < 0.001$ ) at 30 min. In three trials, PNS was compared to US alone.<sup>189–191</sup> The first trial used a single-injection technique (accepting any EMR).<sup>189</sup> Ultrasonography resulted in a higher success rate (89% vs 61%;  $p = 0.005$ ) as well as a quicker onset of sensory and motor blockade. In contrast, the second study ( $n = 44$ ), which compared US with a two-stimulation/injection technique, observed no differences in the rate of complete sensory and motor blockade, surgical anesthesia (82%–100%), onset time, and patient satisfaction.<sup>190</sup> However, US guidance resulted in a shorter performance time (2 vs 5 min;  $p = 0.002$ ), less procedure-related pain (2 vs 4 on a 0–10 scale;  $p = 0.002$ ) as well as fewer needle passes (4 vs 6;  $p < 0.001$ ), paresthesias (0% vs 22%), and vascular punctures (0% vs 22%). In the most recent trial comparing PNS (TN EMR) to US (injection inside the paraneural sheath at the sciatic neural bifurcation), a higher percentage of successful sensory (80% vs 4%;  $p < 0.001$ ) and motor (60% vs 8%;  $p < 0.001$ ) block was observed at 15 min with US guidance.<sup>191</sup> In children, one trial compared PNS and US for a combination of sciatic (subgluteal or popliteal approach) and femoral blocks.<sup>192</sup> Ultrasonography resulted in longer postoperative analgesia ( $508 \pm 178$  vs  $335 \pm 169$  min;  $p < 0.001$ ) with levobupivacaine 0.5%. Finally, one trial compared PNS and US for posterior popliteal block performed in Sim’s position.<sup>193</sup> Despite comparable rates of surgical anesthesia (83%–100%), US guidance resulted in fewer needle passes and a reduction in the volume of lidocaine 1.5% with epinephrine 5  $\mu\text{g/mL}$  (17 vs 37 mL;  $p < 0.001$ ). Thus, the available evidence suggests that, compared to PNS, US results in higher rates of complete sensory and motor block, quicker performance, shorter onset, and lower LA requirements.

Since anesthesiologists are increasingly relying on US to perform peripheral nerve blocks, recent RCTs have focused exclusively on US guidance for popliteal sciatic blocks. One trial compared LA deposition ventral to the popliteal sciatic nerve and circumferential injection around the latter.<sup>194</sup> Despite similar performance times and procedural pain, success rate was expectedly higher with circumferential injection (94% vs 69%;  $p = 0.01$ ). Another study reported a quicker onset for sensory and motor block with separate injections around the TN and CPN compared with a pre-bifurcation injection around the common sciatic trunk.<sup>195</sup>

From its origin to its division TN and CPN, the sciatic nerve travels inside a common paraneural sheath.<sup>50 72</sup> Due to the increased resolution of US machines, LA injection inside this paraneural sheath is now possible. In 2011, Tran *et al*<sup>196</sup> compared a single LA injection inside the common paraneural sheath at the sciatic nerve bifurcation (ie, the subparaneural technique) with targeted supraparaneural injections around the TN and CPN. These authors observed that the subparaneural technique resulted in a higher success rate (84% vs 56%;  $p = 0.032$ ) as well as improved efficiency (decreased performance/onset/total anesthesia-related times and fewer needle passes). Tran *et al*’s initial findings were reproduced by Perlas *et al*.<sup>197</sup> Using a similar research hypothesis, LA mix, injectate volume, and

assessment scale for sensorimotor block, these authors found that, compared with separate injections around the TN and CPN, the subparaneural technique resulted in a higher incidence of complete block at 30 min (76% vs 49%;  $p=0.026$ ) as well as a 30% reduction in onset time for sensory and motor block. A third trial ( $n=48$ ) compared subparaneural to supraparaneural LA injection at the sciatic neural bifurcation.<sup>198</sup> Again, the subparaneural technique yielded a higher success rate (100% vs 73%;  $p=0.006$ ) and a 35% reduction in onset time. Tran *et al*<sup>199</sup> then set out to compare subparaneural LA injection at or proximal to the sciatic neural bifurcation: both techniques displayed similar success rates (85%–88%) and onset times. Subsequently, the same investigators compared single-subparaneural to triple-subparaneural injection techniques: again, no intergroup differences were found in terms of success rate (92%). Furthermore, the total anesthesia-related time (defined as the sum of performance and onset times) was also similar between the two groups.<sup>200</sup> Consequently, these authors concluded that, as long as LA is deposited inside the paraneural sheath, the actual level and number of injections carry minimal clinical relevance.

In recent years, Cappelleri *et al*<sup>201</sup> have proposed a deliberate intraneural injection technique of the TN and CPN in the popliteal fossa. These authors demonstrated that, compared to subparaneural injection, intraneural LA injection resulted in a higher success rate (95% vs 63%;  $p<0.001$ ) and a shorter onset time (10 vs 25 min;  $p<0.001$ ). Furthermore, no intergroup differences were found in electrophysiological evaluation at 5 weeks. However, Cappelleri *et al*'s results should be interpreted with caution, as 40% of subjects assigned to the intraneural injection group were lost to follow-up and did not undergo electrophysiological assessment as planned.

In summary, the (robust) available evidence suggests that, for posterior popliteal sciatic nerve block, US should be preferred to PNS in light of demonstrated efficacy and efficiency (ie, decreased onset, performance time, procedure-related discomfort, and number of needle passes). With US guidance, the subparaneural technique constitutes a simple alternative, which results in a high success rate coupled with a short onset time. Further trials are required to investigate the safety of intentional intraneural injection of the TN and CPN.

### Technique for lateral popliteal sciatic nerve block

Two RCTs have compared single-injection and double-injection PNS-guided lateral popliteal blocks with conflicting results.<sup>202 203</sup> In one trial ( $n=50$ ), a single-injection technique (using inversion as the preferred EMR) resulted in a lower success rate (54% vs 88%;  $p=0.007$ ) than targeted localization/injection of the TN and CPN.<sup>202</sup> In contrast, the other trial observed identical success rates (94%) with single (TN EMR)-injection and double-injection techniques.<sup>203</sup>

One RCT ( $n=24$ ) has compared PNS and US guidance for lateral popliteal sciatic nerve blocks in obese patients.<sup>204</sup> Despite similar sensorimotor block profiles between the two groups, the authors found that US resulted in decreased performance time ( $206\pm 40$  vs  $577\pm 57$  s;  $p<0.001$ ), number of needle redirections, procedural pain and increased patient satisfaction scores.

Two RCTs have investigated the optimal technique for US guidance (SAX-IP technique).<sup>205 206</sup> A combined total of 176 patients were randomized to separate injections of the TN or CPN or a single pre-bifurcation injection around the common sciatic trunk. In one trial, separate injections yielded a higher rate of surgical anesthesia (96% vs 51%;  $p<0.001$ )<sup>205</sup> while similar success rates (97%–100%) occurred in the other one.<sup>206</sup>

However, both studies found a shorter onset time for complete sensory blockade in the separate-injection group. In recent years, there has been considerable interest in LA injection inside the paraneural compartment of the sciatic nerve. Missair *et al*<sup>207</sup> compared the subparaneural technique to an US-guided supraparaneural LA injection for lateral popliteal sciatic nerve blocks. These authors reported a higher rate of complete sensory block at 30 min (90% vs 63%;  $p=0.03$ ) as well as a quicker onset and a 39%-longer block duration in the subparaneural group.

In summary, for lateral popliteal sciatic blocks, the current evidence suggests that, with either PNS or US guidance, separate injections around the TN and CPN provide a higher success rate or shorter onset time than a single LA injection around the common trunk. Expectedly, US provides superior efficiency to PNS in obese patients. As is the case with US-guided posterior popliteal sciatic blocks, the subparaneural technique results in an improved success rate and onset time compared to LA injection outside the paraneural sheath.

### Sciatic perineural catheters

Continuous sciatic perineural infusion may be used to extend the duration of postoperative analgesia for procedures such as lower limb amputations, ankle arthroplasty as well as repair of tibial, fibular, and calcaneal fractures.

### Blind subgluteal versus posterior popliteal catheters

In 60 patients undergoing elective foot surgery, one trial compared blind subgluteal and posterior popliteal catheters.<sup>208</sup> For both approaches, either plantar or dorsiflexion were accepted as EMRs via the stimulating needle. Subsequently, the operator advanced the catheter blindly 3 to 4 cm beyond the needle tip. The authors found no differences in terms of intraoperative fentanyl supplementation, postoperative pain scores, patient satisfaction, ropivacaine use, and breakthrough morphine consumption.

### Techniques for blind posterior popliteal catheters

Two recent RCTs have compared PNS and US for needle placement prior to blind catheter advancement (3–4 cm) of posterior popliteal catheters.<sup>209 210</sup> In the first trial ( $n=98$ ), in addition to fewer needle passes and improved patient satisfaction, US resulted in a higher rate of sensory block at 1, 6, 24, and 48 hours (94% vs 79%;  $p=0.03$ ) and decreased morphine consumption during the first 48 hours (18 vs 34 mg;  $p=0.02$ ).<sup>209</sup> However, no differences were noted in terms of pain scores, LA consumption, and postoperative nausea. Nonetheless, using a cost-effectiveness analysis, the authors estimated that there was an 85% likelihood that US is cheaper and more effective than PNS.<sup>211</sup> In the second trial ( $n=45$ ), no differences were found in terms of static or dynamic pain scores, breakthrough opioid consumption, side effects, and length of stay. However, during the study period (approximately 48 hours), the US group consumed less ropivacaine (cumulative total = 50 vs 197 mL;  $p<0.001$ ).<sup>210</sup> In an effort to define the optimal length for blind catheter insertion, Ilfeld *et al*<sup>212</sup> randomized 100 patients to a blind advancement of 0 to 1 or 5 to 6 cm beyond the needle tip. The authors found no intergroup differences in pain the day after surgery, breakthrough opioid consumption, catheter dislodgement/leakage, and incidence of insensate lower limb.<sup>212</sup>

### Blind versus stimulating posterior popliteal catheters

Four RCTs have compared stimulating and blind posterior popliteal sciatic catheters in the setting of hallux valgus surgery.<sup>213–216</sup>

In 98 subjects, one trial observed that stimulating catheters were associated with a shorter onset of sensory and motor blockade as well as decreases in ropivacaine consumption and rescue (tramadol) analgesia (25% vs 58% of patients;  $p=0.002$ ).<sup>213</sup> However, this did not translate into a difference in static and dynamic pain scores, patient satisfaction or side effects. The following year, the authors repeated the same protocol in another 76 patients with similar findings.<sup>214</sup> Again, during the study period (24 hours), stimulating catheters were associated with a decrease in ropivacaine (120 vs 153 mL;  $p=0.04$ ) and tramadol consumption but not in pain scores or side effects. However, the authors were able to calculate that the reduction in ropivacaine resulted in a decrease in LA-related costs (21 vs 42 euros;  $p<0.001$ ) if 100 mL bags of ropivacaine were used. The decreased cost was able to cover the additional expense of the stimulating catheter so that, in the end, there were no differences in analgesia-related expenditures between the two groups. When using 200 mL bags, the LA-sparing effect did not occur: thus, a 40% increase in analgesia-related costs was seen with stimulating catheters (€75 vs €55;  $p<0.001$ ). Another study randomized 48 patients to blind posterior popliteal sciatic catheters using levobupivacaine 0.125% infusion, stimulating catheters using levobupivacaine 0.0625% infusion and stimulating catheters using levobupivacaine 0.125% infusion.<sup>215</sup> The stimulating catheter/levobupivacaine 0.125% group consistently displayed lower pain scores at 6 to 8 hours (5 vs 60–70 on a 0–100 scale;  $p<0.05$ ) and required less rescue analgesia at 24 hours (0% vs 31%–44% of patients;  $p<0.05$ ). In 2009, a fourth RCT randomized 48 patients to either a blind or a stimulating posterior popliteal sciatic catheter.<sup>216</sup> Despite similar onset times for sensory and motor block, stimulating catheters resulted in lower median volumes of 1.5% mepivacaine to achieve surgical anesthesia in 50% of subjects (2.6 vs 16.6 mL;  $p<0.05$ ). In summary, the available evidence suggests that, compared to their blind counterparts, stimulating popliteal catheters provide similar pain control but result in decreased postoperative LA and opioid consumption. However, this sparing effect may not translate into a reduction in expenditures or adverse events.

### Subgluteal versus posterior popliteal stimulating sciatic catheters

In 56 patients undergoing hallux valgus repair, one RCT compared stimulating sciatic perineural catheters placed using a subgluteal or a posterior popliteal approach.<sup>217</sup> No differences in pain scores were observed during the study period (24 hours). However, subgluteal catheters were associated with fewer attempts for placement and decreased ropivacaine consumption ( $84\pm 22$  vs  $106\pm 30$  mL;  $p<0.05$ ).

### Stimulating versus US-guided popliteal sciatic catheters

In two RCTs (combined  $n=120$ ), Mariano *et al*<sup>218 219</sup> compared PNS and US guidance for posterior popliteal catheters in patients undergoing foot or ankle surgery. Both trials found a shorter performance time with US (5.0–7.0 vs 10.0–11.0 min;  $p<0.034$ ). However, findings pertaining to procedural pain and vascular puncture were mixed: one study found improvement with US guidance<sup>218</sup> while the other reported no differences between the two groups.<sup>219</sup> Interestingly, the trial powered to detect a difference in postoperative analgesia ( $n=80$ ) reported lower average pain scores at 24 hours with PNS (3.0 vs 5.0 on a 0–10 scale;  $p=0.032$ ).<sup>219</sup> Thus, the available evidence suggests that, compared to PNS, US guidance decreases the insertion time

of posterior popliteal catheters. However, pain control may be superior at 24 hours with PNS.

### Techniques for US-guided posterior popliteal catheters

In recent years, four RCTs have attempted to elucidate the optimal insertion technique for US-guided posterior popliteal catheters.<sup>220–223</sup> In 128 patients undergoing foot or ankle surgery, one RCT compared suprapaneural and subparaneural positions of the catheter tip at the neural bifurcation of the sciatic nerve. Patients assigned to the subparaneural group reported lower average and worst pain scores the morning after surgery. However, no inter-group differences were found in terms of opioid consumption.<sup>220</sup>

Suprapaneural popliteal catheters can be performed by insulating the sciatic nerve in long or short axis. In 46 patients undergoing foot or ankle surgery, one RCT ( $n=46$ ) compared both methods and found similar success rates (ie, complete sensory block at 30 min), onset times, numbers of needle passes, procedural pain, intraoperative/postoperative opioid consumption, and patient satisfaction. However, the long axis technique required a markedly longer performance time (9.5 vs 6.5 min;  $p<0.001$ ).<sup>221</sup>

Subparaneural popliteal catheters can be inserted using an IP or OOP needling technique (prior to catheter advancement). Hauritz *et al*<sup>222</sup> found that, compared to its out-of-plane (OOP) counterpart, the IP technique was associated with a fourfold increase in catheter dislodgement and 150% greater opioid (morphine) requirements. A recent trial ( $n=82$ ) compared positioning the catheter tip between the tibial and peroneal nerves or medial to the tibial nerve in the subparaneural space.<sup>223</sup> Catheter tip placement medial to the tibial nerve resulted in lower incidences of foot drop ( $p=0.012$ ) and insensate limb ( $p<0.001$ ) without impacting overall analgesia and LA consumption.<sup>223</sup>

### Summary of continuous sciatic perineural catheters

Continuous sciatic blocks can be performed with proximal (subgluteal) or distal (popliteal) approaches. The current evidence suggests that both methods provide comparable postoperative analgesia. However, LA consumption may be decreased with the subgluteal approach. For the placement of blind popliteal catheters, the sciatic nerve can be identified with PNS or US. Although the use of US requires fewer passes for needle placement, postoperative pain scores are comparable since the catheters are advanced blindly beyond the needle tip in both cases. For foot/ankle surgery, compared to their blind counterparts, stimulating popliteal catheters provide similar pain control but result in decreased postoperative LA and opioid consumption. Compared with PNS, US guidance requires a shorter performance time for the placement of posterior popliteal catheters. However, pain control may be superior at 24 hours with PNS. For US-guided popliteal catheters, an OOP needling technique should be used and the tip should be preferentially positioned inside the paraneural compartment, medial to the tibial nerve.

### Ankle block

Ankle block is commonly performed for midfoot and forefoot surgery.<sup>224</sup> In 71 patients, one trial compared the conventional infiltrative method (using 30 mL of ropivacaine 0.5%) with an US-guided technique.<sup>225</sup> Both methods provided similar success rates (80%–89%). However, during the first 24 hours, the proportion of patients requiring breakthrough opioids was lower with the conventional technique (20% vs 50%;  $p=0.01$ ).<sup>225</sup> An US-guided localization technique with concomitant PNS has been proposed for anesthesia of the deep peroneal nerve at the level of the distal malleolus.<sup>226</sup> However, in 18 volunteers randomized to a

**Table 2** Important technical areas pertaining to lower extremity nerve blocks warranting further investigation with randomized controlled trials

Posterior approach for lumbar plexus block	▶ Reliability of Dekrey's and Capdevila's landmarks for PNS guidance in pediatric patients
Femoral nerve block	▶ Comparison between single-injection and multiple-injection PNS techniques for local anesthetic volumes greater than 12 mL
Obturator nerve block	▶ Comparison between single LA injection between the pectineus and obturator externus muscles and separate LA injections between the adductor longus and brevis muscles and between the adductor brevis and magnus muscles
Sciatic nerve block	<ul style="list-style-type: none"> <li>▶ Comparison between the parasacral and the subgluteal/anterior/popliteal approaches to the sciatic nerve</li> <li>▶ Comparison between the transgluteal and the anterior/lateral mid-femoral approaches to the sciatic nerve</li> <li>▶ Comparison between the subgluteal and the lateral mid-femoral/lateral popliteal approaches to the sciatic nerve</li> <li>▶ Comparison between the anterior and the lateral popliteal/posterior popliteal approaches to the sciatic nerve</li> <li>▶ Comparison between approaches (other than transgluteal, lateral mid-femoral, and anterior) for pediatric patients</li> <li>▶ Optimal evoked motor response for methods other than the parasacral, transgluteal, and lateral popliteal approaches</li> <li>▶ Comparison of US and PNS for methods other than the subgluteal, lateral mid-femoral, and posterior popliteal approaches</li> <li>▶ Comparison of US and PNS for continuous sciatic catheters using methods other than the posterior popliteal approach</li> <li>▶ Further studies to validate the safety of intentional intraneural injection of the tibial and common peroneal nerves</li> </ul>

LA, local anesthetic; PNS, peripheral nerve stimulation; US, ultrasound.

landmark-based technique on one side and US on the other, no differences in sensory and motor block were noted between 20 and 60 min.<sup>227</sup> In contrast, two other volunteer studies reported a higher success rate of tibial and sural blockade with US guidance.<sup>228 229</sup> Thus, although US seems to provide minimal benefits for ankle blocks, it may improve the block success of individual nerves such as the tibial and sural nerves.

### GAPS IN TECHNICAL KNOWLEDGE

A critical survey of available RCTs can provide an effective tool to determine the most effective approaches and techniques for lower limb anesthesia. Despite current best evidence, many important technical issues regarding lower extremity nerve blocks remain unresolved and require further elucidation through well-designed and meticulously conducted RCTs. The authors' opinion related to technical questions warranting further investigation is presented in [table 2](#).

### LOCAL ANESTHETICS AND ADJUVANTS

Desirable LA properties for lower extremity nerve blocks may differ from those pertaining to brachial plexus blockade. For instance, upper limb surgery is often carried out under regional anesthesia. In contrast, surgical anesthesia for lower extremity surgery is most often accomplished using neuraxial or general anesthetic techniques, and lower extremity nerve blocks are used most often to extend postoperative analgesia rather than as the primary anesthetic. This carries implications for LA and adjuvant selection in that rapid block onset becomes less important while analgesic duration assumes a higher priority.

#### Local anesthetic selection

When single injection anesthesia is used, LA choice is dictated primarily by the desired block duration ([box 1](#)). 2-Chloroprocaine 3% is effective when rapid block onset and resolution are required for ambulatory surgery.<sup>230</sup> Longer duration lower extremity analgesia follows the pattern bupivacaine>ropivacaine>mepivacaine.<sup>231 232</sup> Thus, single-injection bupivacaine (0.25% to 0.5%) or ropivacaine (0.5%–0.75%) blocks are indicated for prolonged surgical anesthesia/analgesia, while intermediate-acting lidocaine and mepivacaine (1%–1.5%) are appropriate for 1-hour to 3-hour surgeries of mild-to-moderate discomfort, or to serve as the primary block when postoperative continuous infusion is planned. Liposomal bupivacaine, used off-label in a single volunteer crossover

study of femoral nerve block, resulted in partial sensory and motor block for over 24 hours, but with high inter-subject variability of block magnitude. Moreover, an inverse relationship was seen between the dose of liposomal bupivacaine and the magnitude of the block.<sup>233</sup>

#### Local anesthetic mixing

The practice of mixing LAs to achieve faster block onset combined with prolonged duration has not been extensively investigated in the setting of lower extremity blockade. In a study of femoral–sciatic nerve block, mixing bupivacaine 0.5% or ropivacaine 0.7% with lidocaine 2% resulted in modestly faster block onset (7 to 12 min), but shorter block duration, as compared with using either long-acting LA alone. Furthermore, there were no inter-group differences in terms of pain scores and morphine use.<sup>234</sup> A faster block onset coupled with a shorter duration could be considered inconsequential and detrimental, respectively, if the block is intended solely for analgesia.

#### Local anesthetic mass, concentration, and volume

The amount of LA used for nerve blocks is often greater than the dose required for adequate blockade. Intuitively, increasing LA concentration, volume, and/or mass should result in improved block characteristics (ie, quicker, denser, and longer-acting block). With rare exceptions, this has not proven true and may in fact increase the risk of local anesthetic systemic toxicity (LAST, from higher-than-necessary LA doses) or neurotoxicity (should the nerve's protective perineurium be breached and the fascicles become exposed to higher LA concentrations). Dosing based on patient weight is fallacious because nerve size is independent of a patient's morphometric parameters. Over-reliance on weight-based dosing can be particularly dangerous in children, whose smaller size places them at risk for LAST.<sup>235</sup> For example, several children (36±10 kg) given 3.5 mg/kg of ropivacaine for fascia iliaca block attained high plasma concentrations that exceeded the recommended range.<sup>236</sup> Experimentally, nerve cross-sectional area can predict LA dosing. For instance, complete sensory and motor blockade of the common sciatic nerve was achieved using only 0.15 mL/mm<sup>2</sup> of ropivacaine 0.75%.<sup>237</sup>

#### Local anesthetic concentration

For surgical anesthesia, higher LA concentrations are often necessary; here, the comparative potency of LAs takes on importance.

## Box 1 Evidence-based recommendations for local anesthetic and adjuvant selection for lower extremity peripheral nerve blocks

### Local anesthetics

#### Local anesthetic selection

- ▶ 2-Chloroprocaine 3% is useful when rapid block onset and resolution are desired (2).
- ▶ Lidocaine or mepivacaine 1% to 1.5% are indicated for surgical anesthesia of 1–3 hours' duration or as primary block when a continuous postoperative technique is used (2).
- ▶ For surgical anesthesia, equipotent bupivacaine 0.5% or ropivacaine 0.75% are indicated. For analgesia, bupivacaine 0.25% or ropivacaine 0.5% are adequate (2).
- ▶ Liposomal bupivacaine is off-label and limited study is inadequate for recommendations at this time (4).
- ▶ Local anesthetic mixing modestly reduces block onset time, but at the expense of block duration (2).

#### Local anesthetic dose, concentration, and volume

- ▶ Dose, volume, and concentration of local anesthetics for lower extremity blockade tend toward higher-than-necessary parameters, especially when ultrasound guidance is used (2).
- ▶ Patient weight-based dosing is fallacious and may be dangerous in children or adults with low muscle mass (3).
- ▶ For continuous perineural techniques, drug mass appears to be more important than concentration or volume. Lower local anesthetic concentration may not result in less motor block (2).

### Adjuvants

#### Epinephrine

- ▶ Prolongs intermediate-acting local anesthetic agents (~50%) to a greater extent than long-acting agents (<20%).
- ▶ Possesses the unique advantage of a marker of intravascular injection (2).

#### Clonidine

- ▶ Prolongs intermediate-acting local anesthetic agents to a greater extent than long-acting agents (20% to 30%).
- ▶ Does not improve continuous infusion techniques (2).

#### Buprenorphine

- ▶ Mild to modest prolongation of blockade with increase in nausea and vomiting (2).

#### Dexamethasone

- ▶ 8 mg and higher perineural doses prolong analgesia modestly, but are not different than equivalent intravenous doses (1).
- ▶ 4 mg or less is recommended for perineural dosing (4, 5).

#### Dexmedetomidine

- ▶ Most effective adjuvant for prolonging long-acting local anesthetic blocks (1).

Recommendations based on Oxford Centre for Evidence-Based Medicine 2011 Levels of Evidence (available at: <http://www.cebm.net/index.aspx?o=565> (Level 1 = systematic review of randomized trials or n-of-1 trials; Level 2 = randomized trial or observational study with dramatic effect; Level 3 = non-randomized controlled cohort/follow-up study; Level 4 = case-series or case-control studies, or historically controlled studies; Level 5 = mechanism-based reasoning).

For large nerves, such as the proximal sciatic nerve, ropivacaine 0.75% is equipotent to bupivacaine 0.5% in terms of surgical anesthesia.<sup>238</sup> While l-bupivacaine and ropivacaine share characteristics more similar to each other than to racemic bupivacaine, the former

is more potent and consistently results in longer duration blocks than ropivacaine.<sup>239–241</sup>

Successful neural blockade is attainable despite low LA concentration. Using US guidance for femoral nerve blockade, ropivacaine in concentrations as low as 0.167% weight/volume (95% CI 0.14 to 0.184) resulted in surgical anesthesia.<sup>242</sup> Lower concentrations are particularly adequate for analgesia: bupivacaine 0.25% or ropivacaine 0.2% resulted in 24-hour pain scores after ACL repair that were no different from those obtained using ropivacaine 0.75%.<sup>243</sup> For US-guided transluteal sciatic nerve blocks, mepivacaine 1% rendered block onset and duration equivalent to mepivacaine 2%.<sup>244</sup> Conversely, when PNS was used to localize the sciatic nerve for the same approach, mepivacaine 1.5% resulted in faster block onset and higher success as compared with mepivacaine 1% in equal drug mass. This difference may be due to the block needle being farther away from the nerve using PNS compared with US.<sup>245</sup>

### Local anesthetic volume

There exists little evidence to suggest that LA volumes in excess of 20 mL (administered via a perineural catheter) result in longer block duration.<sup>246 247</sup> Nevertheless, LA volume does vary among block approaches. For instance, the MEV<sub>50</sub> of mepivacaine 1.5% is nearly 50% less for a subgluteal sciatic nerve block than for its popliteal counterpart.<sup>183</sup> The MEV<sub>50</sub> for US-guided subparaneural popliteal sciatic nerve block was determined to be only 6.1 mL (95% CI 4.3 to 7.9) for ropivacaine 0.75%, but 40 min was required to achieve full sensorimotor blockade.<sup>248</sup> Compared to PNS, US guidance decreases the MEV<sub>50</sub> by ~40% for subgluteal sciatic,<sup>175</sup> ankle,<sup>225</sup> and femoral<sup>106</sup> nerve blocks.

### Continuous perineural techniques

The role of volume, concentration, and dose is not well studied for lower extremity continuous perineural blocks. Using a continuous popliteal sciatic nerve block model, Ilfeld *et al*<sup>249</sup> reported that analgesia and patient satisfaction did not differ when ropivacaine was administered at 16 mg/h in either a 0.2% or 0.4% concentration. However, the more concentrated/lower basal rate infusion (0.4% at 4 mL/h) resulted in fewer insensate limbs (a desirable outcome). Conversely, neither concentration nor volume of ropivacaine affected continuous lumbar plexus block characteristics, which led the authors to conclude that LA mass constitutes the most important factor for lumbar plexus blocks. In this study, lower ropivacaine concentration (0.2%) did not impart the advantage of decreased motor blockade.<sup>250</sup>

### ADJUVANT SELECTION

When continuous perineural techniques are not feasible, prolongation of analgesia beyond the expected duration of plain LA is accomplished through the use of adjuvant drugs (box 1). Classic adjuvants such as epinephrine and clonidine prolong intermediate-acting LA duration by approximately 50%, but have much less effect on long-acting LAs, in which only dexmedetomidine and perhaps dexamethasone exert an impactful effect. Pure opioid agonists and other adjuvants<sup>251</sup> such as magnesium,<sup>252</sup> tramadol, or midazolam<sup>253</sup> have no significant effect on LA duration and/or display neurotoxicity concerns. The addition of sodium bicarbonate to bupivacaine for combined lumbar plexus and sciatic nerve block does not result in faster block onset.<sup>254</sup> Alkalinization of intermediate-acting LAs has not been studied specifically for lower extremity block, but the evidence from upper extremity studies suggests that it does not result in a significantly faster onset of anesthesia.<sup>251</sup>

With the exception of epinephrine, all adjuvants discussed hereafter should be considered “off-label” with regard to their perineural use as per the US Food and Drug Administration.

### Epinephrine

Epinephrine remains a useful addition to intermediate-acting LAs and possesses the unique characteristic of being an intravascular marker, which is important when potentially toxic doses of LA are used.<sup>255</sup> Epinephrine’s attributes of intravascular marker and increased LA duration are similar whether 5 µg/mL (1:200 000 dilution) or 2.5 µg/mL (1:400 000) dilution is used, but the latter has less detrimental impact on tachycardia or peripheral nerve blood flow. The vasoconstrictive effects of epinephrine lead to reduced LA clearance and thus prolong block duration, but also cause concern over its use in patients with abnormal peripheral nerves. Thus, epinephrine is relatively contraindicated in patients at risk for peripheral nerve injury, such as those with diabetes mellitus, hypertension, or tobacco use.<sup>255</sup> Even in healthy patients, concern for the integrity of peripheral nerve blood flow to the proximal sciatic nerve has led some experts to advocate avoiding epinephrine when using this approach, but there is no consistent evidence to support this advice.

### Clonidine

The non-neurotoxic alpha-2 adrenoceptor agonist clonidine prolongs analgesic duration by inhibiting cation current across the cell membrane. Prolongation is more effective with intermediate-acting than with long-acting LAs<sup>253</sup> where prolongation of anesthesia is only about 30% when added to ropivacaine 0.75% for femoral-sciatic nerve block<sup>256</sup> or 20% when added to bupivacaine 0.375% with epinephrine for popliteal sciatic nerve block. In the latter study, clonidine did not affect overall pain scores and supplementary analgesic use.<sup>257</sup> Bradycardia, hypotension, and drowsiness are linked to perineural clonidine doses greater than 100 µg. Based on data from upper extremity studies, clonidine is unlikely to add value to continuous infusion techniques and may (undesirably) enhance motor block.<sup>251</sup>

### Buprenorphine

Discovery of opiate receptors on primary afferent neural fibers suggests a possible adjuvant role for opioids.<sup>258</sup> The mu-agonist, kappa-antagonist buprenorphine is not neurotoxic when admixed with ropivacaine in cell cultures.<sup>253</sup> Unfortunately, its benefit for lower extremity blockade remains unclear. Candido *et al*<sup>258</sup> found that perineural buprenorphine 0.3 mg added to bupivacaine 0.5% with epinephrine for infragluteal sciatic nerve block enhanced and prolonged analgesia to a minor degree as compared with intramuscular (IM) administration, but was linked to increased nausea and vomiting. When admixed with dexamethasone 4 mg and bupivacaine 0.25%, perineural administration of buprenorphine 150 µg resulted in 16 hours longer average sciatic nerve block duration, but no difference in pain on movement at 24 hours.<sup>259</sup>

### Dexamethasone

Perineural and intravenous dexamethasone have been the subject of substantial investigation for prolonging neural blockade. Postulated mechanisms of action include inhibition of nociceptive C fibers, upregulation of potassium channels, and vasoconstriction.<sup>260 261</sup> At doses of 8 mg and higher, the existing literature suggests that perineural dexamethasone is not different from intravenous or IM administration in terms of clinically meaningful block quality or duration when using infragluteal

sciatic nerve block,<sup>260</sup> popliteal sciatic nerve block, or ankle block.<sup>261 262</sup> As noted previously, perineural dexamethasone 4 mg combined with buprenorphine 150 µg and 0.25% bupivacaine resulted in prolonged sciatic nerve block duration and lower worst pain scores after ankle surgery, but did not affect pain with movement at 24 hours. Moreover, the study’s multimodal analgesic approach using oxycodone/acetaminophen, meloxicam, pregabalin, and ondansetron resulted in low pain scores overall, making it difficult to assess the true contribution of dexamethasone. If dexamethasone is used, toxicity studies suggest limiting perineural dose to 1 to 2 mg.<sup>263 264</sup> A recent Cochrane review concluded that current evidence is insufficient to determine the effectiveness of dexamethasone as an adjuvant for lower extremity regional anesthesia.<sup>265</sup> As with epinephrine, the use of dexamethasone around diabetic peripheral nerves remains controversial.

### Dexmedetomidine

Perineural dexmedetomidine is non-neurotoxic and appears to be an effective adjuvant for prolonging lower extremity sensory and motor blockade when using long-acting LAs. Similar to clonidine, dexmedetomidine’s purported mechanism of action stems from its alpha-2 adrenoceptor agonist properties. However, it displays an alpha-2/alpha-1 selectivity eight times that of clonidine.<sup>266</sup> In a volunteer crossover study of US-guided posterior tibial nerve block, perineural dexmedetomidine 1 µg/kg admixed with ropivacaine 0.5% increased sensory block by an average 5.3 hours (about 25%).<sup>266</sup> For femoral nerve block, increasing the dose to 2 µg/kg resulted in only one additional hour of analgesia.<sup>267</sup>

## COMPLICATIONS OF LOWER EXTREMITY NERVE BLOCKS

### Complications common to all nerve blocks

The lack of RCTs investigating complications (and their treatments) related to lower extremity nerve blocks can be attributed to ethical reasons, as Institutional Review Boards are unlikely to approve proposals comparing active treatment versus placebo. Thus, in the following section, much of the discussion and recommendations are based on registries, quality assurance publications, prospective and retrospective observational studies, case series, animal trials, and practice advisories.

### Local anesthetic systemic toxicity

Because the lower extremity receives innervation from the lumbar and sacral plexuses, regional anesthesia of the lower limb often requires two or more nerve blocks. The resultant cumulative dose of LA can predispose to LAST. To complicate matters further, the manifestations of LAST after lower extremity blocks may be delayed because of the increased circulation time and the concomitant use of sedation or general anesthesia. Furthermore, perineural LA infusion constitutes another source of delayed LAST and hepatic/renal failure can increase the inherent risk. Fortunately, in clinical practice, the incidence of seizures after lower limb regional anesthesia seems relatively low. For instance, Auroy *et al* reported only three seizures out of 20 162 lower extremity nerve blocks (incidence=0.98/1000).<sup>268</sup> Similarly, in a prospective audit of 4522 lower limb blocks, Barrington *et al*<sup>269</sup> observed only two episodes of LAST (ie, overall incidence=0.44 per 1000 blocks). Two recent large retrospective (n=6678) and prospective (n=8101) studies detected only one episode of seizure each after lower limb regional anesthesia (incidence=0.12–0.215/1000).<sup>270 271</sup> The incidence of cardiovascular arrest from LAST also constitutes a

rare occurrence, as none occurred in published studies by Auroy *et al*, Barrington *et al*, Orebaugh *et al*, and Sites *et al*.<sup>268–271</sup> When present, clinical manifestations of LAST should be managed according to the (recently updated) ASRA recommendations (box 2).<sup>235</sup>

By decreasing the risk of vascular puncture during nerve blocks, US has been shown to curb the incidence of LAST across its clinical continuum, from minor symptoms to seizure and cardiac arrest.<sup>235 270 272–276</sup> In fact, the combined estimate of vascular puncture reveals a significant difference between US and PNS (Relative Risk = 0.16, 95% CI 0.05 to 0.47,  $p=0.001$ ).<sup>277</sup> Furthermore, propensity analysis also confirms that US can lower the risk of LAST by 65%.<sup>273</sup> However, US cannot completely eradicate LAST<sup>276 278</sup>; thus, continued vigilance is paramount to ensure timely diagnosis and treatment.

### Perioperative neurologic symptoms (PONS)

In regional anesthesia, one of the most feared complications is the unintentional intrafascicular injection of LA (box 2).<sup>279 280</sup> In animal (rat) models, intrafascicular injections of bupivacaine, lidocaine, or ropivacaine into the sciatic nerve result in significant neuronal loss, with the most severe changes occurring closest to the injection point.<sup>281</sup> In clinical practice, PONS occurs infrequently after lower extremity nerve blocks (table 3).<sup>268 281–284</sup> Furthermore, deficits seldom persist and most symptoms resolve within a few months (table 3).<sup>268–270, 282–287</sup> In fact, The American Society of Anesthesiologists (ASA) Closed Claims Study Group reported that litigation involving lower limb nerve injuries occur less commonly than that involving the brachial plexus.<sup>285</sup> In previous decades (1980s and 1990s), femoral and sciatic nerve injury accounted for 1% of the (non-obstetric) claims involving permanent neural deficit.<sup>285</sup> However, contemporary data reveal that injuries to other nerves (eg, popliteal sciatic, peroneal, and nerves of the ankle) are starting to occur more frequently due to the increasing popularity of these blocks (table 3).

The use of adjunctive PNS may provide a specific albeit non-sensitive method to detect an intraneural position of the needle tip. For example, in 4 of 24 patients who underwent popliteal sciatic nerve blocks, no EMR was obtained with stimulating currents of 1.5 mA (pulse width=0.1 ms) even when the needle was found to be intraneural.<sup>288</sup> However, intraneural injection occurred in all the patients with EMRs between 0.2 and 0.4 mA. Similarly, the presence of paresthesia constitutes an unreliable marker of neural penetration by the needle tip, as PONS have been reported despite the absence of sentinel paresthesia. Nonetheless, severe paresthesia on needle advancement or LA injection should alert to the possibility of intraneural needle position. Injection pressure has also been advocated as a possible monitor of intraneural placement.<sup>289</sup> For instance, pressures <15 psi are usually recorded when the needle tip is located 1 mm away from the nerve.<sup>290</sup> In contrast, pressures  $\geq$  15 psi suggest possible intraneural injection.

Ultrasound guidance ensures proximity between the needle tip and the nerve while avoiding neural penetration. In turn, this could (theoretically) decrease the incidence of PONS.<sup>276</sup> However, quality assurance and registry studies have found no difference in the prevalence of PONS between US and other localization techniques.<sup>270 276 291</sup> Fortunately, the occurrence of long-term PONS (ie, symptoms exceeding 6–12 months) is rare (incidence=2 to 4 per 10 000 nerve blocks). However, this also signifies that 70 000 patients per group would be required to demonstrate an US-related decrease from 4 to 2 injuries per 10 000 nerve blocks ( $\alpha=0.05$ ,  $\beta=0.8$ ).<sup>276</sup>

## Box 2 Summary statements and recommendations on complications after lower extremity peripheral nerve blocks

### Local anesthetic systemic toxicity (LAST)

- ▶ Symptoms of LAST can be delayed from slow absorption of the local anesthetic (3). The clinician should be aware of total local anesthetic dose and the delayed symptoms with LE blocks (4).
- ▶ The risk factors for LAST include extremes of age, low muscle mass, female gender, and patients with cardiac, liver, and metabolic comorbidities (3).
- ▶ ASRA recommendations for preventing LAST include the use of ultrasound (3), use of lowest effective dose (4), incremental injections (5), aspiration before each injection (5), and addition of epinephrine when employing potentially toxic doses (4).
- ▶ There is considerable variation in the presentation of LAST and the symptoms can be delayed up to 30–60 min (4).

### Postoperative neurologic symptoms (PONS)

- ▶ There are no clinical data to support the superiority of one nerve localization technique over another in terms of reducing PNI (3).
- ▶ High injection pressures have been related to fascicular injury in animal studies, but no human data have shown the effectiveness of monitoring the injection pressure in reducing PNI (3). Subjectively assessing injection pressure is not reliable (2).
- ▶ While US can detect intraneural injection, it does not have adequate resolution to distinguish between intrafascicular and interfascicular injection (5).

### Infectious complications

- ▶ Patients who are immunocompromised or have diabetes appear to be at greater risk (3).
- ▶ The risk of infection is higher with continuous compared with single-injection PNBs (3).
- ▶ There is higher incidence of colonization with LE block, especially blocks in the inguinal area (4). However, most colonizations do not result in clinical infection (3).
- ▶ Chlorhexidine-based solutions appear to be more effective than povidone-iodine in decreasing potential infectious complications (2).

### Hemorrhagic complications

- ▶ The elderly, subjects with low body weight, females, and patients with liver or kidney problems have exaggerated response to the effect of anticoagulant drugs (3).
- ▶ Blood loss can be a serious sequela of bleeding after LE peripheral nerve blocks (4).
- ▶ Deep plexus blocks (lumbar plexus blocks) have been associated with post-block hematomas (4). Extra vigilance should be observed with these injections (5).

### Role of ultrasound in complications

- ▶ US decreases the incidence of LAST across its clinical continuum of symptoms, from minor symptoms to seizure and cardiac arrest (3).
- ▶ There is no difference in the incidence of peripheral nerve injury between USG and other localization techniques (3).

### Blocks while patient is awake versus sleep

- ▶ Adults should not *routinely* receive regional anesthesia while they are anesthetized or deeply sedated (5).

Continued

## Box 2 Continued

- ▶ Multi-institutional prospective studies documented the safety of neuraxial and regional anesthesia in children (3). For pediatric patients, nerve blocks can be done under general anesthesia (3).

## Local anesthetic-induced myotoxicity

- ▶ Clinically evident local anesthetic myotoxicity is rare, but cases have been reported after adductor canal block (4).
- ▶ Muscle weakness is the usual symptom of local anesthetic myotoxicity (4).
- ▶ Most patients recover although it may take several months for complete recovery (4).

## Falls and lower extremity nerve blocks

- ▶ Risk factors associated with falls in patients who had peripheral nerve blocks include patients' age greater than 65 years, prolonged admission, primary total knee replacement surgery, obesity, use of femoral nerve catheter, male sex, and presence of comorbidities (fluid and electrolyte abnormalities, sleep apnea, psychosis, obesity, coagulopathy, and blood loss anemia) (3).
- ▶ Most of the falls after orthopedic surgery are due to unassisted mobilization, occur during the night or evening shift, and elimination (bathroom)-related (3).
- ▶ Patients who have a continuous LE peripheral nerve block have increased risk of falling compared with patients who did not have a nerve block (4).
- ▶ The decrease in strength of the quadriceps muscles is less with adductor canal block compared with a femoral nerve block (2). The incidence of "near falls" is less with adductor canal block (3).
- ▶ Periarticular local anesthetic injection, compared with femoral nerve block, results in a lower incidence of falls (3).
- ▶ Measures to reduce inpatient falls include educational programs, fall prevention protocols, and use of walkers, crutches, or a wheelchair until the block has resolved (3). Knee immobilizers improve lower extremity stability (3).

## Peripheral nerve catheter-related complications

- ▶ The incidence of infections from a peripheral nerve catheter is rare (3).
- ▶ Risk factors for catheter colonization include duration of catheter placement exceeding 24 hours, diabetes, and antibiotic administration the month before the surgery (3).
- ▶ Peripheral nerve catheters are safe in children in terms in terms of infection, LAST, or PONS (3). The most common adverse events are malfunction and dislodgement (3).
- ▶ The number of disconnection and reconnection should be limited (5). Unwitnessed disconnections should be removed (5).

## Tourniquet-related complications

- ▶ The application of a tourniquet during surgery reduces minor complications such as wound oozing, necrosis of wound margins, dehiscence, superficial infection, and leg swelling (3). However, it increases the risk of thrombotic events (3).
- ▶ Tourniquet use should be limited to 2 hours as nerve recovery is delayed with prolonged inflation (3).
- ▶ Venous emboli occurs in patients who have total knee arthroplasty, and the incidence is markedly increased after tourniquet deflation (3).

## Compartment syndrome

## Box 2 Continued

- ▶ Cases of compartment syndrome have been reported in patients who had LE nerve blocks; cardinal symptom is pain that is out of proportion to the injury and worsened by passive movement (stretching) of the affected muscles (4).
- ▶ The signs and symptoms include pain, edema of the affected extremity, pallor, stiffness of the involved muscles, paresthesia, and diminished or absent peripheral pulse (4).
- ▶ A high index of suspicion should be observed in patients with accelerating pain or increasing analgesic needs after surgery (5).
- ▶ Damage to muscle and nerves occur within 4 to 8 hours of the initial symptoms of compartment syndrome (3). Surgery should be conducted within 4–12 hours after the onset of symptoms (3).

Based on the Oxford Levels of Evidence (Level 1 = systematic review of randomized trials or n-of 1 trials; Level 2 = randomized trial or observational study with dramatic effect; Level 3 = non-randomized controlled cohort/follow-up study; Level 4 = case-series or case-control studies, or historically controlled studies; Level 5 = mechanism-based reasoning).

ASRA, American Society of Regional Anesthesia; LAST, local anesthetic systemic toxicity; LE, lower extremity; PNB, peripheral nerve block; PNI, peripheral nerve injury; PONS, postoperative neurological symptoms; US, ultrasound.

At present time, because the optimal method to detect intraneural injection remains elusive, the second ASRA practice advisory on neurologic complications has recommended that adult patients not *routinely* receive regional anesthesia while under general anesthesia or deep sedation.<sup>292</sup> Similarly, lower extremity nerve blocks should only be performed with extreme caution if the patient has a concomitant neuraxial block. In contrast, both the ASRA and the European Society of Regional Anesthesia and Pain Therapy support the performance of nerve blocks under general anesthesia in pediatric patients,<sup>293</sup> as multi-institutional prospective studies have demonstrated the safety of peripheral nerve blocks in children who are asleep.<sup>294–297</sup>

In summary, until the advent of definitive proof, the benefits of injection pressure measurement, adjunctive PNS, US guidance, and avoiding the performance of nerve blocks under general anesthesia remain theoretical and driven by expert opinion. However, in light of the significant sequelae associated with inadvertent intrafascicular injection, the prudent anesthesiologist may elect to incorporate some (or all) of these strategies into his/her clinical practice.

## Hemorrhage

Bleeding accompanied by retroperitoneal, psoas, and renal subcapsular hematoma has been reported after lumbar plexus blocks, attesting to the difficulty in diagnosing and halting hemorrhage occurring in deep and non-compressible areas.<sup>298–302</sup> In the case report authored by Klein *et al*,<sup>299</sup> the large psoas hematoma resulted in a 4-month lumbar plexopathy with weakness of the quadriceps, adductors, and hip flexor muscles.

The recent ASRA guidelines for regional anesthesia in patients receiving anticoagulation have attempted to stratify the hemorrhagic risk after peripheral nerve blocks. Superficial plexus/nerve blocks (eg, femoral block) are considered low risk, while their deep and non-compressible counterparts (eg, lumbar plexus and parasacral blocks) should be approached with extreme

Continued



**Table 3** Nerve injuries after lower extremity nerve blocks

Study	Nature of study	Results	Comments
Lee <i>et al</i> (2004) <sup>285</sup>	Data based on claims involving nerve injuries	1005 regional anesthesia claims. Peripheral nerve blocks accounted for 13% of claims; permanent damage associated with 29% of claims (1% femoral/sciatic nerves).	Claims involving lower extremity blocks low in comparison to upper extremity blocks (1% of claims involved lower extremity compared with 28% with upper extremity blocks). However, data reflect an era where lower extremity nerve blocks were less popular and performed mostly with PNS.
Auroy <i>et al</i> (1997) <sup>282</sup>	Prospective survey of regional anesthesia complications; 5-month study period; 736 anesthesiologists	21 278 peripheral nerve blocks. Four cases of radiculopathy (specific nerve block not stated).	Nerve blocks mostly performed with PNS. Two thirds of patients with neurologic deficits had either paresthesia during needle placement or pain on injection.
Auroy <i>et al</i> (2002) <sup>268</sup>	Prospective survey; 10-month study period; 487 participants	50 223 peripheral nerve blocks. Peripheral neuropathy: femoral (3/10 309), sciatic (2/8507), popliteal (3/952).	Nerve blocks mostly performed with PNS. Seven of 12 patients had persistent neuropathy after 6 months; neurologic complications noted when there was concomitant paresthesia (2/12), use of neurostimulation (9/12) or stimulatory threshold below 0.5 mA (3/12).
Capdevila <i>et al</i> (2005) <sup>286</sup>	Prospective study on continuous peripheral nerve blocks	1416 patients. Patients with nerve lesions: femoral (3/683), fascia iliaca (0/94), sciatic (0/32), popliteal (0/167), distal (1/38).	In 2 of 3 femoral neuropathies, the blocks were done while the patients were anesthetized. One patient reported sharp pain on injection. Complete resolution occurred in 36 hours, at 6 weeks, and at 10 weeks.
Compere <i>et al</i> (2009) <sup>283</sup>	Prospective study on continuous popliteal sciatic nerve blocks; 400 patients over a 2-month period	Median time of catheter usage: 47 hours. Two cases of neuropathy (0.5%).	Paresthesia in the superficial peroneal nerve distribution; beyond 18 months in one patient (paresthesia reported during nerve localization).
Brull <i>et al</i> (2007) <sup>284</sup>	Review of 32 published studies between 1 January 1995 and 31 December 2005	Rate of neuropathy after femoral nerve blocks: 0.34:100 (95% CI 0.04 to 2.81:100).	Only 1 case of permanent neuropathy reported among 16 studies.
Barrington <i>et al</i> (2009) <sup>269</sup>	Prospective study of complications after peripheral nerve blocks, January 2006–May 2008	7156 peripheral nerve blocks in 6069 patients. 30 patients (0.5%) had neurologic feature (pain, paresthesia, weakness, motor deficit); 3/30 patients had block-related injury (0.4 per 1000 blocks; 95% CI 0.08 to 1:1000).	Eleven of the 30 patients received lower extremity nerve blocks; seven were unrelated to the block; one due to tourniquet neuropraxia; one had an underlying neuropathy; two related to block (sensory deficits lasted 12 months and greater than 6 months, respectively).
Orebaugh <i>et al</i> (2012) <sup>270</sup>	Retrospective study using Quality Improvement electronic database	3543 (39%) of 9069 blocks were for the lower extremity. Four patients displayed symptoms lasting 6–12 months while one lasted more than 12 months.	The type of nerve block where injury occurred not specified.
Hajek <i>et al</i> (2012) <sup>287</sup>	Retrospective study of neuropathic complications after continuous popliteal nerve blocks	157 blocks. Three patients displayed common peroneal nerve damage (surgical causes eliminated).	One patient—motor function improved at 5 months but had residual weakness; two patients—improved motor but residual hypoesthesia at 11 months.

PNS, peripheral nerve stimulation.

**Table 4** Rate of infectious complications after lower extremity perineural catheters

Study (year)	Incidence of infection	Comments
Neuberger <i>et al</i> (2007) <sup>307</sup>	2285 perineural catheters (upper or lower limb). Incidence of infection: femoral catheter (3.3%), posterior popliteal (2.8%).	Duration of catheter placement constitutes a risk factor.
Cuvillon <i>et al</i> (2001) <sup>308</sup>	211 femoral catheters. Colonization with bacteremia in 3 (15%) patients. Bacterial colonization occurred in 57% of catheters at 48 hours, primarily <i>Staphylococcus</i> (71%) and <i>Enterococcus</i> (10%).	Catheters removed at 48 hours and cultures done, patients followed for 48 hours and 6 weeks.
Borgeat <i>et al</i> (2006) <sup>309</sup>	1001 popliteal sciatic catheters. 0% incidence of infection	Patients followed for 12 weeks.
Compere <i>et al</i> (2009) <sup>283</sup>	400 popliteal sciatic catheters. 1 (0.25%) case of infection.	One case of thigh abscess with methicillin-resistant <i>Staphylococcus aureus</i> .
Capdevila <i>et al</i> (2005) <sup>286</sup>	1416 patients with upper or lower limb perineural catheters. 1/683 (0.07%) abscess occurred after a femoral catheter in a diabetic woman No infection occurred after fascia iliaca (94), sciatic (32), popliteal (167), or distal (38) catheter infusions—median duration of 56 hours. Rates of positive bacterial colonization of catheters, upper and lower extremity: 29% (278/969).	Risk factors for local inflammation/infection include intensive care confinement, catheter duration greater than 48 hours, male gender, absence of antibiotic prophylaxis.
Wiegel <i>et al</i> (2007) <sup>310</sup>	1398 perineural catheters (upper or lower limb). Local inflammation: 4/628 (0.6%) femoral catheters; 4/549 (0.7%) sciatic catheters. Local infection: 3/628 (0.5%) femoral catheters; 0% sciatic catheters.	2/3 cultures positive: 1— <i>Staphylococcus epidermidis</i> ; 1— <i>Staphylococcus aureus</i> ; no patient showed signs of systemic infection.
Aveline <i>et al</i> (2011) <sup>306</sup>	760 perineural catheters (upper or lower limb). Incidence of colonization: 42/465 (9%) femoral catheters; 3/42 (7.1%) subgluteal catheters; 6/63 (9.5%) popliteal catheters.	No patient showed local or systemic inflammation at the time of catheter removal.
Schroeder <i>et al</i> (2012) <sup>311</sup>	Femoral catheters. Incidence of colonization: 3/48 (6.3%) in BIOPATCH (chlorhexidine-impregnated patch) patients compared with 2/47 (4.3%) non-BIOPATCH patients ( $p > 0.999$ ).	Femoral catheters inserted and tunneled following chlorhexidine cleansing.

caution (if at all) in patients receiving anticoagulation. Intermediate-risk peripheral nerve blocks should be assessed on a case basis according to site compressibility, body habitus, comorbidities as well as the degree of anticoagulation.<sup>303</sup> Studies on anticoagulants have demonstrated that patients who are elderly, female, afflicted with hepatorenal dysfunction, or have a low body weight can display an exaggerated response to the effect of these drugs.<sup>304</sup> Moreover, in the literature, reports of bleeding have occurred with the combination of anticoagulants possessing different mechanisms of action (eg, enoxaparin and aspirin,<sup>299</sup> warfarin and aspirin<sup>301</sup>) or drugs with the same antiplatelet action (eg, dipyridamole and aspirin).<sup>305</sup> Thus, the performance of nerve blocks in patients receiving more than one anticoagulant is strongly discouraged.<sup>304</sup>

### Infection

The prevalence of bacterial colonization associated with lower extremity perineural catheters is high (especially in the inguinal area) (29%–57%). Independent risk factors for catheter colonization include duration of catheter placement (>24 hours), diabetes, and antibiotic administration the month before surgery.<sup>306</sup> Fortunately, the incidence of true infection requiring antibiotic or surgical therapy is much lower (0%–3%) and, expectedly, increases with the duration of catheter placement (table 4).<sup>286 306–312</sup> In a prospective study of 20 174 perineural catheters,<sup>313</sup> patients who developed an infection displayed a longer median (IQR) duration of catheter placement than those who did not (4.5 (3–7) vs 3 (1–3);  $p < 0.001$ ). Although infection following perineural catheter placement usually occurs at the insertion site, cases of bacteremic seeding resulting in psoas abscess (after a continuous femoral catheter),<sup>314 315</sup> or thigh abscess (after a continuous popliteal sciatic catheter)<sup>312</sup> have been reported.

Both the ASRA and the ASA have issued practice advisories to curtail the risk of infectious complications: their recommendations are virtually identical (ie, thorough hand washing, skin

disinfection with chlorhexidine, use of surgical gloves as well as mask) (box 2).<sup>316 317</sup> Additionally, disinfection of the US machine is recommended, as this practice has been shown to reduce bacterial colonization of the equipment.<sup>318</sup> Although chlorhexidine-based solutions are most effective for skin disinfection,<sup>319 320</sup> chlorhexidine-impregnated patches do not appear to decrease the risk of bacterial colonization for perineural catheters.<sup>311</sup>

Premature disconnection occasionally occurs with perineural catheters. Although no recommendation exists for witnessed catheter disconnection, the prudent anesthesiologist can employ the ASA practice advisory issued for neuraxial catheters<sup>317</sup>: in the event of witnessed disconnection, one should limit the time between disconnection and reconnection. However, in cases of unwitnessed disconnection, perineural catheters should be immediately removed.

### Local anesthetic-related myotoxicity

All LAs are inherently myotoxic.<sup>321–323</sup> However, clinically evident myotoxicity is rare and has been mostly confined to retrobulbar and peribulbar blocks until now.<sup>324–331</sup> In recent years, sentinel cases have been reported after femoral triangle/adductor canal blocks.<sup>323</sup> Signs and symptoms of LA-related myotoxicity include swelling, paresis, and pain that is typically aggravated by stretch and relieved by shortening of the muscle.<sup>321</sup> However, in recent reports,<sup>323</sup> swelling and pain were not always manifest, and flaccid quadriceps paralysis constituted the more consistent finding. MRI can reveal edema, localized swelling as well as inflammatory changes. Diminished action potentials, consistent with myopathy, appear on electromyography. Muscle biopsy confirms the diagnosis of muscle injury (ie, degenerating and regenerating muscle fibers, fiber splitting, and inflammatory infiltrates).<sup>322</sup> Treatment remains conservative and includes non-steroidal anti-inflammatory drugs, non-opioid analgesics, and physical therapy. Although most patients recover, the process may take several months.

## Complications specific to lower extremity nerve blocks

### Patient fall

One of the most prevalent concerns after lower extremity nerve blocks is patient fall. In 2010, Ilfeld *et al*<sup>332</sup> pooled data from three published RCTs involving continuous femoral nerve blocks for hip and knee arthroplasty. These authors detected no fall in 86 patients who received perineural saline infusion compared with 7 falls in 85 subjects who were administered perineural ropivacaine ( $p=0.013$ ). In 2013, Johnson *et al*<sup>333</sup> also concluded that continuous lumbar plexus blockade was associated with a fourfold greater risk of fall when compared with single-injection or no blockade. The association between lower extremity nerve blocks and inpatient falls was further investigated by Crumley-Aybar *et al*,<sup>334</sup> who pooled data from 13 separate articles that met their inclusion criteria. These authors reported that a patient who had a peripheral nerve block incurred an eight times greater risk of fall and that the number (of blocks)-needed-to-harm was 50.<sup>334</sup> However, the association between nerve blocks and falls has been recently challenged by Memtsoudis *et al*.<sup>335</sup> Using a national Premier Perspective database of 191 570 patients, these authors found no link between peripheral nerve blocks and inpatient falls.<sup>335</sup> Furthermore, from a mechanistic standpoint, it is possible that sensorimotor blockade does not constitute the primary etiology for falls, as Turbitt *et al*<sup>336</sup> have detected no difference in the rate of falls between patients with femoral catheters in situ, subjects who fell less than 12 hours after catheter removal, and those who incurred a fall more than 12 hours after catheter removal. Other important contributory factors could include medication side effects, delirium, reduced vigilance, decreased strength in the surgical limb, and non-adherence to the fall-prevention protocol. Nonetheless, as a preventive measure, Ilfeld *et al*<sup>332</sup> have recommended minimizing the LA dose and employing limited-volume patient-controlled bolus doses for perineural catheters. Other measures include the adoption of a specific protocol to prevent falls and the use of assistive devices (eg, walker, crutches, knee immobilizer, wheelchair) until the block recedes. Unfortunately, beneficial effects stemming from these programs remain ambiguous.<sup>337 338</sup>

### Local anesthetic spread to adjacent structures

During the performance of lumbar plexus blocks, LA can diffuse to the epidural space thereby resulting in total spinal anesthesia and circulatory collapse.<sup>95 286 339 340</sup> Femoral triangle blocks may result in quadriceps weakness due to retrograde LA spread to the muscular branches of the femoral nerve.<sup>341 342</sup> Voiding difficulties requiring bladder catheterization (or urinary incontinence) can occur after parasacral blocks due to the proximity of the injection site and the autonomic nerves supplying the bladder.<sup>343 344</sup>

### Needle trauma to adjacent structures

Cases of rectal perforation and hematoma have been described with parasacral blocks.<sup>345</sup>

## Complications related to lower extremity surgery

### Tourniquet-related complications

Although arterial tourniquets shorten surgical time, they do not prevent blood loss or blood transfusion but, in fact, can increase the risk of thromboembolic events.<sup>346-348</sup> As a general rule, tourniquet time should be limited to 2 hours, as inflation periods exceeding 100 min are associated with an increased risk of infections, deep vein thrombosis, compartment syndrome, and nerve injury.<sup>349</sup>

Neural damage after tourniquet inflation ranges from paresthesia to paralysis<sup>350-352</sup> and can be attributed to mechanical pressure as well as ischemia. Transient tourniquet release followed by re-inflation has been advocated to alleviate neural impairment. Unfortunately, this maneuver only modestly decreases the risk of neural injury.<sup>353</sup> Strategies to prevent tourniquet-related complications include proper maintenance of the cuff and rubber tubing, positioning the tourniquet at the maximal circumference of the lower limb, confirmation of the manometer's accuracy, ensuring that the padding placed underneath the tourniquet is free of folds, and alerting the surgeon at frequent and agreed-upon temporal intervals (box 2).<sup>351</sup>

### Compartment syndrome

The etiology of compartment syndrome is multifactorial and includes tight dressings/casts, malposition of the lower limb during a long surgery, and trauma. The increased pressure within the compartment decreases vascular flow in arterioles, leading to neuromuscular infarction and necrosis. Damage to muscle and nerves usually occurs within 4 to 8 hours.<sup>354</sup> Thus, early diagnosis and surgical decompression (within 4–12 hours) is paramount to prevent permanent deficits.<sup>354-356</sup> The cardinal symptom of compartment syndrome is pain that is out of proportion with the injury and worsened by passive movement (stretching) of the affected muscle. Objective signs include edema, pallor, stiffness, diminished peripheral pulses, and muscle paresis.<sup>356-358</sup> Unfortunately, these clinical findings can be unreliable; furthermore, pulselessness and paralysis usually occur late in the evolution of compartment syndrome.<sup>359</sup>

One of the greatest controversies in regional anesthesia revolves around the (safe) performance of peripheral nerve blocks in patients who are at risk for compartment syndrome. Because the latter has been reported in subjects who had received lower extremity nerve blocks,<sup>354 356 360-364</sup> some experts have questioned whether lower limb regional anesthesia can delay the diagnosis by masking the pain of compartment syndrome. In contrast, others have argued that occurrence of “breakthrough pain” despite an effective sensorimotor block constitutes a reliable manifestation of compartment syndrome.<sup>356 363</sup> Furthermore, pain in neural territories not anesthetized by the nerve block can offer another important diagnostic clue.<sup>354</sup> Until the conundrum can be solved, communication between anesthesiologists and surgeons is paramount when/if carrying out regional anesthesia in patients at risk for compartment syndrome. Furthermore, if nerve blocks are performed, a dilute LA concentration should be selected in order to provide adequate analgesia while avoiding profound sensorimotor blockade.<sup>354</sup>

### Neural injury related to lower extremity surgery

Lower extremity surgery can lead to multiple neural injuries. For instance, total hip arthroplasty (THA) may result in injury to the common peroneal nerve (due its subcutaneous location) and to the femoral nerve (due to compression from an improperly placed retractor).<sup>365</sup> Furthermore, the superior gluteal and lateral femoral cutaneous nerves can be damaged with the lateral and anterior surgical approaches, respectively. During hip arthroscopy, the perineal post may cause traction injury to the pudendal nerve. Total knee arthroplasty can result in impairment of the common peroneal nerve due to traction or compressive hematoma. Damage to the saphenous nerve may occur during arthroscopic meniscal repair and the infrapatellar branch can be harmed during ACL reconstruction.<sup>365</sup> Because ankle arthroscopy is performed via anterior and posterior approaches, damage to

**Table 5** Important issues pertaining to lower extremity surgery and peripheral nerve blocks warranting further investigation with randomized controlled trials

Total knee arthroplasty	<ul style="list-style-type: none"> <li>▶ Comparison between adductor canal and femoral triangle block</li> <li>▶ Comparison between femoral and adductor canal/femoral triangle block in terms of patient mobilization and risk of fall</li> <li>▶ Comparison between single-injection and continuous adductor canal/femoral triangle block</li> <li>▶ Investigation of SPANK block for posterior knee pain</li> <li>▶ Investigation of adjunctive obturator block in the setting of continuous femoral/femoral triangle/adductor canal block</li> <li>▶ Comparison between single-injection and continuous obturator block as an adjunct to femoral/femoral triangle/adductor canal block</li> </ul>
Anterior cruciate ligament repair	<ul style="list-style-type: none"> <li>▶ Additional comparison between femoral and adductor canal/femoral triangle block</li> <li>▶ Long term (6 months) quadriceps muscle strength in patients receiving adductor canal/femoral triangle block</li> </ul>
Total hip arthroplasty	<ul style="list-style-type: none"> <li>▶ Additional comparison between multimodal analgesia (without or without intrathecal morphine) and lower extremity nerve blocks</li> <li>▶ Comparison between suprainguinal fascia iliaca block and lumbar plexus or femoral nerve block</li> <li>▶ Comparison between single-injection and continuous femoral/fascia iliaca block</li> </ul>
Hip fracture surgery	<ul style="list-style-type: none"> <li>▶ Comparison between ultrasound-guided fascia iliaca block and femoral or lumbar plexus block</li> <li>▶ Comparison between single-injection and continuous lumbar plexus/femoral/fascia iliaca block</li> </ul>

cutaneous nerves may result from the placement of arthroscopic portals. The tibial nerve can be particularly vulnerable during posteromedial portal insertion.<sup>366</sup> An anterior approach for total ankle replacement can lead to injury of the peroneal nerve. The superficial peroneal and sural nerves may be traumatized by the lateral cutaneous incision commonly used in ankle arthrodesis. Therefore, in light of the potential neural injury associated with surgery itself, nerve blocks should not be automatically assumed to be the cause of PONS. Instead, the prudent anesthesiologist should seek a neurologic consultation and conduct a thorough investigation to establish the topography of the deficit and the likely etiologic factors. The results of these investigations will inform the prognosis and optimal management strategy.

### CONTROVERSIAL AREAS RELATED TO OUTCOMES

Over the last 20 years, the advent of prophylactic anticoagulation, the increasing popularity of US for lower extremity nerve blocks,<sup>367</sup> and the rehabilitative benefits associated with continuous femoral and femoral triangle blockade for TKR<sup>368–370</sup> have ushered in a new standard of care. In contemporary practice, single-injection and continuous lower extremity nerve blocks are routinely employed to provide postoperative analgesia for TKR, ACL repair, THA, and hip fracture surgery. While an in-depth discussion of the evidence supporting the many different nerve blocks for these surgical procedures exceeds the scope of the current review article, a brief overview of controversial areas may be warranted (table 5).

#### Total knee arthroplasty

The anterior, medial, and posterior aspects of the knee joint are primarily innervated by the femoral, obturator, and sciatic nerve, respectively (figure 4). Because continuous femoral blocks provide comparable analgesia and fewer side effects (eg, hypotension, urinary retention) than lumbar epidural analgesia, they have been routinely used in the setting of TKR since 1998.<sup>368 369 371</sup> However, in the last 5 years, their hegemony has been challenged by so-called adductor canal blocks. The latter aim to spare the main femoral nerve thereby preserving quadriceps motor function. Randomized trials comparing single-injection and continuous adductor canal to femoral blocks have all confirmed that the former result in improved postoperative quadriceps strength with minimal impact on the quality of pain control after TKR.<sup>370 372–374</sup> However, whether the improved

motor function of the quadriceps muscle results in better patient mobilization and a decreased risk of fall remains debatable.<sup>374–377</sup> Future investigation is required to elucidate the matter. Furthermore, since the introduction of adductor canal blocks into clinical practice, some authors have employed single-injection blocks<sup>374</sup> while others have advocated continuous blockade.<sup>370 373 376 377</sup> Thus, randomized trials are required to compare single-injection and continuous adductor canal blocks for TKR. More importantly, the optimal injection site requires clinical elucidation: recent anatomical studies suggest that LA injection at the midpoint between the anterosuperior iliac spine and the patella, a technique favored by most authors, targets in fact the femoral triangle (which contains the saphenous nerve and the nerve to the vastus medialis muscle) and not the adductor canal per se (which contains the saphenous nerve).<sup>14 22 378</sup> Therefore, future trials are required to determine if femoral triangle blocks may be superior to their adductor canal counterparts because of concomitant anesthesia of the saphenous nerve and the nerve to the vastus medialis muscle.

In addition to femoral (or femoral triangle) blockade, supplemental obturator nerve blocks have been advocated for TKR by some authors. Compared with femoral nerve blocks (with or without concomitant sciatic nerve blocks), the addition of obturator blocks has been demonstrated to improve pain control and decrease consumption of breakthrough opioids.<sup>119 379</sup> Furthermore, the benefits stemming from obturator blockade also seems to extend to postoperative analgesic regimens using femoral triangle blocks. In 2016, Runge *et al*<sup>380</sup> compared femoral triangle blocks to combined femoral triangle-obturator blocks in patients undergoing TKR. These authors reported that the addition of obturator blockade resulted in decreased opioid consumption, pain scores and side effects (ie, nausea and vomiting). Although patients randomized to femoral triangle-obturator blocks (expectedly) displayed decreased motor strength, this did not impact ambulation. To date, RCTs have only investigated obturator blocks in the setting of single-injection femoral and femoral triangle blocks. Thus, future studies should determine if the benefits associated with obturator blocks would still persist in the setting of continuous femoral/femoral triangle blocks. Furthermore, continuous obturator blocks should also be investigated for TKR.

The issue of supplemental sciatic nerve block remains controversial. Although the combination of femoral and sciatic blocks

seem to provide optimal analgesia for TKR,<sup>381–383</sup> the impact of calf and foot motor paralysis on physiotherapy and ambulation remains a concern for many practitioners.<sup>154</sup> Proposed alternatives to sciatic nerve block include LA infiltration of the posterior capsule of the knee joint, selective tibial nerve block,<sup>384</sup> and sensory posterior articular nerve of the knee (ie, SPANK) block.<sup>385</sup> Posterior capsular infiltration remains controversial, as Gi *et al*<sup>386</sup> found it to be a viable alternative to sciatic nerve block whereas Safa *et al*<sup>387</sup> and Pinsornak *et al*<sup>388</sup> concluded that it confers no additional analgesia when combined with femoral nerve block or standard LA infiltration of the knee, respectively. Although selective tibial nerve block spares the peroneal nerve (and prevents the occurrence of foot drop), its impact on ambulation and rehabilitation remains unknown. Further trials are required to investigate SPANK blocks.

### ACL reconstruction

In contemporary practice, ACL repair is usually carried out with an arthroscopic surgical technique. Femoral nerve block remains the most common choice for postoperative analgesia. In the most recent meta-analysis (11 trials; 628 patients), Kirkham *et al*<sup>389</sup> concluded that, compared to intra-articular LA infiltration, femoral blockade results in superior analgesia in the immediate (0–2 hours), intermediate (3–12 hours), and late (13–24 hours) postoperative periods. Unfortunately, the meta-analysis could not draw definitive conclusions pertaining to functional outcomes (eg, quadriceps motor strength, range motion) and complications (eg, fall), as these parameters were not recorded by the original trials. Currently, the most controversial issue surrounding femoral blocks for ACL repair revolves around femoral nerve injury and quadriceps motor dysfunction. In 2017, Stebler *et al*<sup>390</sup> randomized 74 patients undergoing ACL reconstruction to 48 hours of continuous femoral nerve block or intravenous opioids. At 4 weeks, all patients underwent electrophysiological studies: no patient in either group met the electrophysiological criteria for femoral nerve injury. In contrast, in a recent systematic review article, Swank *et al*<sup>391</sup> pooled the findings of six studies that assessed quadriceps strength between 7 days and 6 months postoperatively. Swank *et al*<sup>391</sup> reported that, at 6 months, two out of four studies detected greater deficits in isokinetic testing in patients who had received femoral blocks for ACL reconstruction. In another study, the deficit persisted at 6 weeks but had subsided by 6 months. The clinical implication of these findings remains uncertain, as no differences were observed in terms of functional outcomes and patient return to sports at 6 months after ACL reconstruction.<sup>391</sup>

In recent years, El Ahl<sup>392</sup> and Abdallah *et al*<sup>393</sup> set out to investigate the benefits of quadriceps-sparing femoral triangle/adductor canal blocks compared with femoral blocks for ACL reconstruction. Expectedly, in both studies, patients randomized to the former displayed superior quadriceps strength as assessed by straight leg raise during the first 24 hours<sup>392</sup> or maximal voluntary isometric contraction at 45 min.<sup>393</sup> However, the findings pertaining to pain control differed between the two trials. Whereas Abdallah *et al*<sup>393</sup> found that femoral triangle/adductor canal blocks resulted in non-inferior analgesia and opioid consumption compared to femoral blocks, El Ahl<sup>392</sup> reported lower pain scores (at 18 and 24 hours) as well as decreased morphine consumption in patients receiving femoral blocks. This discrepancy could be attributed to the nature of the graft: patellar<sup>392</sup> versus hamstring or bone–tendon–bone.<sup>393</sup> Nonetheless, in light of these contradictory results, additional trials are needed to compare femoral triangle/adductor canal and femoral

blocks for the different types (grafts) of ACL repair. Furthermore, future studies should investigate long-term (6 months) muscle strength in patients receiving femoral triangle/adductor canal blocks for ACL repair.

### Total hip arthroplasty

The hip joint receives sensory innervation from both the lumbar and sacral plexuses (figure 4). However, the contribution of the former may be more important<sup>31</sup> and as a result, most randomized trials have focused on lumbar plexus, femoral, and fascia iliaca blocks. The contemporary literature displays remarkably consistent results: compared with sham/no blocks, lower extremity nerve blocks result in significant benefits (eg, decreased postoperative pain and opioid consumption) for patients undergoing THA.<sup>394–399</sup>

Lumbar plexus, femoral, and fascia iliaca blocks have been compared with one another with mixed results. For instance, Biboulet *et al*<sup>87</sup> reported that during the first 4 hours after THA, pain scores and morphine consumption were lower with single-injection lumbar plexus blocks than single-injection femoral blocks. However, after 4 hours, no significant differences could be detected between the two groups. In contrast, Marino *et al*<sup>400</sup> observed that, compared to their continuous femoral counterparts, continuous lumbar plexus blocks consistently provided lower pain scores during the first two postoperative days. Furthermore, the use of continuous lumbar plexus blocks was associated with a decreased incidence of opioid-related side effects, greater distances walked, and improved patient satisfaction.<sup>400</sup> Ilfeld *et al*<sup>401</sup> have also compared continuous lumbar plexus and femoral blocks in patients undergoing THA. Although they did find greater ambulation distances with lumbar plexus catheters, unlike Marino *et al*,<sup>400</sup> they could not detect intergroup differences in terms of pain, breakthrough analgesic consumption, and patient satisfaction.<sup>401</sup> In a recent meta-analysis (five trials; 308 patients), Wang *et al*<sup>402</sup> set out to compare fascia iliaca and femoral blocks for THA: these authors concluded that fascia iliaca and femoral blocks result in equivalent analgesia. However, their findings should be interpreted with caution, as all pooled trials have employed the conventional infrainguinal technique for fascia iliaca blocks. In 2015, Kumar *et al*<sup>403</sup> demonstrated that, compared with its infrainguinal counterpart, a suprainguinal technique results in improved analgesia (at 6 hours) and decreased opioid consumption (at 24 hours) for patients undergoing THA. These authors speculated that the suprainguinal method promote cephalad diffusion of LA, resulting in a more reliable spread toward the lumbar plexus.<sup>403</sup> Thus, additional trials are required to compare suprainguinal fascia iliaca and femoral blocks in patients undergoing THA. Moreover, future studies are also required to compare suprainguinal fascia iliaca and lumbar plexus blocks.

In addition to elucidating the optimal nerve block for THA, future investigation should also confirm the benefits of continuous over single-injection lower extremity nerve blocks. In 2008, Ilfeld *et al*<sup>404</sup> reported that, for lumbar plexus blocks, compared with an overnight LA (ropivacaine 0.2%) infusion, a 4-day infusion regimen attained three discharge criteria (ie, adequate analgesia, independence from intravenous analgesics, and ambulation distance  $\geq 30$  m) more swiftly. However, health-related quality of life, measured using the Western Ontario and McMaster Universities Osteoarthritis (WOMAC) index, was comparable between the two groups from 7 days to 1 year after surgery.<sup>405</sup> Similar trials are required for femoral and fascia iliaca blocks. More importantly, future investigation

should attempt to determine if regional anesthesia is truly necessary for THA. There exists some evidence to suggest that intrathecal morphine may provide similar (or superior) efficacy to fascia iliaca blocks<sup>406</sup> and lumbar plexus blocks.<sup>407</sup> Furthermore, in a recent network meta-analysis (35 trials, 2296 patients), Jiménez-Almonte *et al*<sup>408</sup> found no differences between LA infiltration and peripheral nerve blocks in terms of analgesia or opioid consumption 24 hours after THA. In fact, in a recent trial, Kuchálik *et al*<sup>409</sup> observed that, compared to femoral blocks, LA infiltration resulted in decreased pain during mobilization and lower morphine consumption at 24 hours.

### Hip fracture surgery

Hip fracture commonly occurs in an at-risk (elderly) patient population that is often afflicted with multiple comorbidities (eg, osteoporosis). Peripheral nerve blocks have been traditionally employed to optimize postoperative analgesia and curtail the consumption of breakthrough opioids. In the most recent Cochrane Database systematic review (31 trials; 1760 patients), Guay *et al*<sup>410</sup> concluded that regional anesthesia decreases pain on movement within 30 min after block placement. Furthermore, moderate-quality evidence suggests that lower extremity nerve blocks also reduce the risk of pneumonia as well as the time to first mobilization.<sup>410</sup> Possible nerve blocks for hip fracture include lumbar plexus, femoral, lateral femoral cutaneous, and fascia iliaca compartment blocks. Expectedly, LFCN blocks confer minimal benefits<sup>411</sup> because they anesthetize the skin of the lateral thigh but not the fractured bone (figure 4). To date, most randomized trials have compared single-injection femoral and fascia iliaca blocks with mixed results.<sup>412 413</sup> While Reavley *et al*<sup>412</sup> observed no significant differences between the two blocks, Newman *et al*<sup>413</sup> reported that patients receiving fascia iliaca blocks required significantly more morphine than those receiving femoral nerve blocks. This discrepancy could be attributed to the fact that the “blind” fascia iliaca technique, favored by both Reavley *et al* and Newman *et al*, can be notoriously unreliable, as fascias consist of several layers separated by adipose tissue; thus, blind puncture of any of these layers could have been mistaken for the second “pop.”<sup>113</sup> Thus, future trials should endeavor to compare lumbar plexus, femoral, and fascia iliaca blocks using optimal techniques (eg, US guidance for fascia iliaca blocks). Furthermore, the benefits of continuous nerve blocks should be investigated for patients with hip fractures.

The research arena surrounding hip fracture surgery can be deceptively complex, as it encompasses multiple surgical interventions (eg, insertion of pins and screws or hemiarthroplasty). In a previous cohort study, Foss *et al*<sup>414</sup> have observed higher postoperative pain levels in subjects receiving dynamic or intramedullary hip screws than those undergoing hemiarthroplasty. Thus, future trials should carefully define their study population a priori; furthermore, researchers should be cognizant of the fact that their results may not be translated to a different type of hip fracture or another surgical intervention. Because nerve blocks can be performed in three different settings (ambulance, emergency department, and operating room), the situation becomes even more intricate from a technical and safety standpoint. For instance, while most emergency and operating rooms benefit from ready access to US machines, ambulances may not be outfitted with the latter; thus, despite its documented shortcomings, “blind” fascia iliaca blocks may constitute the only option.<sup>415</sup> Moreover, lumbar plexus block carry an inherent risk of LA spread to the epidural space.<sup>95</sup> Therefore, although they are routinely (and safely) performed in operating room settings,

the prudent emergency physician may opt for more conservative options like femoral (or fascia iliaca) blocks.

### FUTURE RESEARCH DIRECTIONS

Thirteen years have elapsed since the publication of the first review article on lower extremity regional anesthesia.<sup>1</sup> During this time, lower limb nerve blocks have enjoyed renewed popularity due to the implementation of US guidance and its conferred ability to visualize the needle, nerve, and LA spread. In parallel to the clinical resurgence of lower extremity blocks, our collective understanding of lower limb anatomy has also progressed by leaps and bounds. For instance, although not novel per se, certain anatomical concepts (such as the subparaneural compartment) have crossed over into the clinical realm and led to the development of new techniques (eg, subparaneural sciatic blocks). However, much work is still required, as other anatomical concepts (eg, contents of the femoral triangle and adductor canal) remain hotly debated. Furthermore, the understanding of “new” anatomical notions, like the relative contributions of the sciatic and obturator nerves to the popliteal neural plexus, remains embryonic and requires further research in years to come.

Despite current best evidence, many important technical issues regarding lower extremity nerve blocks remain unresolved and mandate investigation with well-designed and adequately powered trials (table 2). Most importantly, despite Cappelleri *et al*'s promising initial results,<sup>201</sup> the risk:benefit ratio of intentional tibial and peroneal intraneural injection necessitates further validation. Until the time when the safety and maximal LA volume/concentration for intraneural injection are elucidated beyond a reasonable doubt, the authors advise extreme caution when breaching (if at all) the epineurium of small peripheral nerves, as current US technology cannot distinguish between intraneural extrafascicular and intrafascicular positions of the needle tip.

Local anesthetic pharmacology benefits from a substantial amount of research cumulated throughout the years. Results acquired using traditional nerve localization modalities (eg, PNS) can and will apply to lower extremity nerve blocks performed with US. However, future research is still very much needed to investigate the optimal doses of novel adjuncts such as dexamethasone and dexmedetomidine. Moreover, investigators should remember to compare the clinical effects of these molecules to each other.

Since lower extremity regional anesthesia is (axiomatically) performed for lower extremity surgery, future trials must determine the optimal blocks for the different types of surgical intervention (eg, femoral vs femoral triangle blocks for ACL repair, optimal analgesic modality for posterior knee pain after TKR). Although postoperative pain should never be neglected, future studies should also investigate “big” outcomes. For example, femoral triangle/adductor canal blocks are currently widely used for knee surgery. Considering the fact these blocks are not devoid of complications (eg, local anesthesia–related myotoxicity), large prospective studies are required to determine if, beyond preservation of quadriceps strength, they can actually translate into concrete benefits such as a decreased incidence of patient fall or improved rehabilitation. Similarly, the contributive and mechanistic roles of femoral blockade in long-term quadriceps dysfunction after ACL repair require further investigation.

In conclusion, the last 13 years could be construed as the beginning of a “Golden Age” for lower extremity regional anesthesia. Multiple well-conducted studies have appeared in

the literature, broadening our collective understanding of the anatomy, methods/techniques, pharmacology, and outcomes pertaining to lower extremity nerve blocks. More importantly, these trials have also highlighted areas in dire need of further investigation. The authors are convinced that, with the (future) third iteration of this review article, multiple questions raised in the preceding pages will have found answers and multiple new queries will see the light of day.

**Acknowledgements** The first author would like to thank Dr Daniela Bravo (University of Chile) for her invaluable assistance with the literature search pertaining to the Outcomes section.

**Competing interests** None declared.

## REFERENCES

- Enneking FK, Chan V, Greger J, et al. Lower-extremity peripheral nerve blockade: essentials of our current understanding. *Reg Anesth Pain Med* 2005;30:4–35.
- Williams A, Newell RLM, Davies MS, et al. Pelvic girdle and lower limb. In: Standring S, Ellis H, Healy JC, et al, eds. *Gray's anatomy—the anatomical basis of clinical practice*. 39th edn. Philadelphia, PA: Elsevier Churchill Livingstone, 2005.
- Farny J, Drolet P, Girard M. Anatomy of the posterior approach to the lumbar plexus block. *Can J Anaesth* 1994;41:480–5.
- Awad IT, Duggan EM. Posterior lumbar plexus block: anatomy, approaches, and techniques. *Reg Anesth Pain Med* 2005;30:143–9.
- Lu S, Chang S, Zhang Y-zhi, et al. Clinical anatomy and 3D virtual reconstruction of the lumbar plexus with respect to lumbar surgery. *BMC Musculoskelet Disord* 2011;12:76.
- Sim IW, Webb T. Anatomy and anaesthesia of the lumbar somatic plexus. *Anaesth Intensive Care* 2004;32:178–87.
- Karmakar MK, Li JW, Kwok WH, et al. Sonoanatomy relevant for lumbar plexus block in volunteers correlated with cross-sectional images and magnetic resonance imaging. *Reg Anesth Pain Med* 2013;38:391–7.
- Kirchmair L, Lirk P, Colvin J, et al. Lumbar plexus and psoas major muscle: not always as expected. *Reg Anesth Pain Med* 2008;33:109114.
- Mannion S, Barrett J, Kelly D, et al. A description of the spread of injectate after psoas compartment block using magnetic resonance imaging. *Reg Anesth Pain Med* 2005;30:567–71.
- Capdevila X, Macaire P, Dadure C, et al. Continuous psoas compartment block for postoperative analgesia after total hip arthroplasty: new landmarks, technical guidelines, and clinical evaluation. *Anesth Analg* 2002;94:1606–13.
- Ilfeld BM, Loland VJ, Mariano ER. Prepuncture ultrasound imaging to predict transverse process and lumbar plexus depth for psoas compartment block and perineural catheter insertion: a prospective, observational study. *Anesth Analg* 2010;110:1725–8.
- Short AJ, Barnett JGG, Gofeld M, et al. Anatomic study of the anterior hip capsule: implication for image-guided intervention. *Reg Anesth Pain Med* 2018;43:186–92.
- Birnbaum K, Prescher A, Heßler S, et al. The sensory innervation of the hip joint—an anatomical study. *Surg Radiol Anat* 1997;19:371–5.
- Bendtsen TF, Moriggl B, Chan V, et al. The optimal analgesic block for total knee arthroplasty. *Reg Anesth Pain Med* 2016;41:711–9.
- Wong WY, Björn S, Strid JMC, et al. Defining the location of the adductor canal using ultrasound. *Reg Anesth Pain Med* 2017;42:241–5.
- Vloka JD, Hadzic A, Drobnik L, et al. Anatomical landmarks for femoral nerve block: a comparison of four needle insertion sites. *Anesth Analg* 1999;89:1467–70.
- Ty Muhly W, Orebaugh SL. Ultrasound evaluation of the anatomy of the vessels in relation to the femoral nerve at the femoral crease. *Surg Radiol Anat* 2011;33:491–4.
- Gustafson KJ, Pinault GJC, Neville JJ, et al. Fascicular anatomy of human femoral nerve: implications for neural prostheses using nerve cuff electrodes. *J Rehabil Res Dev* 2009;46:973–84.
- Nader A, Malik K, Kendall MC, et al. Relationship between ultrasound imaging and eliciting motor response during femoral nerve blockade. *J Ultrasound Med* 2009;28:345–50.
- Lonchena TK, McFadden K, Orebaugh SL. Correlation of ultrasound appearance, gross anatomy, and histology of the femoral nerve at the femoral triangle. *Surg Radiol Anat* 2016;38:115–22.
- Ishiguro S, Yokochi A, Yoshioka K, et al. Anatomy and clinical implications of ultrasound-guided selective femoral nerve block. *Anesth Analg* 2012;115:1467–70.
- Andersen HL, Andersen SL, Trantum-Jensen J. The spread of injectate during saphenous nerve block at the adductor canal: a cadaver study. *Acta Anaesthesiol Scand* 2015;59:238–45.
- Tubbs RS, Loukas M, Shoja MM, et al. Anatomy and potential clinical significance of the vastoadductor membrane. *Surg Radiol Anat* 2007;29:569–73.
- Runge C, Moriggl B, Børglum J, et al. The spread of ultrasound-guided injectate from the adductor canal to the genicular branch of the posterior obturator nerve and the popliteal fossa: a cadaver study. *Reg Anesth Pain Med* 2017;42:725–30.
- Burckett-St Laurant D, Peng P, Girón Arango L, et al. The nerves of the adductor canal and the innervation of the knee. *Reg Anesth Pain Med* 2016;41:321–7.
- Horner G, Dellon AL. Innervation of the human knee joint and implications for surgery. *Clin Orthop Relat Res* 1994;301:221–6.
- Kennedy JC, Alexander JJ, Hayes KC. Nerve supply of the human knee and its functional importance. *Am J Sports Med* 1982;10:329–35.
- Saranteas T, Anagnostis G, Paraskeuopoulos T, et al. Anatomy and clinical implications of the ultrasound-guided subsartorial saphenous nerve block. *Reg Anesth Pain Med* 2011;36:399–402.
- Horn J-L, Pitsch T, Salinas F, et al. Anatomic basis to the ultrasound-guided approach for saphenous nerve blockade. *Reg Anesth Pain Med* 2009;34:486–9.
- Lundblad M, Kapral S, Marhofer P, et al. Ultrasound-guided infrapatellar nerve block in human volunteers: description of a novel technique †. *Br J Anaesth* 2006;97:710–4.
- Mentzel M, Fleischmann W, Bauer G, et al. Ankle joint denervation. Part 1: anatomy—the sensory innervation of the ankle joint. *Foot and Ankle Surg* 1999;5:15–20.
- Eglitis N, Horn J-L, Benninger B, et al. The importance of the saphenous nerve in ankle surgery. *Anesth Analg* 2016;122:1704–6.
- Mercer D, Morrell NT, Fitzpatrick J, et al. The course of the distal saphenous nerve: a cadaveric investigation and clinical implications. *Iowa Orthop J* 2011;31:231–5.
- López AM, Sala-Blanch X, Magaldi M, et al. Ultrasound-guided ankle block for forefoot surgery: the contribution of the saphenous nerve. *Reg Anesth Pain Med* 2012;37:554–7.
- Marsland D, Dray A, Little NJ, et al. The saphenous nerve in foot and ankle surgery: its variable anatomy and relevance. *Foot Ankle Surg* 2013;19:76–9.
- Anagnostopoulou S, Kostopanagioutou G, Paraskeuopoulos T, et al. Anatomic variations of the obturator nerve in the inguinal region: implications in conventional and ultrasound regional anesthesia techniques. *Reg Anesth Pain Med* 2009;34:33–9.
- Nielsen TD, Moriggl B, Søballe K, et al. A cadaveric study of subpectineal spread around the obturator nerve and its hip articular branches. *Reg Anesth Pain Med* 2017;42:357–61.
- Bouaziz H, Vial F, Jochum D, et al. An evaluation of the cutaneous distribution after obturator nerve block. *Anesth Analg* 2002;94:445–9.
- Gardner E. The innervation of the knee joint. *Anat Rec* 1948;101:109–30.
- Akkaya T, Comert A, Kendir S, et al. Detailed anatomy of accessory obturator nerve blockade. *Minerva Anesthesiol* 2008;74:119–22.
- Katritsis E, Anagnostopoulou S, Papadopoulos N. Anatomical observations on the accessory obturator nerve (based on 1000 specimens). *Anat Anz* 1980;148:440–5.
- Corujo A, Franco CD, Williams JM. The sensory territory of the lateral cutaneous nerve of the thigh as determined by anatomic dissections and ultrasound-guided blocks. *Reg Anesth Pain Med* 2012;37:561–4.
- Majkrzak A, Johnston J, Kacey D, et al. Variability of the lateral femoral cutaneous nerve: an anatomic basis for planning safe surgical approaches. *Clin Anat* 2010;23:NA.
- Ray B, D'Souza AS, Kumar B, et al. Variations in the course and microanatomical study of the lateral femoral cutaneous nerve and its clinical importance. *Clin Anat* 2010;23:978–84.
- Doklamyay P, Agthong S, Chentanez V, et al. Anatomy of the lateral femoral cutaneous nerve related to inguinal ligament, adjacent bony landmarks, and femoral artery. *Clin Anat* 2008;21:769–74.
- Carai A, Fenu G, Sechi E, et al. Anatomical variability of the lateral femoral cutaneous nerve: findings from a surgical series. *Clin Anat* 2009;22:365–70.
- O'Connor M, Coleman M, Wallis F, et al. An anatomical study of parasacral block using magnetic resonance imaging of healthy volunteers. *Anesth Analg* 2009;108:1708–12.
- Wertheimer LG. The sensory nerves of the hip joint. *J Bone Joint Surg Am* 1952;34:477–87.
- Sunderland S, Ray LJ. The intraneural topography of the sciatic nerve and its popliteal divisions in man. *Brain* 1948;71:242–73.
- Sladjana UZ, Ivan JD, Bratislav SD. Microanatomical structure of the human sciatic nerve. *Surg Radiol Anat* 2008;30:619–26.
- Ugrenovic S, Topalovic M, Jonanovic I. Morphological and morphometric analysis of fascicular structure of tibial and common peroneal nerves. *Medicine and Biology* 2014;16:18–22.
- Franco CD. Posterior approach to the sciatic nerve in adults: is Euclidean geometry still necessary? *Anesthesiology* 2003;98:723–8.
- Karmakar MK, Kwok WH, Ho AM, et al. Ultrasound-guided sciatic nerve block: description of a new approach at the subgluteal space. *Br J Anaesth* 2007;98:390–5.
- Currin SS, Mirjalili SA, Meikle G, et al. Revisiting the surface anatomy of the sciatic nerve in the gluteal region. *Clin Anat* 2015;28:144–9.

- 55 Sukhani R, Candido KD, Doty R, *et al.* Infragluteal-parabiceps sciatic nerve block: an evaluation of a novel approach using a single-injection technique. *Anesth Analg* 2003;96:868–73.
- 56 Bruhn J, Moayeri N, Groen GJ, *et al.* Soft tissue landmark for ultrasound identification of the sciatic nerve in the infragluteal region: the tendon of the long head of the biceps femoris muscle. *Acta Anaesthesiol Scand* 2009;53:921–5.
- 57 Moayeri N, van Geffen GJ, Bruhn J, *et al.* Correlation among ultrasound, cross-sectional anatomy, and histology of the sciatic nerve: a review. *Reg Anesth Pain Med* 2010;35:442–9.
- 58 Bruhn J, van Geffen GJ, Gielen MJ, *et al.* Visualization of the course of the sciatic nerve in adult volunteers by ultrasonography. *Acta Anaesthesiol Scand* 2008;52:1298–302.
- 59 Gustafson KJ, Grinberg Y, Joseph S, *et al.* Human distal sciatic nerve fascicular anatomy: implications for ankle control using nerve-cuff electrodes. *J Rehabil Res Dev* 2012;49:309–22.
- 60 Barrington MJ, Lai S-LK, Briggs CA, *et al.* Ultrasound-guided midhigh sciatic nerve block—a clinical and anatomical study. *Reg Anesth Pain Med* 2008;33:369–76.
- 61 Vloka JD, Hadžić A, April E, *et al.* The division of the sciatic nerve in the popliteal fossa: anatomical implications for popliteal nerve blockade. *Anesth Analg* 2001;92:215–7.
- 62 Benzon HT, Kim C, Benzon HP, *et al.* Correlation between evoked motor response of the sciatic nerve and sensory blockade. *Anesthesiology* 1997;87:547–52.
- 63 Doty R, Sukhani R, Kendall MC, *et al.* Evaluation of a proximal block site and the use of nerve-stimulator-guided needle placement for posterior tibial nerve block. *Anesth Analg* 2006;103:1300–5.
- 64 Flanagan RM, DiGiovanni BF. Peripheral nerve entrapments of the lower leg, ankle, and foot. *Foot Ankle Clin* 2011;16:255–74.
- 65 Zhu J, Li D, Shao J, *et al.* An ultrasound study of anatomic variants of the sural nerve. *Muscle Nerve* 2011;43:560–2.
- 66 Johnson CS, Johnson RL, Niesen AD, *et al.* Ultrasound-guided posterior femoral cutaneous nerve block. *J Ultrasound Med* 2018;37:897–903.
- 67 Meng S, Lieba-Samal D, Reissig LF, *et al.* High-resolution ultrasound of the posterior femoral cutaneous nerve: visualization and initial experience with patients. *Skeletal Radiol* 2015;44:1421–6.
- 68 Reina MA, De Andres JA, Hernandez-Garcia JM, *et al.* Successive changes in extraneural structures from the subarachnoid nerve roots to the peripheral nerve, influencing anesthetic block, and treatment of acute postoperative pain. *Eur J Pain* 2011;55:377–85.
- 69 Sala-Blanch X, Vandepitte C, Laur JJ. A practical review of perineural versus intraneural injections: a call for standard nomenclature. *Int Anesthesiol Clin* 2011;49:44–55.
- 70 Choquet O, Capdevila X. Ultrasound-guided nerve blocks: the real position of the needle should be defined. *Anesth Analg* 2012;114:929–30.
- 71 Franco CD. Connective tissues associated with peripheral nerves. *Reg Anesth Pain Med* 2012;37:363–5.
- 72 Andersen HL, Andersen SL, Tranum-Jensen J. Injection inside the paraneural sheath of the sciatic nerve: direct comparison among ultrasound imaging, macroscopic anatomy, and histologic analysis. *Reg Anesth Pain Med* 2012;37:410–4.
- 73 Karmakar MK, Shariat AN, Pangthipampai P, *et al.* High-definition ultrasound imaging defines the paraneural sheath and the fascial compartments surrounding the sciatic nerve at the popliteal fossa. *Reg Anesth Pain Med* 2013;38:447–51.
- 74 Moayeri N, Groen GJ. Differences in quantitative architecture of sciatic nerve may explain differences in potential vulnerability to nerve injury, onset time, and minimum effective anesthetic volume. *Anesthesiology* 2009;111:1128–34.
- 75 Hogan Q. Finding nerves is not simple. *Reg Anesth Pain Med* 2003;28:367–71.
- 76 Chelly JE, Casati A, Al-Samsam T, *et al.* Continuous lumbar plexus block for acute postoperative pain management after open reduction and internal fixation of acetabular fractures. *J Orthop Trauma* 2003;17:362–7.
- 77 Mouzopoulos G, Vasiliadis G, Lasanianos N, *et al.* Fascia iliaca block prophylaxis for hip fracture patients at risk for delirium: a randomized placebo-controlled study. *J Orthop Traumatol* 2009;10:127–33.
- 78 Foss NB, Kristensen BB, Bundgaard M, *et al.* Fascia iliaca compartment blockade for acute pain control in hip fracture patients: a randomized, placebo-controlled trial. *Anesthesiology* 2007;106:773–8.
- 79 Winnie AP, Ramamurthy S, Durani Z. Plexus blocks for lower extremity surgery: new answers to old problems. *Anesth Rev* 1974;1:1–6.
- 80 Chayen D, Nathan H, Chayen M. The psoas compartment block. *Anesthesiology* 1976;45:95–9.
- 81 Parkinson SK, Mueller JB, Little WL, *et al.* Extent of blockade with various approaches to the lumbar plexus. *Anesth Analg* 1989;68:243–8.
- 82 Winnie AP, Ramamurthy S, Durrani Z. The inguinal paravascular technic of lumbar plexus anesthesia: the "3-in-1 block". *Anesth Analg* 1973;52:989–96.
- 83 Tokat O, Türker YG, Uckunkaya N, *et al.* A clinical comparison of psoas compartment and inguinal paravascular blocks combined with sciatic nerve block. *J Int Med Res* 2002;30:161–7.
- 84 Ali AM, Tahoun HM, Ahmed AA. Comparative study between the analgesic efficacies of nerve stimulator-guided 3-in-1 block, ultrasonographic-guided 3-in-1 block and posterior approach lumbar plexus block following total hip arthroplasty. *Eg J Anaesth* 2003;19:39–43.
- 85 Ganidağlı S, Cengiz M, Baysal Z, *et al.* The comparison of two lower extremity block techniques combined with sciatic block: 3-in-1 femoral block vs. psoas compartment block. *Int J Clin Pract* 2005;59:771–6.
- 86 Cappelleri G, Aldegheri G, Ruggieri F, *et al.* Effects of using the posterior or anterior approaches to the lumbar plexus on the minimum effective anesthetic concentration (MEAC) of mepivacaine required to block the femoral nerve: a prospective, randomized, up-and-down study. *Reg Anesth Pain Med* 2008;33:10–16.
- 87 Biboulet P, Morau D, Aubas P, *et al.* Postoperative analgesia after total-hip arthroplasty: comparison of intravenous patient-controlled analgesia with morphine and single injection of femoral nerve or psoas compartment block. A prospective, randomized, double-blind study. *Reg Anesth Pain Med* 2004;29:102–9.
- 88 Morin AM, Kratz CD, Eberhart LH, *et al.* Postoperative analgesia and functional recovery after total-knee replacement: comparison of a continuous posterior lumbar plexus (psoas compartment) block, a continuous femoral nerve block, and the combination of a continuous femoral and sciatic nerve block. *Reg Anesth Pain Med* 2005;30:434–45.
- 89 Kaloul I, Guay J, Côté C, *et al.* The posterior lumbar plexus (psoas compartment) block and the three-in-one femoral nerve block provide similar postoperative analgesia after total knee replacement. *Can J Anesth* 2004;51:45–51.
- 90 Marhofer P, Našel C, Sitzwohl C, *et al.* Magnetic resonance imaging of the distribution of local anesthetic during the three-in-one block. *Anesth Analg* 2000;90:119–24.
- 91 Spillane WF. 3-in-1 blocks and continuous 3-in-1 blocks. *Reg Anesth* 1992;17:175–6.
- 92 Dalens B, Tanguy A, Vanneville G. Lumbar plexus block in children: a comparison of two procedures in 50 patients. *Anesth Analg* 1988;67:750–8.
- 93 Mannion S, O'Callaghan S, Walsh M, *et al.* In with the new, out with the old? Comparison of two approaches for psoas compartment block. *Anesth Analg* 2005;101:259–64.
- 94 Danelli G, Ghisi D, Bellinghieri F, *et al.* The nerve stimulation technique versus the loss of resistance technique for the posterior approach to lumbar plexus block: a randomized, prospective, observer-blinded, pilot study. *Minerva Anestesiol* 2011;77:959–63.
- 95 Gadsden JC, Lindenmuth DM, Hadžić A, *et al.* Lumbar plexus block using high-pressure injection leads to contralateral and epidural spread. *Anesthesiology* 2008;109:683–8.
- 96 Karmakar MK, Ho AM-H, Li X, *et al.* Ultrasound-guided lumbar plexus block through the acoustic window of the lumbar ultrasound trident. *Br J Anaesth* 2008;100:533–7.
- 97 Karmakar MK, Li JW, Kwok WH, *et al.* Ultrasound-guided lumbar plexus block using a transverse scan through the lumbar intertransverse space: a prospective case series. *Reg Anesth Pain Med* 2015;40:75–81.
- 98 Lin JA, Lu HT. Solution to the challenging part of the Shamrock method during lumbar plexus block. *Br J Anaesth* 2014;113:516–7.
- 99 Strid JMC, Sauter AR, Ullensvang K, *et al.* Ultrasound-guided lumbar plexus block in volunteers: a randomized controlled trial. *Br J Anaesth* 2017;118:430–8.
- 100 Arunatasupakul V, Chalachewa T, Leurcharusmee P, *et al.* Ultrasound with neurostimulation compared with ultrasound guidance alone for lumbar plexus block. *Eur J Anaesthesiol* 2018;35:224–30.
- 101 Dauri M, Sidiropoulou T, Fabbri E, *et al.* Efficacy of continuous femoral nerve block with stimulating catheters versus nonstimulating catheters for anterior cruciate ligament reconstruction. *Reg Anesth Pain Med* 2007;32:282–7.
- 102 Schiferer A, Gore C, Gorove L, *et al.* A randomized controlled trial of femoral nerve blockade administered preclinically for pain relief in femoral trauma. *Anesth Analg* 2007;105:1852–4.
- 103 Casati A, Fanelli G, Beccaria P, *et al.* The effects of the single or multiple injection technique on the onset time of femoral nerve blocks with 0.75% ropivacaine. *Anesth Analg* 2000;91:181–4.
- 104 Casati A, Fanelli G, Beccaria P, *et al.* The effects of single or multiple injections on the volume of 0.5% ropivacaine required for femoral nerve blockade. *Anesth Analg* 2001;93:183–6.
- 105 Anns JP, Chen EW, Nirkavan N, *et al.* A comparison of sartorius versus quadriceps stimulation for femoral nerve block: a prospective randomized double-blind controlled trial. *Anesth Analg* 2011;112:725–31.
- 106 Casati A, Baciarello M, Cianni SD, *et al.* Effects of ultrasound guidance on the minimum effective anaesthetic volume required to block the femoral nerve. *Br J Anaesth* 2007;98:823–7.
- 107 Sites BD, Beach ML, Chinn CD, *et al.* A comparison of sensory and motor loss after a femoral nerve block conducted with ultrasound versus ultrasound and nerve stimulation. *Reg Anesth Pain Med* 2009;34:508–13.
- 108 Hirst GC, Lang SA, Dust WN, *et al.* Femoral nerve block. Single injection versus continuous infusion for total knee arthroplasty. *Reg Anesth* 1996;21:292–7.
- 109 Marhofer P, Schrogendorfer K, Koinig H, *et al.* Ultrasonographic guidance improves sensory block and onset time of three-in-one blocks. *Anesth Analg* 1997;85:854–7.



- 110 Marhofer P, Schrögenderfer K, Wallner T, et al. Ultrasonographic guidance reduces the amount of local anesthetic for 3-in-1 blocks. *Reg Anesth Pain Med* 1998;23:584–8.
- 111 Dalens B, Vanneville G, Tanguy A. Comparison of the fascia iliaca compartment block with the 3-in-1 block in children. *Anesth Analg* 1989;69:705–13.
- 112 Capdevila X, Biboulet P, Bouregba M, et al. Comparison of the three-in-one and fascia iliaca compartment blocks in adults: clinical and radiographic analysis. *Anesth Analg* 1998;86:1039–44.
- 113 Dolan J, Williams A, Murney E, et al. Ultrasound guided fascia iliaca block: a comparison with the loss of resistance technique. *Reg Anesth Pain Med* 2008;33:526–31.
- 114 Tumber PS, Bhatia A, Chan VW. Ultrasound-guided lateral femoral cutaneous nerve block for meralgia paresthetica. *Anesth Analg* 2008;106:1021–2.
- 115 Shannon J, Lang SA, Yip RW, et al. Lateral femoral cutaneous nerve block revisited. A nerve stimulator technique. *Reg Anesth* 1995;20:100–4.
- 116 Ng I, Vaghadia H, Choi PT, et al. Ultrasound imaging accurately identifies the lateral femoral cutaneous nerve. *Anesth Analg* 2008;107:1070–4.
- 117 Gupta G, Radhakrishna M, Tamblin I, et al. A randomized comparison between neurostimulation and ultrasound-guided lateral femoral cutaneous nerve block. *US Army Med Dep J* 2017;(2-17):33–8.
- 118 Hara K, Sakura S, Shido A. Ultrasound-guided lateral femoral cutaneous nerve block: comparison of two techniques. *Anaesth Intensive Care* 2011;39:69–72.
- 119 Macalou D, Trueck S, Meuret P, et al. Postoperative analgesia after total knee replacement: the effect of an obturator nerve block added to the femoral 3-in-1 nerve block. *Anesth Analg* 2004;99:251–4.
- 120 Choquet O, Capdevila X, Bennourine K, et al. A new inguinal approach for the obturator nerve block: anatomical and randomized clinical studies. *Anesthesiology* 2005;103:1238–45.
- 121 Fujiwara Y, Sato Y, Kitayama M, et al. Obturator nerve block using ultrasound guidance. *Anesth Analg* 2007;105:888–9.
- 122 Helayel PE, da Conceição DB, Pavei P, et al. Ultrasound-guided obturator nerve block: a preliminary report of a case series. *Reg Anesth Pain Med* 2007;32:221–6.
- 123 Manassero A, Bossolasco M, Ugues S, et al. Ultrasound-guided obturator nerve block: interfacial injection versus a neurostimulation-assisted technique. *Reg Anesth Pain Med* 2012;37:67–71.
- 124 Taha AM. Brief reports: ultrasound-guided obturator nerve block: a proximal interfacial technique. *Anesth Analg* 2012;114:236–9.
- 125 De Mey J-CJ, Deruyck LJ, Cammu G, et al. A paravenous approach for the saphenous nerve block. *Reg Anesth Pain Med* 2001;26:504–6.
- 126 van der Wal M, Lang SA, Yip RW. Transartorial approach for saphenous nerve block. *Can J Anesth* 1993;40:542–6.
- 127 Comfort VK, Lang SA, Yip RW. Saphenous nerve anaesthesia—a nerve stimulator technique. *Can J Anesth* 1996;43:852–7.
- 128 Benzou HT, Sharma S, Calimaran A. Comparison of the different approaches to saphenous nerve block. *Anesthesiology* 2005;102:633–8.
- 129 Kent ML, Hackworth RJ, Riffenburgh RH, et al. A comparison of ultrasound-guided and landmark-based approaches to saphenous nerve blockade: a prospective, controlled, blinded, crossover trial. *Anesth Analg* 2013;117:265–70.
- 130 Marian AA, Ranganath Y, Bayman EO, et al. A comparison of 2 ultrasound-guided approaches to the saphenous nerve block: adductor canal versus distal transartorial: a prospective, randomized, blinded, noninferiority trial. *Reg Anesth Pain Med* 2015;40:623–30.
- 131 Montgomery SH, Shamji CM, Yi GS, et al. Effect of nerve stimulation use on the success rate of ultrasound-guided subsartorial saphenous nerve block: a randomized controlled trial. *Reg Anesth Pain Med* 2017;42:25–31.
- 132 Andersen HL, Gyrn J, Møller L, et al. Continuous saphenous nerve block as supplement to single-dose local infiltration analgesia for postoperative pain management after total knee arthroplasty. *Reg Anesth Pain Med* 2013;38:106–11.
- 133 Jenstrup MT, Jaeger P, Lund J, et al. Effects of adductor-canal-blockade on pain and ambulation after total knee arthroplasty: a randomized study. *Acta Anaesthesiol Scand* 2012;56:357–64.
- 134 Jaeger P, Nielsen ZJ, Henningsen MH, et al. Adductor canal block versus femoral nerve block and quadriceps strength: a randomized, double-blind, placebo-controlled, crossover study in healthy volunteers. *Anesthesiology* 2013;118:409–15.
- 135 Mariano ER, Kim TE, Wagner MJ, et al. A randomized comparison of proximal and distal ultrasound-guided adductor canal catheter insertion sites for knee arthroplasty. *J Ultrasound Med* 2014;33:1653–62.
- 136 Meier AW, Auyong DB, Yuan SC, et al. Comparison of continuous proximal versus distal adductor canal blocks for total knee arthroplasty. *Reg Anesth Pain Med* 2018;43:36–42.
- 137 Cappelleri G, Ghisi D, Ceravola E, et al. A randomised controlled comparison between stimulating and standard catheters for lumbar plexus block. *Anaesthesia* 2015;70:948–55.
- 138 Morau D, Lopez S, Biboulet P, et al. Comparison of continuous 3-in-1 and fascia iliaca compartment blocks for postoperative analgesia: feasibility, catheter migration, distribution of sensory block, and analgesic efficacy. *Reg Anesth Pain Med* 2003;28:309–14.
- 139 Brisbane Orthopaedic & Sports Medicine Centre Writing Committee, McMeniman TJ, McMeniman PJ, et al. Femoral nerve block vs fascia iliaca block for total knee arthroplasty postoperative pain control: a prospective, randomized controlled trial. *J Arthroplasty* 2010;25:1246–9.
- 140 Fredrickson MJ, Danesh-Clough TK. Ambulatory continuous femoral analgesia for major knee surgery: a randomised study of ultrasound-guided femoral catheter placement. *Anaesth Intensive Care* 2009;37:758–66.
- 141 Farag E, Atim A, Ghosh R, et al. Comparison of three techniques for ultrasound-guided femoral nerve catheter insertion. *Anesthesiology* 2014;121:239–48.
- 142 Salinas FV, Neal JM, Sueda LA, et al. Prospective comparison of continuous femoral nerve block with nonstimulating catheter placement versus stimulating catheter-guided perineural placement in volunteers. *Reg Anesth Pain Med* 2004;29:212–20.
- 143 Hayek SM, Ritchey RM, Sessler D, et al. Continuous femoral nerve analgesia after unilateral total knee arthroplasty: stimulating versus nonstimulating catheters. *Anesth Analg* 2006;103:1565–70.
- 144 Barrington MJ, Olive DJ, McCutcheon CA, et al. Stimulating catheters for continuous femoral nerve blockade after total knee arthroplasty: a randomized, controlled, double-blinded trial. *Anesth Analg* 2008;106:1316–21.
- 145 Morin AM, Eberhart LHJ, Benkhe HKE, et al. Does femoral nerve catheter placement with stimulating catheters improve effective placement? A randomized, controlled, and observer-blinded trial. *Anesth Analg* 2005;100:1503–10.
- 146 Gandhi K, Lindenmuth DM, Hadzic A, et al. The effect of stimulating versus conventional perineural catheters on postoperative analgesia following ultrasound-guided femoral nerve localization. *J Clin Anesth* 2011;23:626–31.
- 147 Aveline C, Le Roux A, Le Hetet H, et al. Postoperative efficacies of femoral nerve catheters sited using ultrasound combined with neurostimulation compared with neurostimulation alone for total knee arthroplasty. *Eur J Anaesthesiol* 2010;27:978–84.
- 148 Li M, Xu T, Han WY, et al. Use of ultrasound to facilitate femoral nerve block with stimulating catheter. *Chin Med J* 2011;124:519–24.
- 149 Mariano ER, Loland VJ, Sandhu NS, et al. Ultrasound guidance versus electrical stimulation for femoral perineural catheter insertion. *J Ultrasound Med* 2009;28:1453–60.
- 150 Kim H-Y, Byeon G-J, Cho H-J, et al. A comparison of ultrasound alone vs ultrasound with nerve stimulation guidance for continuous femoral nerve block in patients undergoing total knee arthroplasty. *J Clin Anesth* 2016;32:274–80.
- 151 Wang A-Z, Gu L, Zhou Q-H, et al. Ultrasound-guided femoral nerve block for analgesia after total knee arthroplasty. *Reg Anesth Pain Med* 2010;35:127–31.
- 152 Mariano ER, Kim TE, Funck N, et al. A randomized comparison of long- and short-axis imaging for in-plane ultrasound-guided femoral perineural catheter insertion. *J Ultrasound in Medicine* 2013;32:149–56.
- 153 Ilfeld BM, Loland VJ, Sandhu NS, et al. Continuous femoral nerve blocks: the impact of catheter tip location relative to the femoral nerve (anterior versus posterior) on quadriceps weakness and cutaneous sensory block. *Anesth Analg* 2012;115:721–7.
- 154 Wegener JT, van Ooij B, van Dijk CN, et al. Value of single-injection or continuous sciatic nerve block in addition to a continuous femoral nerve block in patients undergoing total knee arthroplasty. *Reg Anesth Pain Med* 2011;36:481–8.
- 155 Ilfeld BM, Morey TE, Wang RD, et al. Continuous popliteal sciatic nerve block for postoperative pain control at home. *Anesthesiology* 2002;97:959–65.
- 156 Cooper J, Benirschke S, Sangeorzan B, et al. Sciatic Nerve Blockade Improves Early Postoperative Analgesia After Open Repair of Calcaneus Fractures. *J Orthop Trauma* 2004;18:197–201.
- 157 Hunt KJ, Higgins TF, Carlston CV, et al. Continuous peripheral nerve blockade as postoperative analgesia for open treatment of calcaneal fractures. *J Orthop Trauma* 2010;24:148–55.
- 158 Mansour NY. Reevaluating the sciatic nerve block: another landmark for consideration. *Reg Anesth* 1993;18:322–3.
- 159 Cuvillon P, Ripart J, Jeannes P, et al. Comparison of the parasacral approach and the posterior approach, with single- and double-injection techniques, to block the sciatic nerve. *Anesthesiology* 2003;98:1436–41.
- 160 di Benedetto P, Bertini L, Casati A, et al. A new posterior approach to the sciatic nerve block: a prospective, randomized comparison with the classic posterior approach. *Anesth Analg* 2001;93:1040–4.
- 161 Taboada M, Alvarez J, Cortes J, et al. The Effects of Three Different Approaches on the Onset Time of Sciatic Nerve Blocks with 0.75% Ropivacaine. *Anesth Analg* 2004;98:242–7.
- 162 Fuzier R, Fuzier V, Albert N, et al. The sciatic nerve block in emergency settings: a comparison between a new anterior and the classic lateral approaches. *Med Sci Monit* 2004;10:CR563–7.
- 163 Amin WA, Abou Seada MO, Saeed MF, et al. Continuous sciatic nerve block: comparative study between the parasacral, lateral, and anterior approaches for lower limb surgery. *M E J Anesth* 2010;20:695–702.
- 164 Ota J, Sakura S, Hara K, et al. Ultrasound-guided anterior approach to sciatic nerve block: a comparison with the posterior approach. *Anesth Analg* 2009;108:660–5.
- 165 Dalens B, Tanguy A, Vanneville G. Sciatic nerve blocks in children: comparison of the posterior, anterior, and lateral approaches in 180 pediatric patients. *Anesth Analg* 1990;70:131–7.

- 166 Hagon BS, Itani O, Bidgoli JH, *et al.* Parasacral sciatic nerve block: does the elicited motor response predict the success rate? *Anesth Analg* 2007;105:263–6.
- 167 Taboada M, Atanassoff PG, Rodriguez J, *et al.* Plantar flexion seems more reliable than dorsiflexion with Labat's sciatic nerve block: a prospective, randomized comparison. *Anesth Analg* 2005;100:250–4.
- 168 Sukhani R, Nader A, Candido KD, *et al.* Nerve stimulator-assisted evoked motor response predicts the latency and success of a single-injection sciatic block. *Anesth Analg* 2004;99:584–8.
- 169 Nader A, Doty R, Brodskaja A, *et al.* Sensory testing of distal sural and posterior tibial nerves provides early prediction of surgical anesthesia after single-injection infragluteal-parabiceps sciatic nerve block. *Anesth Analg* 2010;110:951–7.
- 170 Bailey SL, Parkinson SK, Little WL, *et al.* Sciatic nerve block. A comparison of single versus double injection technique. *Reg Anesth* 1994;19:9–13.
- 171 Taboada M, Alvarez J, Cortes J, *et al.* Is a double-injection technique superior to a single injection in posterior subgluteal sciatic nerve block? *Acta Anaesthesiol Scand* 2004;48:883–7.
- 172 Wadhwa A, Tlucek H, Sessler D. A simple approach to the sciatic nerve that does not require geometric calculations or multiple landmarks. *Anesth Analg* 2010;110:958–63.
- 173 Van Elstraete A, Poey C, Lebrun T, *et al.* New landmarks for the anterior approach to the sciatic nerve block: imaging and clinical study. *Anesth Analg* 2002;95:214–8.
- 174 Taboada M, Rodriguez J, Del Rio S, *et al.* Does the site of injection distal to the greater trochanter make a difference in lateral sciatic nerve blockade? *Anesth Analg* 2005;101:1188–91.
- 175 Danelli G, Ghisi D, Fanelli A, *et al.* The effects of ultrasound guidance and neurostimulation on the minimum effective anesthetic volume of mepivacaine 1.5% required to block the sciatic nerve using the subgluteal approach. *Anesth Analg* 2009;109:1674–8.
- 176 Domingo-Triado V, Sella S, Martinez F, *et al.* Ultrasound guidance for lateral midfemoral sciatic nerve block: a prospective, comparative, randomized study. *Anesthesia & Analgesia* 2007;104:1270–4.
- 177 Yamamoto H, Sakura S, Wada M, *et al.* A prospective, randomized comparison between single- and multiple-injection techniques for ultrasound-guided subgluteal sciatic nerve block. *Anesth Analg* 2014;119:1442–8.
- 178 Abdallah FW, Chan VW, Koshkin A, *et al.* Ultrasound-guided sciatic nerve block in overweight and obese patients. *Reg Anesth Pain Med* 2013;38:547–52.
- 179 Kilpatrick AWA, Coventry DM, Todd JG. A comparison of two approaches to sciatic nerve block. *Anaesthesia* 1992;47:155–7.
- 180 Fuzier R, Hoffreumont P, Bringuier-Brancheau S, *et al.* Does the sciatic nerve approach influence thigh tourniquet tolerance during below-knee surgery? *Anesth Analg* 2005;100:1511–4.
- 181 Taboada M, Rodriguez J, Alvarez J, *et al.* Sciatic nerve block via posterior Labat approach is more efficient than lateral popliteal approach using a double-injection technique. *Anesthesiology* 2004;101:138–42.
- 182 Cappelleri G, Aldegheri G, Ruggieri F, *et al.* Minimum effective anesthetic concentration (MEAC) for sciatic nerve block: subgluteus and popliteal approaches. *Can J Anesth* 2007;54:283–9.
- 183 Taboada M, Rodriguez J, Valino C, *et al.* What is the minimum effective volume of local anesthetic required for sciatic nerve blockade? A prospective, randomized comparison between a popliteal and a subgluteal approach. *Anesth Analg* 2006;102:593–7.
- 184 Triadó VD, Crespo MT, Aguilar JL, *et al.* A comparison of lateral popliteal versus lateral midfemoral sciatic nerve blockade using ropivacaine 0.5%. *Reg Anesth Pain Med* 2004;29:23–7.
- 185 Hadzic A, Vloka JD. A comparison of the posterior versus lateral approaches to the block of the sciatic nerve in the popliteal fossa. *Anesthesiology* 1998;88:1480–6.
- 186 Nader A, Kendall MC, Candido KD, *et al.* A randomized comparison of a modified intertendinous and classic posterior approach to popliteal sciatic nerve block. *Anesth Analg* 2009;108:359–63.
- 187 March X, Pineda O, Garcia MM, *et al.* The posterior approach to the sciatic nerve in the popliteal fossa: a comparison of single- versus double-injection technique. *Anesth Analg* 2006;103:1571–3.
- 188 Dufour E, Quennesson P, Van Robais AL, *et al.* Combined ultrasound and neurostimulation guidance for popliteal sciatic nerve block: a prospective, randomized comparison with neurostimulation alone. *Anesth Analg* 2008;106:1553–8.
- 189 Perlas A, Brull R, Chan VWS, *et al.* Ultrasound guidance improves the success of sciatic nerve block at the popliteal fossa. *Reg Anesth Pain Med* 2008;33:259–65.
- 190 Danelli G, Fanelli A, Ghisi D, *et al.* Ultrasound vs nerve stimulation multiple injection technique for posterior popliteal sciatic nerve block. *Anaesthesia* 2009;64:638–42.
- 191 Sala-Blanch X, de Riva N, Carrera A, *et al.* Ultrasound-guided popliteal sciatic block with a single injection at the sciatic division results in faster block onset than the classical nerve stimulator technique. *Anesth Analg* 2012;114:1121–7.
- 192 Oberndorfer U, Marhofer P, Bösenberg A, *et al.* Ultrasonographic guidance for sciatic and femoral nerve blocks in children †. *Br J Anaesth* 2007;98:797–801.
- 193 van Geffen GJ, van den Broek E, Braak GJ, *et al.* A prospective randomised controlled trial of ultrasound guided versus nerve stimulation guided distal sciatic nerve block at the popliteal fossa. *Anaesth Intensive Care* 2009;37:32–7.
- 194 Brull R, Macfarlane AJR, Parrington SJ, *et al.* Is circumferential injection advantageous for ultrasound-guided popliteal sciatic nerve block? *Reg Anesth Pain Med* 2011;36:266–70.
- 195 Prasad A, Perlas A, Ramlogan R, *et al.* Ultrasound-guided popliteal block distal to sciatic nerve bifurcation shortens onset time. *Reg Anesth Pain Med* 2010;35:267–71.
- 196 Tran DQH, Dugani S, Pham K, *et al.* A randomized comparison between subepineural and conventional ultrasound-guided popliteal sciatic nerve block. *Reg Anesth Pain Med* 2011;36:548–52.
- 197 Perlas A, Wong P, Abdallah F, *et al.* Ultrasound-guided popliteal block through a common paraneural sheath versus conventional injection. *Reg Anesth Pain Med* 2013;38:218–25.
- 198 Choquet O, Noble GB, Abbal B, *et al.* Subparaneural versus circumferential extraneural injection at the bifurcation level in ultrasound-guided popliteal sciatic nerve blocks. *Reg Anesth Pain Med* 2014;39:306–11.
- 199 Tran DQH, González AP, Bernucci F, *et al.* A randomized comparison between bifurcation and prebifurcation subparaneural popliteal sciatic nerve blocks. *Anesth Analg* 2013;116:1170–5.
- 200 Tiyyarasertkul W, Bernucci F, González AP, *et al.* A randomized comparison between single- and triple-injection subparaneural popliteal sciatic nerve block. *Reg Anesth Pain Med* 2015;40:315–20.
- 201 Cappelleri G, Cedrati VL, Fedele LL, *et al.* Effects of the intraneural and subparaneural ultrasound-guided popliteal sciatic nerve block: a prospective, randomized, double-blind clinical and electrophysiological comparison. *Reg Anesth Pain Med* 2016;41:430–7.
- 202 Paqueron X, Bouaziz H, Macalou D, *et al.* The lateral approach to the sciatic nerve at the popliteal fossa: one or two injections? *Anesth Analg* 1999;89:1221–5.
- 203 Arcioni R, Palmisani S, Della Rocca M, *et al.* Lateral popliteal sciatic nerve block: a single injection targeting the tibial branch of the sciatic nerve is as effective as a double-injection technique. *Acta Anaesthesiol Scand* 2007;51:115–21.
- 204 Lam NC, Petersen TR, Gerstein NS, *et al.* A randomized clinical trial comparing the effectiveness of ultrasound guidance versus nerve stimulation for lateral popliteal-sciatic nerve blocks in obese patients. *J Ultrasound Med* 2014;33:1057–63.
- 205 Buys MJ, Arndt CD, Vagh F, *et al.* Ultrasound-guided sciatic nerve block in the popliteal fossa using a lateral approach: onset time comparing separate tibial and common peroneal nerve injections versus injecting proximal to the bifurcation. *Anesth Analg* 2010;110:635–7.
- 206 Germain G, Lévesque S, Dion N, *et al.* A comparison of an injection cephalad or caudad to the division of the sciatic nerve for ultrasound-guided popliteal block. *Anesthesia & Analgesia* 2012;114:233–5.
- 207 Missair A, Weisman RS, Suarez MR, *et al.* A 3-dimensional ultrasound study of local anesthetic spread during lateral popliteal nerve block. *Reg Anesth Pain Med* 2012;37:627–32.
- 208 di Benedetto P, Casati A, Bertini L, *et al.* Postoperative analgesia with continuous sciatic nerve block after foot surgery: a prospective, randomized comparison between the popliteal and subgluteal approaches. *Anesth Analg* 2002;94:996–1000.
- 209 Bendtsen TF, Nielsen TD, Rohde CV, *et al.* Ultrasound guidance improves a continuous popliteal sciatic nerve block when compared with nerve stimulation. *Reg Anesth Pain Med* 2011;36:181–4.
- 210 Maalouf D, Liu SS, Movahedi R, *et al.* Nerve stimulator versus ultrasound guidance for placement of popliteal catheters for foot and ankle surgery. *J Clin Anesth* 2012;24:44–50.
- 211 Ehlers L, Jensen JM, Bendtsen TF. Cost-effectiveness of ultrasound vs nerve stimulation guidance for continuous sciatic nerve block †. *Br J Anaesth* 2012;109:804–8.
- 212 Ilfeld BM, Sandhu NS, Loland VJ, *et al.* Ultrasound-guided (needle-in-plane) perineural catheter insertion: the effect of catheter-insertion distance on postoperative analgesia. *Reg Anesth Pain Med* 2011;36:261–5.
- 213 Casati A, Fanelli G, Koscielniak-Nielsen ZI, *et al.* Using stimulating catheters for continuous sciatic nerve block shortens onset time of surgical block and minimizes postoperative consumption of pain medication after hallux valgus repair as compared with conventional nonstimulating catheters. *Anesth Analg* 2005;101:1192–7.
- 214 Casati A, Fanelli G, Danelli G, *et al.* Stimulating or conventional perineural catheters after hallux valgus repair: a double-blind, pharmaco-economic evaluation. *Acta Anaesthesiol Scand* 2006;50:1284–9.
- 215 Rodriguez J, Taboada M, Carceller J, *et al.* Stimulating popliteal catheters for postoperative analgesia after hallux valgus repair. *Anesth Analg* 2006;102:258–62.
- 216 Paqueron X, Narchi P, Mazoit J-X, *et al.* A randomized, observer-blinded determination of the median effective volume of local anesthetic required to anesthetize the sciatic nerve in the popliteal fossa for stimulating and nonstimulating perineural catheters. *Reg Anesth Pain Med* 2009;34:290–5.
- 217 Taboada M, Rodriguez J, Valino C, *et al.* A prospective, randomized comparison between the popliteal and subgluteal approaches for continuous sciatic nerve block with stimulating catheters. *Anesth Analg* 2006;103:244–7.

- 218 Mariano ER, Cheng GS, Choy LP, *et al.* Electrical stimulation versus ultrasound guidance for popliteal-sciatic perineural catheter insertion. *Reg Anesth Pain Med* 2009;34:480–5.
- 219 Mariano ER, Loland VJ, Sandhu NS, *et al.* Comparative efficacy of ultrasound-guided and stimulating popliteal-sciatic perineural catheters for postoperative analgesia. *Can J Anesth* 2010;57:919–26.
- 220 Monahan AM, Madison SJ, Loland VJ, *et al.* Continuous popliteal sciatic blocks: does varying perineural catheter location relative to the sciatic bifurcation influence block effects? A dual-center, randomized, subject-masked, controlled clinical trial. *Anesth Analg* 2016;122:1689–95.
- 221 Kim TE, Howard SK, Funck N, *et al.* A randomized comparison of long-axis and short-axis imaging for in-plane ultrasound-guided popliteal-sciatic perineural catheter insertion. *J Anesth* 2014;28:854–60.
- 222 Hauritz RW, Pedersen EM, Linde FS, *et al.* Displacement of popliteal sciatic nerve catheters after major foot and ankle surgery: a randomized controlled double-blinded magnetic resonance imaging study. *Br J Anaesth* 2016;117:220–7.
- 223 Ambrosoli AL, Guzzetti L, Chiaranda M, *et al.* A randomised controlled trial comparing two popliteal nerve catheter tip positions for postoperative analgesia after day-case hallux valgus repair. *Anaesthesia* 2016;71:1317–23.
- 224 Rudkin GE, Rudkin AK, Dracopoulos GC. Ankle block success rate: a prospective analysis of 1,000 patients. *Can J Anesth* 2005;52:209–10.
- 225 Fredrickson MJ, White R, Danesh-Clough TK. Low-volume ultrasound-guided nerve block provides inferior postoperative analgesia compared to a higher-volume landmark technique. *Reg Anesth Pain Med* 2011;36:393–8.
- 226 Benzoni HT, Sekhadia M, Benzoni HA, *et al.* Ultrasound assisted and evoked motor response after stimulation of the deep peroneal nerve. *Anesth Analg* 2009;109:2022–4.
- 227 Antonakakis JG, Scalzo DC, Jorgenson AS, *et al.* Ultrasound does not improve the success rate of a deep peroneal nerve block at the ankle. *Reg Anesth Pain Med* 2010;35:217–21.
- 228 Redborg KE, Sites BD, Chinn CD, *et al.* Ultrasound improves the success rate of a sural nerve block at the ankle. *Reg Anesth Pain Med* 2009;34:24–8.
- 229 Redborg KE, Antonakakis JG, Beach ML, *et al.* Ultrasound improves the success rate of a tibial nerve block at the ankle. *Reg Anesth Pain Med* 2009;34:256–60.
- 230 Saporito A, Anselmi L, Borgeat A, *et al.* Can the choice of the local anesthetic have an impact on ambulatory surgery perioperative costs? Chloroprocaine for popliteal block in outpatient foot surgery. *J Clin Anesth* 2016;32:119–26.
- 231 Greengrass RA, Klein SM, D'Ercole FJ, *et al.* Lumbar plexus and sciatic nerve block for knee arthroplasty: comparison of ropivacaine and bupivacaine. *Can J Anaesth* 1998;45:1094–6.
- 232 Fanelli G, Casati A, Beccaria P, *et al.* A double-blind comparison of ropivacaine, bupivacaine, and mepivacaine during sciatic and femoral nerve blockade. *Anesth Analg* 1998;87:597–600.
- 233 Ilfeld BM, Malhotra N, Furnish TJ, *et al.* Liposomal bupivacaine as a single-injection peripheral nerve block: a dose–response study. *Anesth Analg* 2013;117:1248–56.
- 234 Cuvillon P, Nouvellon E, Ripart J, *et al.* A comparison of the pharmacodynamics and pharmacokinetics of bupivacaine, ropivacaine (with epinephrine) and their equal volume mixtures with lidocaine used for femoral and sciatic nerve blocks: a double-blind randomized study. *Anesth Analg* 2009;108:641–9.
- 235 Neal JM, Barrington MJ, Fettiplace MR, *et al.* The third American society of regional anesthesia and pain medicine practice advisory on local anesthetic systemic toxicity. *Reg Anesth Pain Med* 2018;43:113–23.
- 236 Paut O, Schreiber E, Lacroix F, *et al.* High plasma ropivacaine concentrations after fascia iliaca compartment block in children. *Br J Anaesth* 2004;92:416–8.
- 237 Keplinger M, Marhofer P, Marhofer D, *et al.* Effective local anaesthetic volumes for sciatic nerve blockade: a clinical evaluation of the ED<sub>99</sub>. *Anaesthesia* 2015;70:585–90.
- 238 Connolly C, Coventry DM, Wildsmith JAW. Double-blind comparison of ropivacaine 7.5 mg ml<sup>-1</sup> with bupivacaine 5 mg ml<sup>-1</sup> for sciatic nerve block. *Br J Anaesth* 2001;86:674–7.
- 239 Casati A, Vinciguerra F, Santorsola R, *et al.* Sciatic nerve block with 0.5% levobupivacaine, 0.75% levobupivacaine or 0.75% ropivacaine: a double-blind, randomized comparison. *Eur J Anaesthesiol* 2005;22:452–6.
- 240 Fournier R, Faust A, Chassot O, *et al.* Levobupivacaine 0.5% provides longer analgesia after sciatic nerve block using the Labat approach than the same dose of ropivacaine in foot and ankle surgery. *Anesth Analg* 2010;110:1486–9.
- 241 Casati A, Borghi B, Fanelli G, *et al.* A double-blinded, randomized comparison of either 0.5% levobupivacaine or 0.5% ropivacaine for sciatic nerve block. *Anesth Analg* 2002;94:987–90.
- 242 Taha AM, Abd-Elmaksoud AM. Ropivacaine in ultrasound-guided femoral nerve block: what is the minimal effective anaesthetic concentration (EC<sub>50</sub>)? *Anaesthesia* 2014;69:678–82.
- 243 Wulf H, Lowe J, Gnutzmann K-H, *et al.* Femoral nerve block with ropivacaine or bupivacaine in day case anterior crucial ligament reconstruction. *Acta Anaesthesiol Scand* 2010;54:414–20.
- 244 Cappelleri G, Ambrosoli AL, Turconi S, *et al.* Effect of local anesthetic dilution on the onset time and duration of double-injection sciatic nerve block: a prospective, randomized, blinded evaluation. *Anesth Analg* 2014;119:489–93.
- 245 Muñoz MT, Rodríguez J, Bermúdez M, *et al.* Low volume and high concentration of local anesthetic is more efficacious than high volume and low concentration in Labat's sciatic nerve block: a prospective, randomized comparison. *Anesth Analg* 2008;107:2085–8.
- 246 Weber A, Fournier R, Gamulin Z, *et al.* Duration of analgesia is similar when 15, 20, 25 and 30 mL of ropivacaine 0.5% are administered via a femoral catheter. *Canadian Journal of Anesthesia/Journal canadien d'anesthésie* 2005;52:390–6.
- 247 Fournier R, Weber A, Gamulin Z. No differences between 20, 30, or 40 mL ropivacaine 0.5% in continuous lateral popliteal sciatic-nerve block. *Reg Anesth Pain Med* 2006;31:455–9.
- 248 Bang SU, Kim DJ, Bae JH, *et al.* Minimum effective local anesthetic volume for surgical anesthesia by subparaneural, ultrasound-guided popliteal sciatic nerve block. *Medicine* 2016;95:e4652.
- 249 Ilfeld BM, Loland VJ, Gerancher JC, *et al.* The effects of varying local anesthetic concentration and volume on continuous popliteal sciatic nerve blocks: a dual-center, randomized, controlled study. *Anesth Analg* 2008;107:701–7.
- 250 Ilfeld BM, Moeller LK, Mariano ER, *et al.* Continuous peripheral nerve blocks. *Anesthesiology* 2010;112:347–54.
- 251 Neal JM, Gerancher JC, Hebl JR, *et al.* Upper extremity regional anesthesia: essentials of our current understanding, 2008. *Reg Anesth Pain Med* 2009;34:134–70.
- 252 Sun J, Feng X, Zhu Q, *et al.* Analgesic effect of perineural magnesium sulphate for sciatic nerve block for diabetic toe amputation: a randomized trial. *PLoS One* 2017;12:e0176589.
- 253 Brummett CM, Williams BA. Additives to local anesthetics for peripheral nerve blockade. *Int Anesthesiol Clin* 2011;49:104–16.
- 254 Candido KD, Winnie AP, Covino BG, *et al.* Addition of bicarbonate to plain bupivacaine does not significantly alter the onset or duration of plexus anesthesia. *Reg Anesth* 1995;20:133–8.
- 255 Neal JM. Effects of epinephrine in local anesthetics on the central and peripheral nervous systems: neurotoxicity and neural blood flow. *Reg Anesth Pain Med* 2003;28:124–34.
- 256 Casati A, Magistris L, Fanelli G, *et al.* Small-dose clonidine prolongs postoperative analgesia after sciatic-femoral nerve block with 0.75% ropivacaine for foot surgery. *Anesth Analg* 2000;91:388–92.
- 257 YaDeau JT, LaSala VR, Paroli L, *et al.* Clonidine and analgesic duration after popliteal fossa nerve blockade: randomized, double-blind, placebo-controlled study. *Anesth Analg* 2008;106:1916–20.
- 258 Candido KD, Hennes J, Gonzalez S, *et al.* Buprenorphine enhances and prolongs the postoperative analgesic effect of bupivacaine in patients receiving infraglutal sciatic nerve block. *Anesthesiology* 2010;113:1419–26.
- 259 YaDeau JT, Paroli L, Fields KG, *et al.* Addition of dexamethasone and buprenorphine to bupivacaine sciatic nerve block: a randomized controlled trial. *Reg Anesth Pain Med* 2015;40:321–9.
- 260 Rahangdale R, Kendall MC, McCarthy RJ, *et al.* The effects of perineural versus intravenous dexamethasone on sciatic nerve blockade outcomes: a randomized, double-blind, placebo-controlled study. *Anesth Analg* 2014;118:1113–9.
- 261 Fredrickson Fanzca MJ, Danesh-Clough TK, White R. Adjuvant dexamethasone for bupivacaine sciatic and ankle blocks: results from 2 randomized placebo-controlled trials. *Reg Anesth Pain Med* 2013;38:300–7.
- 262 Dawson RL, McLeod DH, Koerber JP, *et al.* A randomised controlled trial of perineural vs intravenous dexamethasone for foot surgery. *Anaesthesia* 2016;71:285–90.
- 263 Williams BA, Hough KA, Tsui BYK, *et al.* Neurotoxicity of adjuvants used in perineural anesthesia and analgesia in comparison with ropivacaine. *Reg Anesth Pain Med* 2011;36:225–30.
- 264 Williams BA, Schott NJ, Mangione MP, *et al.* Perineural dexamethasone and multimodal perineural analgesia: how much is too much? *Anesth Analg* 2014;118:912–4.
- 265 Pehora C, Pearson AM, Kaushal A, *et al.* Dexamethasone as an adjuvant to peripheral nerve block. *Cochrane Database Syst Rev* 2017;11:CD011770.
- 266 Rancourt M-PM, Albert NT, Côté M, *et al.* Posterior tibial nerve sensory blockade duration prolonged by adding dexmedetomidine to ropivacaine. *Anesth Analg* 2012;115:958–62.
- 267 Packiasabapathy S, Kashyap L, Arora M, *et al.* Effect of dexmedetomidine as an adjuvant to bupivacaine in femoral nerve block for perioperative analgesia in patients undergoing total knee replacement arthroplasty: a dose–response study. *Saudi J Anaesth* 2017;11:293–8.
- 268 Auroy Y, Benhamou D, Bagues L, *et al.* Major complications of regional anesthesia in France: The SOS Regional Anesthesia Hotline Service. *Anesthesiology* 2002;97:1274–80.
- 269 Barrington MJ, Watts SA, Gledhill SR, *et al.* Preliminary results of the Australasian Regional Anaesthesia Collaboration: a prospective audit of more than 7000 peripheral nerve and plexus blocks for neurologic and other complications. *Reg Anesth Pain Med* 2009;34:534–41.
- 270 Orebaugh SL, Kentor ML, Williams BA. Adverse outcomes associated with nerve-stimulator-guided and ultrasound-guided peripheral nerve blocks: update of a single database by supervised trainees. *Reg Anesth Pain Med* 2012;37:577–82.

- 271 Sites BD, Taenzer AH, Herrick MD, *et al.* Incidence of local anesthetic systemic toxicity and postoperative neurologic symptoms associated with 12,668 ultrasound-guided nerve blocks. *Reg Anesth Pain Med* 2012;37:478–82.
- 272 Neal JM, Brull R, Horn J-L, *et al.* The second American Society of Regional Anesthesia and Pain Medicine evidence-based medicine assessment of ultrasound-guided regional anesthesia: Executive summary. *Reg Anesth Pain Med* 2016;41:181–94.
- 273 Barrington MJ, Kluger R. Ultrasound guidance reduces the risk of local anesthetic systemic toxicity following peripheral nerve blockade. *Reg Anesth Pain Med* 2013;38:289–97.
- 274 Salinas FV. Evidence basis for ultrasound guidance for lower-extremity peripheral nerve block. *Reg Anesth Pain Med* 2016;41:261–74.
- 275 Liu SS, Ortolan S, Sandoval MV, *et al.* Cardiac arrest and seizures caused by local anesthetic systemic toxicity after peripheral nerve blocks. *Reg Anesth Pain Med* 2016;41:5–21.
- 276 Neal JM. Ultrasound-guided regional anesthesia and patient safety: update of an evidence-based analysis. *Reg Anesth Pain Med* 2016;41:195–204.
- 277 Abrahams MS, Aziz MF, Fu RF, *et al.* Ultrasound guidance compared with electrical neurostimulation for peripheral nerve block: a systematic review and meta-analysis of randomized controlled trials. *Br J Anaesth* 2009;102:408–17.
- 278 Gnaho A, Eyrieux S, Gentili M. Cardiac arrest during an ultrasound-guided sciatic nerve block combined with nerve stimulation. *Reg Anesth Pain Med* 2009;34:278.
- 279 Sala-Blanch X, López AM, Pomés J, *et al.* No clinical or electrophysiologic evidence of nerve injury after intraneural injection during sciatic popliteal block. *Anesthesiology* 2011;115:589–95.
- 280 Sala-Blanch X, Ribalta T, Rivas E, *et al.* Structural injury to the human sciatic nerve after intraneural needle insertion. *Reg Anesth Pain Med* 2009;34:201–5.
- 281 Farber SJ, Saheb-Al-Zamani M, Zieske L, *et al.* Peripheral nerve injury after local anesthetic injection. *Anesth Analg* 2013;117:731–9.
- 282 Auroy Y, Narchi P, Messiah A, *et al.* Serious complications related to regional anesthesia: results of a prospective survey in France. *Anesthesiology* 1997;87:479–86.
- 283 Compere V, Rey N, Baert O, *et al.* Major complications after 400 continuous popliteal sciatic nerve blocks for post-operative analgesia. *Acta Anaesthesiol Scand* 2009;53:339–45.
- 284 Brull R, McCartney CJL, Chan VWS, *et al.* Neurological complications after regional anesthesia: contemporary estimates of risk. *Anesth Analg* 2007;104:965–74.
- 285 Lee LA, Posner KL, Domino KB, *et al.* Injuries associated with regional anesthesia in the 1980s and 1990s. *Anesthesiology* 2004;101:143–52.
- 286 Capdevila X, Pirat P, Bringuier S, *et al.* Continuous peripheral nerve blocks in hospital wards after orthopedic surgery: a multicenter prospective analysis of the quality of postoperative analgesia and complications in 1,416 patients. *Anesthesiology* 2005;103:1035–45.
- 287 Hajek V, Dussart C, Klack F, *et al.* Neuropathic complications after 157 procedures of continuous popliteal nerve block for hallux valgus surgery. A retrospective study. *Orthop Traumatol Surg Res* 2012;98:327–33.
- 288 Robards C, Hadzic A, Somasundaram L, *et al.* Intraneural injection with low-current stimulation during popliteal sciatic nerve block. *Anesth Analg* 2009;109:673–7.
- 289 Orebaugh SL, Mukalel JJ, Krediet AC, *et al.* Brachial plexus root injection in a human cadaver model: injectate distribution and effects on the neuraxis. *Reg Anesth Pain Med* 2012;37:525–9.
- 290 Gadsden JC, Choi JJ, Lin E, *et al.* Opening injection pressure consistently detects needle–nerve contact during ultrasound-guided interscalene brachial plexus block. *Anesthesiology* 2014;120:1246–53.
- 291 Liu SS, Gordon MA, Shaw PM, *et al.* A prospective clinical registry of ultrasound-guided regional anesthesia for ambulatory shoulder surgery. *Anesthesia & Analgesia* 2010;111:617–23.
- 292 Neal JM, Barrington MJ, Brull R, *et al.* The Second ASRA Practice Advisory on neurologic complications associated with regional anesthesia and pain medicine. *Reg Anesth Pain Med* 2015;40:401–30.
- 293 Ivani G, Suresh S, Ecoffey C, *et al.* The European society of regional anaesthesia and pain therapy and the American society of regional anesthesia and pain medicine joint committee practice advisory on controversial topics in pediatric regional anesthesia. *Reg Anesth Pain Med* 2015;40:526–32.
- 294 Llewellyn N, Moriarty A. The National pediatric epidural audit. *Pediatric Anesthesia* 2007;17:520–33.
- 295 Giaufré E, Dalens B, Gombert A. Epidemiology and morbidity of regional anesthesia in children: a one-year prospective survey of the French-Language Society of Pediatric Anesthesiologists. *Anesth Analg* 1996;83:904–12.
- 296 Ecoffey C, Lacroix F, Giaufré E, *et al.* Association des Anesthésistes Réanimateurs Pédiatriques d'Expression Française (ADARPEF). Epidemiology and morbidity of regional anesthesia in children: a follow-up one-year prospective survey of the French-Language Society of Paediatric Anaesthesiologists (ADARPEF). *Paediatr Anaesth* 2010;20:1061–9.
- 297 Polaner DM, Taenzer AH, Walker BJ, *et al.* Pediatric Regional Anesthesia Network (PRAN): a multi-institutional study of the use and incidence of complications of pediatric regional anesthesia. *Anesth Analg* 2012;115:1353–64.
- 298 Aida S, Takahashi H, Shimoji K. Renal subcapsular hematoma after lumbar plexus block. *Anesthesiology* 1996;84:452–5.
- 299 Klein SM, D'Ercole F, Greengrass RA, *et al.* Enoxaparin associated with psoas hematoma and lumbar plexopathy after lumbar plexus block. *Anesthesiology* 1997;87:1576–9.
- 300 Aveline C, Bonnet F. Delayed retroperitoneal haematoma after failed lumbar plexus block. *Br J Anaesth* 2004;93:589–91.
- 301 Weller RS, Gerancher JC, Crews JC, *et al.* Extensive retroperitoneal hematoma without neurologic deficit in two patients who underwent lumbar plexus block and were later anticoagulated. *Anesthesiology* 2003;98:581–5.
- 302 Wheatley JK, Motamedi F, Hammonds WD. Page kidney resulting from massive subcapsular hematoma complication of lumbar sympathetic nerve block. *Urology* 1984;24:361–3.
- 303 Horlocker TT, Vandermeulen E, Kopp SL, *et al.* Regional anesthesia in the patient receiving antithrombotic or thrombolytic therapy: American society of regional anesthesia and pain medicine evidence-based guidelines (fourth edition). *Reg Anesth Pain Med* 2018;43:263–309.
- 304 Benzon HT, Avram MJ, Green D, *et al.* New oral anticoagulants and regional anaesthesia. *Br J Anaesth* 2013;111(51):96–113.
- 305 Parvaiz MA, Korwar V, McArthur D, *et al.* Large retroperitoneal haematoma: an unexpected complication of ilioinguinal nerve block for inguinal hernia repair. *Anaesthesia* 2012;67:80–1.
- 306 Aveline C, Le Hetet H, Le Roux A, *et al.* Perineural ultrasound-guided catheter bacterial colonization: a prospective evaluation in 747 cases. *Reg Anesth Pain Med* 2011;36:579–84.
- 307 Neuburger M, Büttner J, Blumenthal S, *et al.* Inflammation and infection complications of 2285 perineural catheters: a prospective study. *Acta Anaesthesiol Scand* 2007;51:108–14.
- 308 Cuvillon P, Ripart J, Lalourcey L, *et al.* The continuous femoral nerve block catheter for postoperative analgesia: bacterial colonization, infectious rate and adverse effects. *Anesth Analg* 2001;93:1045–9.
- 309 Borgeat A, Blumenthal S, Lambert M, *et al.* The feasibility and complications of the continuous popliteal nerve block: a 1001-case survey. *Anesth Analg* 2006;103:229–33.
- 310 Wiegel M, Gottschaldt U, Hennebach R, *et al.* Complications and adverse effects associated with continuous peripheral nerve blocks in orthopedic patients. *Anesth Analg* 2007;104:1578–82.
- 311 Schroeder KM, Jacobs RA, Guite C, *et al.* Use of a chlorhexidine-impregnated patch does not decrease the incidence of bacterial colonization of femoral nerve catheters: a randomized trial. *Can J Anesth* 2012;59:950–7.
- 312 Compère V, Cornet C, Fourdrinier V, *et al.* Thigh abscess as a complication of continuous popliteal sciatic nerve block. *Br J Anaesth* 2005;95:255–6.
- 313 Walker BJ, Long JB, De Oliveira GS, *et al.* Peripheral nerve catheters in children: an analysis of safety and practice patterns from the pediatric regional anesthesia network (PRAN). *Br J Anaesth* 2015;115:457–62.
- 314 Adam F, Jaziri S, Chauvin M. Psoas abscess complicating femoral nerve block catheter. *Anesthesiology* 2003;99:230–1.
- 315 Bernstein IT, Hansen BJ. Iatrogenic psoas abscess. Case report. *Scand J Urol Nephrol* 1991;25:85–6.
- 316 Hebl JR. The importance and implications of aseptic techniques during regional anesthesia. *Reg Anesth Pain Med* 2006;31:311–23.
- 317 American Society of Anesthesiologists Task Force on Infectious Complications Associated with Neuraxial Techniques. Practice advisory for the prevention, diagnosis, and management of infectious complications associated with neuraxial techniques. *Anesthesiology* 2010;112:530–45.
- 318 Chuan A, Tiong C, Maley M, *et al.* Decontamination of ultrasound equipment used for peripheral ultrasound-guided regional anaesthesia. *Anaesth Intensive Care* 2013;41:529–34.
- 319 Kinirons B, Mimoz O, Lafendi L, *et al.* Chlorhexidine versus povidone iodine in preventing colonization of continuous epidural catheters in children. *Anesthesiology* 2001;94:239–44.
- 320 Chaiyakunapruk N, Veenstra DL, Lipsky BA, *et al.* Chlorhexidine compared with povidone-iodine solution for vascular catheter–site care. *Ann Intern Med* 2002;136:792–801.
- 321 Zink W, Graf BM. Local anesthetic myotoxicity. *Reg Anesth Pain Med* 2004;29:333–40.
- 322 Hogan Q, Dotson R, Erickson S, *et al.* Local anesthetic myotoxicity: a case and review. *Anesthesiology* 1994;80:942–6.
- 323 Neal JM, Salinas FV, Choi DS. Local anesthetic-induced myotoxicity after continuous adductor canal block. *Reg Anesth Pain Med* 2016;41:723–7.
- 324 Gómez-Arnau JI, Yangüela J, González A, *et al.* Anaesthesia-related diplopia after cataract surgery. *Br J Anaesth* 2003;90:189–93.
- 325 Rainin EA, Carlson BM. Postoperative diplopia and ptosis. A clinical hypothesis based on the myotoxicity of local anesthetics. *Arch Ophthalmol* 1985;103:1337–9.
- 326 Esswein MB, von Noorden GK. Paresis of a vertical rectus muscle after cataract extraction. *Am J Ophthalmol* 1993;116:424–30.
- 327 Koide R, Honda M, Kora Y, *et al.* Diplopia after cataract surgery. *J Cataract Refract Surg* 2000;26:1198–204.
- 328 Golnik KC, West CE, Kaye E, *et al.* Incidence of ocular misalignment and diplopia after uneventful cataract surgery. *J Cataract Refract Surg* 2000;26:1205–9.

- 329 Ong-Tone L, Pearce WG. Inferior rectus muscle restriction after retrobulbar anesthesia for cataract extraction. *Can J Ophthalmol* 1989;24:162–5.
- 330 Salama H, Farr AK, Guyton DL. Anesthetic myotoxicity as a cause of restrictive strabismus after scleral buckling surgery. *Retina* 2000;20:478–82.
- 331 Parris WCV, Dettbarn WD. Muscle atrophy following nerve block therapy. *Anesthesiology* 1988;69:289.
- 332 Ilfeld BM, Duke KB, Donohue MC. The association between lower extremity continuous peripheral nerve blocks and patient falls after knee and hip arthroplasty. *Anesth Analg* 2010;111:1552–4.
- 333 Johnson RL, Kopp SL, Hebl JR, et al. Falls and major orthopaedic surgery with peripheral nerve blockade: a systematic review and meta-analysis. *Br J Anaesth* 2013;110:518–28.
- 334 Crumley Aybar BL, Gillespie MJ, Gipson SF, et al. Peripheral nerve blocks causing increased risk for fall and difficulty in ambulation for the hip and knee joint replacement patient. *J Perianesth Nurs* 2016;31:504–19.
- 335 Memtsoudis SG, Danninger T, Rasul R, et al. Inpatient falls after total knee arthroplasty: the role of anesthesia type and peripheral nerve blocks. *Anesthesiology* 2014;120:551–63.
- 336 Turbitt LR, McHardy PG, Casanova M, et al. Analysis of inpatient falls after total knee arthroplasty in patients with continuous femoral nerve block. *Anesth Analg* 2018;127:224–7.
- 337 Muraskin SI, Conrad B, Zheng N, et al. Falls associated with lower-extremity-nerve blocks: a pilot investigation of mechanisms. *Reg Anesth Pain Med* 2007;32:67–72.
- 338 Pelt CE, Anderson AW, Anderson MB, et al. Postoperative falls after total knee arthroplasty in patients with a femoral nerve catheter: can we reduce the incidence? *J Arthroplasty* 2014;29:1154–7.
- 339 Huet O, Eyrolle LJ, Mazoit JX, et al. Cardiac arrest after injection of ropivacaine for posterior lumbar plexus blockade. *Anesthesiology* 2003;99:1451–3.
- 340 Pousman RM, Mansoor Z, Sciard D. Total spinal anesthetic after continuous posterior lumbar plexus block. *Anesthesiology* 2003;98:1281–2.
- 341 Veal C, Auyong DB, Hanson NA, et al. Delayed quadriceps weakness after continuous adductor canal block for total knee arthroplasty: a case report. *Acta Anaesthesiol Scand* 2014;58:362–4.
- 342 Chen J, Lesser JB, Hadzic A, et al. Adductor canal block can result in motor block of the quadriceps muscle. *Reg Anesth Pain Med* 2014;39:170–1.
- 343 Morris G, Lang S, Dust W, et al. The parasacral sciatic nerve block. *Reg Anesth Pain Med* 1997;22:223–8.
- 344 Helayer PE, Ceccon MS, Knaesel JA, et al. Urinary incontinence after bilateral parasacral sciatic-nerve block. *Reg Anesth Pain Med* 2006;31:368–71.
- 345 Ripart J, Cuvillon P, Nouvellon E, et al. Parasacral approach to block the sciatic nerve: a 400-case survey. *Reg Anesth Pain Med* 2005;30:193–7.
- 346 Zhang P, Liang Y, He J, et al. Timing of tourniquet release in total knee arthroplasty. *Medicine* 2017;96:e6786.
- 347 Berman AT, Parmet JL, Harding SP, et al. Emboli observed with use of transeophageal echocardiography immediately after tourniquet release during total knee arthroplasty with cement\*. *J Bone Joint Surg Am* 1998;80:389–96.
- 348 Parmet JL, Horrow JC, Berman AT, et al. The incidence of large venous emboli during total knee arthroplasty without pneumatic tourniquet use. *Anesth Analg* 1998;87:439–44.
- 349 Olivecrona C, Lapidus LJ, Benson L, et al. Tourniquet time affects postoperative complications after knee arthroplasty. *Int Orthop* 2013;37:827–32.
- 350 Rorabeck CH, Kennedy JC. Tourniquet-induced nerve ischemia complicating knee ligament surgery. *Am J Sports Med* 1980;8:98–102.
- 351 Kam PC, Kavanagh R, Yoong FF, et al. The arterial tourniquet: pathophysiological consequences and anaesthetic implications. *Anaesthesia* 2001;56:534–45.
- 352 Kumar K, Railton C, Tawfic Q. Tourniquet application during anesthesia: "What we need to know?". *J Anaesthesiol Clin Pharmacol* 2016;32:424–30.
- 353 Horlocker TT, Hebl JR, Gali B, et al. Anesthetic, patient, and surgical risk factors for neurologic complications after prolonged total tourniquet time during total knee arthroplasty. *Anesth Analg* 2006;102:950–5.
- 354 Walker BJ, Noonan KJ, Bosenberg AT. Evolving compartment syndrome not masked by a continuous peripheral nerve block: evidence-based case management. *Reg Anesth Pain Med* 2012;37:393–7.
- 355 Han F, Daruwalla ZI, Shen L, et al. A prospective study of surgical outcomes and quality of life in severe foot trauma and associated compartment syndrome after fasciotomy. *J Foot Ankle Surg* 2015;54:417–23.
- 356 Cometa MA, Esch AT, Boezaart AP. Did continuous femoral and sciatic nerve block obscure the diagnosis or delay the treatment of acute lower leg compartment syndrome? A case report. *Pain Med* 2011;12:823–8.
- 357 Mannion S, Capdevila X. Acute compartment syndrome and the role of regional anesthesia. *Int Anesthesiol Clin* 2010;48:85–105.
- 358 Schmidt AH. Acute compartment syndrome. *Injury* 2017;48(S1):S22–S25.
- 359 Mar GJ, Barrington MJ, McGuirk BR. Acute compartment syndrome of the lower limb and the effect of postoperative analgesia on diagnosis. *Br J Anaesth* 2009;102:3–11.
- 360 Hyder N, Kessler S, Jennings AG, et al. Compartment syndrome in tibial shaft fracture missed because of a local nerve block. *J Bone Joint Surg Br* 1996;78-B:499–500.
- 361 Noorpuri B, Shahane S, Getty C. Acute compartment syndrome following revisional arthroplasty of the forefoot: the dangers of ankle-block. *Foot Ankle Int*;200:680–2.
- 362 Nair GS, Soliman LM, Maheshwari K, et al. Importance of vigilant monitoring after continuous nerve block: lessons from a case report. *Ochsner J* 2013;13:267–9.
- 363 Kucera TJ, Boezaart AP. Regional anesthesia does not consistently block ischemic pain: two further cases and a review of the literature. *Pain Medicine* 2014;15:316–9.
- 364 Uzel A-P, Steinmann G. Thigh compartment syndrome after intramedullary femoral nailing: possible femoral nerve block influence on diagnosis timing. *Orthop Traumatol Surg Res* 2009;95:309–13.
- 365 Dwyer T, Drexler M, Chan VW, et al. Neurological complications related to elective orthopedic surgery: part 2: common hip and knee procedures. *Reg Anesth Pain Med* 2015;40:443–54.
- 366 Veljkovic A, Dwyer T, Lau JT, et al. Neurological complications related to elective orthopedic surgery: part 3: common foot and ankle procedures. *Reg Anesth Pain Med* 2015;40:455–66.
- 367 Tran D, Clemente A, Finlayson RJ. A review of approaches and techniques for lower extremity nerve blocks. *Can J Anaesth* 2007;54:922–34.
- 368 Singelyn FJ, Deyaert M, Joris D, et al. Effects of intravenous patient-controlled analgesia with morphine, continuous epidural analgesia, and continuous three-in-one block on postoperative pain and knee rehabilitation after unilateral total knee arthroplasty. *Anesth Analg* 1998;87:88–92.
- 369 Capdevila X, Barthelet Y, Biboulet P, et al. effects of perioperative analgesic technique on the surgical outcome and duration of rehabilitation after major knee surgery. *Anesthesiology* 1999;91:8–15.
- 370 Jaeger P, Zanic D, Fomsgaard JS, et al. Adductor canal block versus femoral nerve block for analgesia after total knee arthroplasty: a randomized, double-blind study. *Reg Anesth Pain Med* 2013;38:526–32.
- 371 Barrington MJ, Olive D, Low K, et al. Continuous femoral nerve blockade or epidural analgesia after total knee replacement: a prospective randomized controlled trial. *Anesth Analg* 2005;101:1824–9.
- 372 Kwofie MK, Shastri UD, Gadsden JC, et al. The effects of ultrasound-guided adductor canal block versus femoral nerve block on quadriceps strength and fall risk. *Reg Anesth Pain Med* 2013;38:321–5.
- 373 Shah NA, Jain NP. Is continuous adductor canal block better than continuous femoral nerve block after total knee arthroplasty? Effect on ambulation ability, early functional recovery and pain control: a randomized controlled trial. *J Arthroplasty* 2014;29:2224–9.
- 374 Macrinici GI, Murphy C, Christman L, et al. Prospective, double-blind, randomized study to evaluate single-injection adductor canal nerve block versus femoral nerve block: postoperative functional outcomes after total knee arthroplasty. *Reg Anesth Pain Med* 2017;42:10–16.
- 375 Sorensen JK, Jaeger P, Dahl JB, et al. The isolated effect of adductor canal block on quadriceps femoris muscle strength after total knee arthroplasty: a triple-blinded, randomized, placebo-controlled trial with individual patient analysis. *Anesth Analg* 2016;122:553–8.
- 376 Elkassabany NM, Antosh S, Ahmed M, et al. The risk of falls after total knee arthroplasty with the use of a femoral nerve block versus an adductor canal block: a double-blinded randomized controlled study. *Anesth Analg* 2016;122:1696–703.
- 377 Wiesmann T, Piechowiak K, Duderstadt S, et al. Continuous adductor canal block versus continuous femoral nerve block after total knee arthroplasty for mobilisation capability and pain treatment: a randomised and blinded clinical trial. *Arch Orthop Trauma Surg* 2016;136:397–406.
- 378 Ozer H, Tekdemir I, Elhan A, et al. A clinical case and anatomical study of the innervation supply of the vastus medialis muscle. *Knee Surg Sports Traumatol Arthroscop* 2004;12:119–22.
- 379 McNamee DA, Parks L, Milligan KR. Post-operative analgesia following total knee replacement: an evaluation of the addition of an obturator nerve block to combined femoral and sciatic nerve block. *Acta Anaesthesiol Scand* 2002;46:95–9.
- 380 Runge C, Børglum J, Jensen JM, et al. The analgesic effect of obturator nerve block added to a femoral triangle block after total knee arthroplasty. *Reg Anesth Pain Med* 2016;41:445–51.
- 381 Terkawi AS, Mavridis D, Sessler DI, et al. Pain management modalities after total knee arthroplasty: a network meta-analysis of 170 randomized controlled trials. *Anesthesiology* 2017;126:923–37.
- 382 Grape S, Kirkham KR, Baeriswyl M, et al. The analgesic efficacy of sciatic nerve block in addition to femoral nerve block in patients undergoing total knee arthroplasty: a systematic review and meta-analysis. *Anaesthesia* 2016;71:1198–209.
- 383 Abdallah FW, Madjdpour C, Brull R. Is sciatic nerve block advantageous when combined with femoral nerve block for postoperative analgesia following total knee arthroplasty? a meta-analysis. *Can J Anaesth* 2016;63:552–68.
- 384 Sinha SK, Abrams JH, Arumugam S, et al. Femoral nerve block with selective tibial nerve block provides effective analgesia without foot drop after total knee arthroplasty: a prospective, randomized, observer-blinded study. *Anesth Analg* 2012;115:202–6.
- 385 Kardash KJ, Noel GP. The SPANK block: a selective sensory, single-injection solution for posterior pain after total knee arthroplasty. *Reg Anesth Pain Med* 2016;41:118–9.
- 386 Gi E, Yamauchi M, Yamakage M, et al. Effects of local infiltration analgesia for posterior knee pain after total knee arthroplasty: comparison with sciatic nerve block. *J Anesth* 2014;28:696–701.

- 387 Safa B, Gollish J, Haslam L, *et al.* Comparing the effects of single shot sciatic nerve block versus posterior capsule local anesthetic infiltration on analgesia and functional outcome after total knee arthroplasty. *J Arthroplasty* 2014;29:1149–53.
- 388 Pinsorsak P, Nangnual S, Boontanapibul K. Multimodal infiltration of local anaesthetic in total knee arthroplasty; is posterior capsular infiltration worth the risk? A prospective, double-blind, randomised controlled trial. *Bone Joint J* 2017;99-B:483–8.
- 389 Kirkham KR, Grape S, Martin R, *et al.* Analgesic efficacy of local infiltration analgesia vs. femoral nerve block after anterior cruciate ligament reconstruction: a systematic review and meta-analysis. *Anaesthesia* 2017;72:1542–53.
- 390 Stebler K, Martin R, Kirkham KR, *et al.* Electrophysiological study of femoral nerve function after a continuous femoral nerve block for anterior cruciate ligament reconstruction: a randomized, controlled single-blind trial. *Am J Sports Med* 2017;45:578–83.
- 391 Swank KR, DiBartola AC, Everhart JS, *et al.* The effect of femoral nerve block on quadriceps strength in anterior cruciate ligament reconstruction: a systematic review. *Arthroscopy* 2017;33:1082–91.
- 392 El Ahl M. Femoral nerve block versus adductor canal block for postoperative pain control after anterior cruciate ligament reconstruction: a randomized controlled double blind study. *Saudi J Anaesth* 2015;9:279–82.
- 393 Abdallah FW, Whelan DB, Chan VW, *et al.* Adductor canal block provides noninferior analgesia and superior quadriceps strength compared with femoral nerve block in anterior cruciate ligament reconstruction. *Anesthesiology* 2016;124:1053–64.
- 394 Siddiqui ZI, Cepeda SM, Denman W, *et al.* Continuous lumbar plexus block provides improved analgesia with fewer side effects compared with systemic opioids after hip arthroplasty. *Reg Anesth Pain Med* 2007;32:393–8.
- 395 Becchi C, Al Malyan M, Coppini R, *et al.* Opioid-free analgesia by continuous psoas compartment block after total hip arthroplasty: a randomized study. *Eur J Anaesthesiol* 2008;25:418–23.
- 396 Fournier R, Van Gessel E, Gaggero G, *et al.* Postoperative analgesia with “3-in-1” femoral nerve block after prosthetic hip surgery. *Can J Anaesth* 1998;45:34–8.
- 397 Wiesmann T, Steinfeldt T, Wagner G, *et al.* Supplemental single shot femoral nerve block for total hip arthroplasty: impact on early postoperative care, pain management and lung function. *Minerva Anestesiol* 2014;80:48–57.
- 398 Stevens M, Harrison G, McGrail M. A modified fascia iliaca compartment block has significant morphine-sparing effect after total hip arthroplasty. *Anaesth Intensive Care* 2007;35:949–52.
- 399 Desmet M, Vermeylen K, Van Herreweghe I, *et al.* A longitudinal supra-inguinal fascia iliaca compartment block reduces morphine consumption after total hip arthroplasty. *Reg Anesth Pain Med* 2017;42:327–33.
- 400 Marino J, Russo J, Kenny M, *et al.* Continuous lumbar plexus block for postoperative pain control after total hip arthroplasty. *J Bone Joint Surg Am* 2009;91:29–37.
- 401 Ilfeld BM, Mariano ER, Madison SJ, *et al.* Continuous femoral versus posterior lumbar plexus nerve blocks for analgesia after hip arthroplasty. *Anesth Analg* 2011;113:897–903.
- 402 Wang X, Sun Y, Wang L, *et al.* Femoral nerve block versus fascia iliaca block for pain control in total knee and hip arthroplasty: a meta-analysis from randomized controlled trials. *Medicine* 2017;96:e7382.
- 403 Kumar K, Pandey RK, Bhalla AP, *et al.* Comparison of conventional infrainguinal versus modified proximal suprainguinal approach of fascia iliaca compartment block for postoperative analgesia in total hip arthroplasty. A prospective randomized study. *Acta Anaesthesiol Belg* 2015;66:95–100.
- 404 Ilfeld BM, Ball ST, Gearen PF, *et al.* Ambulatory continuous posterior lumbar plexus nerve blocks after hip arthroplasty: a dual-center, randomized, triple-masked, placebo-controlled trial. *Anesthesiology* 2008;109:491–501.
- 405 Ilfeld BM, Ball ST, Gearen PF, *et al.* Health-related quality of life after hip arthroplasty with and without an extended-duration continuous posterior lumbar plexus nerve block: a prospective, 1-year follow-up of a randomized, triple-masked, placebo-controlled study. *Anesth Analg* 2009;109:586–91.
- 406 Kearns R, Macfarlane A, Grant A, *et al.* A randomised, controlled, double blind, non-inferiority trial of ultrasound-guided fascia iliaca block vs. spinal morphine for analgesia after primary hip arthroplasty. *Anaesthesia* 2016;71:1431–40.
- 407 Souron V, Delaunay L, Schiffrine P. Intrathecal morphine provides better postoperative analgesia than psoas compartment block after primary hip arthroplasty. *Can J Anaesth* 2003;50:574–9.
- 408 Jiménez-Almonte JH, Wyles CC, Wyles SP, *et al.* Is local infiltration analgesia superior to peripheral nerve blockade for pain management after THA: a network meta-analysis. *Clin Orthop Relat Res* 2016;474:495–516.
- 409 Kuchálik J, Magnuson A, Lundin A, *et al.* Local infiltration analgesia or femoral nerve block for postoperative pain management in patients undergoing total hip arthroplasty. A randomized, double-blind study. *Scand J Pain* 2017;16:223–30.
- 410 Guay J, Parker MJ, Griffiths R, *et al.* Peripheral nerve blocks for hip fractures. *Cochrane Database Syst Rev* 2017;5:CD001159.
- 411 Coad NR. Post-operative analgesia following femoral-neck surgery—a comparison between 3 in 1 femoral nerve block and lateral cutaneous nerve block. *Eur J Anaesthesiol* 1991;8:287–90.
- 412 Reavley P, Montgomery AA, Smith JE, *et al.* Randomised trial of the fascia iliaca block versus the ‘3-in-1’ block for femoral neck fractures in the emergency department. *Emerg Med J* 2015;32:685–9.
- 413 Newman B, McCarthy L, Thomas PW, *et al.* A comparison of pre-operative nerve stimulator-guided femoral nerve block and fascia iliaca compartment block in patients with a femoral neck fracture. *Anaesthesia* 2013;68:899–903.
- 414 Foss NB, Kristensen MT, Palm H, *et al.* Postoperative pain after hip fracture is procedure specific. *Br J Anaesth* 2009;102:1111–6.
- 415 McRae PJ, Bendall JC, Madigan V, *et al.* Paramedic-performed fascia iliaca compartment block for femoral fractures: A controlled trial. *J Emerg Med* 2015;48:581–9.